

# Right ventricle outflow tract stenting as a method of palliative treatment of severe tetralogy of Fallot

Paweł Dryżek, Anna Mazurek-Kula, Tomasz Moszura and Andrzej Sysa

Department of Cardiology, Polish Mother's Memorial Hospital, Research Institute, Łódź, Poland

## Abstract

*We present the case of a 3-month-old infant with tetralogy of Fallot (ToF) with pulmonary artery hypoplasia, critical right ventricle outflow tract (RVOT) obstruction and the presence of major aortopulmonary collateral arteries (MAPCA) and CATCH 22 syndrome. Due to anatomical conditions (severe pulmonary artery hypoplasia), the patient was not qualified for palliative operative treatment Blalock-Taussig shunt. We conducted catheterization with an attempt of balloon plasty and stent implantation into the right ventricle outflow tract and main pulmonary artery. Successful stent implantation into the right ventricle outflow tract was performed. The stent created a 4.1 mm diameter channel and allowed for unrestricted blood flow from the right ventricle to the pulmonary arteries. After the procedure we observed an increase in blood saturation of up to 89%.*

*Control echocardiography revealed blood flow through the stent to the pulmonary arteries with a pressure gradient of 45 mm Hg. There were neither rhythm nor conduction disturbances in the control ECG after the procedure.*

*After 6 days of observation the patient was discharged from our department.*

*We conclude that successful stent implantation into the RVOT in patients with ToF and hypoplastic pulmonary arteries improves their clinical condition, increases pulmonary blood flow by physiological means and leads to an improvement of pulmonary artery development before surgical treatment. (Cardiol J 2008; 15: 376–379)*

**Key words:** tetralogy of Fallot, stent, treatment

## Introduction

Tetralogy of Fallot (ToF) is quite a common congenital heart defect that represents about 6% of all congenital malformations of the cardiovascular system. In this condition the presence and degree of cyanosis depends on right ventricular outflow tract obstruction and the degree of pulmonary artery development. Tetralogy of Fallot has many anatomical variants with different clinical and

hemodynamic findings. The form with correct pulmonary arteries occurs rarely. Usually a different degree of pulmonary artery hypoplasia is diagnosed.

A special type of ToF is the form with pulmonary artery hypoplasia, critical right ventricle outflow tract (RVOT) obstruction and the presence of major aortopulmonary collateral arteries (MAPCA). Blalock-Taussig anastomosis is often the first step of operative treatment in this type of ToF. It allows for hypoxia avoidance, satisfactory oxygen

---

**Address for correspondence:** Paweł Dryżek, MD, PhD, Department of Cardiology, Polish Mother's Memorial Hospital, Research Institute, Rzgowska 281/289, 93–338 Łódź, Poland, tel: +48 42 271 21 84, fax: +48 42 271 14 78, e-mail: pawdry@tlen.pl

Received: 7.02.2008

Accepted: 6.04.2008

delivery and pulmonary artery development until the next step of surgical treatment.

In some patients with severe pulmonary artery underdevelopment there is no possibility for systemic-pulmonary anastomosis during the early life period, and increasing hypoxemia is life-threatening for these children.

Right ventricle outflow tract balloon plasty with subsequent stent implantation can be an alternative method of treatment in this group of patients.

We present a case of successful interventional treatment of a 3-month-old infant with ToF.

### Case report

A 2-month-old female infant was admitted to the Cardiology Department of the Polish Mother's Memorial Hospital — Research Institute with a diagnosis of ToF with severe pulmonary artery hypoplasia and MAPCAs for preoperative assessment and qualification for operative treatment. Due to severe hypoxemia the child required permanent passive oxygen therapy (arterialized capillary blood oxygen concentration 70%). The infant was born as a child from a third pregnancy, full time (41 weeks of gestation) vaginal delivery with a birth weight of 3680 g and Apgar score of 8 at 5 min.

Cardiac catheterization was performed on the fifteenth day of life in the Cardiology Department of the Institute of Pediatrics of the Medical University of Gdansk, where the patient was previously hospitalized. The catheterization revealed a severe degree of main, right and left pulmonary artery underdevelopment and 3 big MAPCAs originating from the descending aorta.

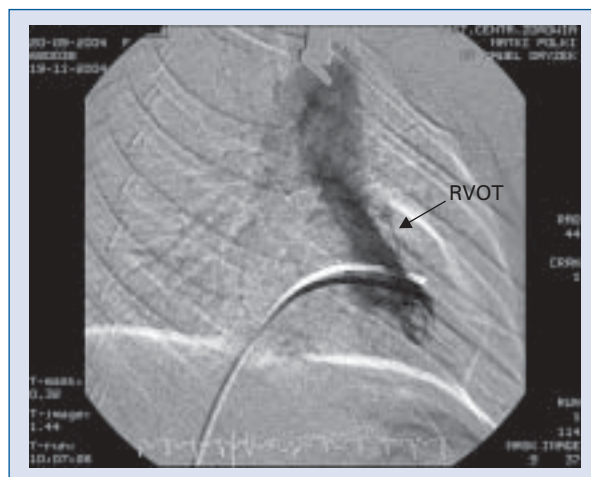
Because of dysmorphism and the type of cardiac malformation, we suspected CATCH 22 (di George) syndrome, which was confirmed by FISH test.

Due to anatomical conditions (severe pulmonary hypoplasia) the patient was not qualified for palliative operative treatment Blalock-Taussig shunt.

The patient was qualified for recatheterization with an attempt of balloon plasty and stent implantation into the right ventricle outflow tract and main pulmonary artery. The body weight at the day of catheterization was 4500 g.

### Method of treatment

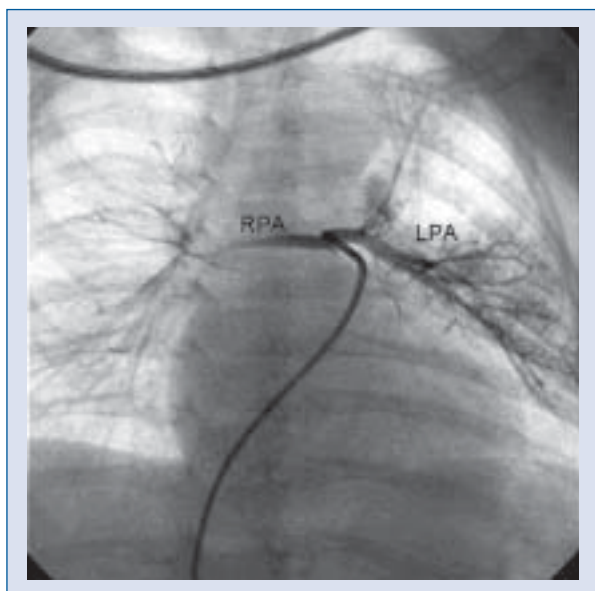
After intubation and mechanical ventilation with 100% oxygen in general anesthesia, a 4 F MPA catheter (Cordis, Johnson-Johnson) was inserted into the right ventricle through the right femoral



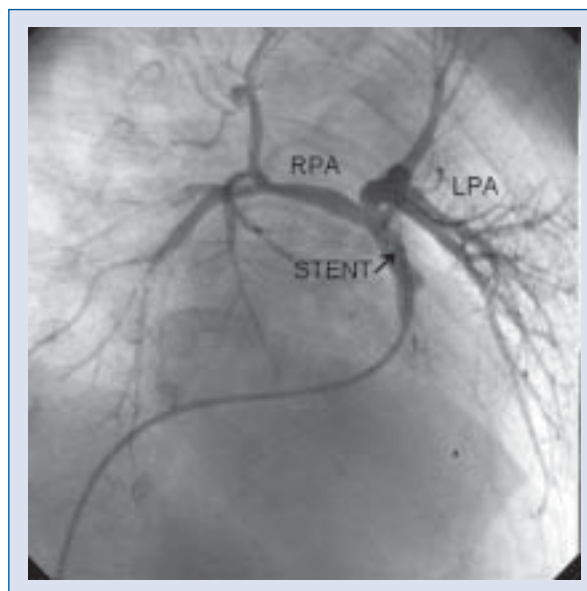
**Figure 1.** Right ventriculography in a patient with tetralogy of Fallot before stent implantation.

vein. We then performed angiography which confirmed severe right ventricle outflow tract obstruction with main, right and left pulmonary artery severe underdevelopment. Mean diameter of the main pulmonary artery was 2.8 mm; right pulmonary artery — 1.8 mm; and left pulmonary artery — 1.5 mm. Despite repeated trials, we failed with introduction of a 0.014" coronary guide wire into the right or left pulmonary artery. A catheter was introduced into the right ventricle outflow tract and into the main pulmonary artery. Using a floppy guide wire (Cordis, Johnson-Johnson) with a 3 cm tip fixed in the right pulmonary artery we introduced an angiographic catheter. After stable localisation of the coronary guide wire in the terminal branches of the right pulmonary artery we introduced a Sprinter coronary balloon catheter 3.5 × 20 mm (Medtronic) and performed balloon angioplasty of the right ventricle outflow tract and main and right pulmonary arteries. We then introduced a coronary stent, fixed on the balloon Coroflex 3.5 × 16 mm (Braun), into the main pulmonary artery and after correct fixation in the space between the RVOT and pulmonary artery bifurcation we expanded the balloon with a pressure of 20 atm. for stent implantation to the RVOT.

We performed control angiography from the right ventricle and pressure measurements. Antibiotic (cephalosporin) was administered prophylactically, and a single dose of heparin (100 U/kg body weight) was administered during the procedure. In the days following the procedure the patient was administered low-molecular-weight heparin (enoxaparin sodium) and we started acetylsalicylate acid treatment (3 mg/kg body weight) with a recommendation of treatment continuation for 6 months (Fig. 1, 2).



**Figure 2.** Angiography from the main pulmonary artery showed hypoplastic right (RPA) and left (LPA) pulmonary arteries.



**Figure 3.** Angiography after deployment of a stent in the infundibulum, with improvement of blood flow to the hypoplastic pulmonary arteries; RPA — right pulmonary artery; LPA — left pulmonary artery.

## Results

Successful stent implantation into the RVOT was performed. In control angiography we confirmed correct stent localization from RVOT to pulmonary artery bifurcation. The stent created a 4.1 mm diameter channel and allowed for unrestricted blood flow. After the procedure we observed increase of blood saturation up to 89%.

Control echocardiography revealed blood flow through the stent to the pulmonary arteries with a pressure gradient of 45 mm Hg. There were neither rhythm nor conductivity disturbances in the control ECG after the procedure.

After 6 days of observation the patient was discharged from our department (Fig. 3).

## Discussion

Right ventricle outflow tract and main pulmonary artery stent implantation can be an alternative to palliative surgical treatment in patients with ToF and hypoplastic pulmonary arteries, especially when anatomical conditions restrict surgical treatment. Stent implantation into the RVOT was used as a method of treatment in patients after surgical repair with restenosis of native RVOT or implanted homograft [1–3]. This procedure can also be used in patients with ToF with severe pulmonary artery underdevelopment despite Blalock-Taussig anastomosis. In these patients RVOT stent implan-

tation leads to an increase in pulmonary inflow by anatomical means, blood saturation and improvement of clinical condition [4].

In analyzed publications we did not find any data concerning coronary stent implantation into the RVOT in young infants with ToF. The use of a coronary stent was the consequence of the native pulmonary artery diameter [5]. Such a small stent diameter may cause internal hypertrophy and stent occlusion, which occurs in 3–36% of cases [6–8]. Ventricular rhythm disturbances, stent damage, fracture or dislocation are possible complications of stent implantation into the RVOT [3].

## Outcome

The patient still remains under our observation. At the age of 8 months (6 months after intervention) the child was readmitted to our department due to cyanosis increase and blood desaturation to 75%. Catheterization revealed a left pulmonary artery (LPA) diameter of 4 mm and right pulmonary artery (RPA) diameter of 3.6 mm. We also conducted balloon angioplasty on the previously implanted stent. After intervention, a saturation increase to 85% was observed. The next catheterization, performed at the age of 15 months, confirmed continuation of pulmonary artery development (LPA 4.2 mm; RPA 3.9 mm); we also

visualized 3 wide MAPCAs originating from the descending aorta. The patient was qualified for surgical treatment. The right Blalock-Taussig anastomosis (3.5 mm diameter) was performed in the child's fifteenth month of age.

During the last hospitalization in November 2007 at the age of 3 years and 2 months, we observed desaturation to 76–78% and cyanosis increase. Catheterization visualized critical stenosis of the right ventricle outflow in the proximal part of the implanted stent and below the stent. Balloon angioplasty with stent Palmaz-Genesis (6 × 18 mm) implantation were performed. We observed a saturation increase to 86% after the intervention.

We have observed systematic development of the pulmonary arteries from infancy. The diameters of both pulmonary arteries are currently about 6 mm.

### Conclusions

Successful stent implantation into the RVOT in patients with ToF and hypoplastic pulmonary arteries improves clinical condition, increases pulmonary blood flow by physiological means and leads to an improvement in pulmonary artery development before surgical treatment.

### Acknowledgements

The authors do not report any conflict of interest regarding this work.

### References

1. Hausdorf G, Schulze-Neick I, Lange PE. Radiofrequency-assisted "reconstruction" of the right ventricular outflow tract muscular atresia with ventricular septal defect. *Br Heart J*, 1993; 69: 43–46.
2. O'Laughlin MP, Slack MC, Grifka RG, Perry SB, Lock JE, Mullins CE. Implantation and intermediate term follow-up of stent in congenital heart disease. *Circulation*, 1993; 88: 605–614.
3. Nakanishi T, Kondoh C, Nishikawa T et al. Intravascular stent for management of pulmonary artery and right ventricular outflow obstruction. *Heart Vessels*, 1994; 4: 40–48.
4. Gibbs JL, Uzun O, Blackburn MEC, Parsons JM, Dickinson DF. Right ventricular outflow stent implantation: an alternative to palliative surgical relief of infundibular pulmonary stenosis. *Heart*, 1997; 77: 176–179.
5. Pass RH, Hsu DT, Garabedian CP, Schiller MS, Jayakumar KA, Hellenbrand WE. Endovascular stent implantation in the pulmonary arteries of infants and children without the use of a long vascular sheath. *Catheter Cardiovasc Interv*, 2002; 55: 505–509.
6. Ing FF, Grifka RG, Nihill MR, Mullins CE. Repeat dilation of intravascular stent in congenital heart defects. *Circulation*, 1995; 92: 893–897.
7. Fogelman R, Nykanen D, Smallhorn JF, McCrindle BW, Freedom RM, Benson LN. Endovascular stent in the pulmonary circulation: Clinical impact on management and medium-term follow-up. *Circulation*, 1995; 92: 881–885.
8. McMahon CJ, El-Said HG, Grifka RG, Fraley JK, Nihill MR, Mullins CE. Redilation of endovascular stents in congenital heart disease: factors implicated in the development of restenosis and neointimal proliferation. *J Am Coll Cardiol*, 2001; 38: 521–526.