

# Mid-term results of a modified arterial switch operation using the direct reconstruction technique of the pulmonary artery

Włodzimierz Kuroczyński<sup>1</sup>, Christoph Kampmann<sup>2</sup>, Ali Asghar Peivandi<sup>1</sup>,  
Marc Hartert<sup>1</sup>, Markus Knuf<sup>2</sup>, Markus K. Heinemann<sup>1</sup>, Christian-Friedrich Vahl<sup>1</sup>

<sup>1</sup>Department of Cardiothoracic and Vascular Surgery, University Hospital Mainz, Germany

<sup>2</sup>Department of Pediatric Cardiology, University Hospital Mainz, Germany

## Abstract

**Background:** *There is ongoing discussion as to whether it is beneficial to avoid pulmonary sinus augmentation in the arterial switch operation. We report a single-surgeon series of mid-term results for direct pulmonary artery anastomosis during switch operation for transposition of the great arteries (TGA).*

**Methods:** *This retrospective study includes 17 patients with TGA, combined with an atrial septal defect, patent foramen ovale or ventricular septal defect. Patient data was analyzed from hospital charts, including operative reports, post-operative course, and regular follow-up investigations. The protocol included cardiological examination by a single pediatric cardiologist. Echocardiographic examinations were performed immediately after arrival on the intensive unit, before discharge, and then after three, six, and 12 months, followed by yearly intervals. Pulmonary artery stenosis (PAS) was categorized into three groups according to the Doppler-measured pulmonary gradient: grade I (trivial stenosis) = increased pulmonary flow with a gradient below 25 mm Hg; grade II (moderate stenosis) = a gradient ranging from 25 to 49 mm Hg; and grade III (severe stenosis) = a gradient above 50 mm Hg. Follow-up data was available for all patients. The length of follow-up ranged from 1.2 to 9.7 years, median: 7.5 years (mean 6.1 years ± 14 months).*

**Results:** *During follow-up, 12 patients (70.6%) had no (or only trivial) PAS, five patients (29.4%) had moderate stenosis without progress, and no patient had severe PAS. Cardiac catheterization after arterial switch operation was performed in 11 patients (64.7%) and showed a good correlation with echocardiographic findings. During follow-up there was no re-intervention for PAS.*

**Conclusions:** *Direct reconstruction of the neo-pulmonary artery is a good option in TGA with antero-posterior position of the great vessels, with very satisfactory mid-term results. (Cardiol J 2010; 17, 6: 574–579)*

**Key words:** coronary heart disease, arterial switch, pulmonary arteries, outcomes, pediatric

**Address for correspondence:** Włodzimierz Kuroczyński, MD, PhD, Department of Cardiothoracic and Vascular Surgery, University Hospital Mainz, Langenbeckstrasse 1, D-55131 Mainz, Germany, tel. +49 (0) 6131 173935, fax: +49 (0) 6131 17 473935, e-mail: [kuroczynski@uni-mainz.de](mailto:kuroczynski@uni-mainz.de)

Received: 30.12.2009

Accepted: 27.04.2010

## Introduction

Since its first successful application in 1975 by Jatene, the anatomical correction known as the neonatal arterial switch operation (ASO) has been accepted as the procedure of choice for neonates with transposition of the great arteries (TGA) with or without ventricular septal defect (VSD). Current operative mortality is low and recent results are satisfactory [1]. A considerable number of series have been reported recently with excellent functional and clinical results [2, 3]. Potential problems following this procedure are stenoses or alterations in the growth of the great arteries. The commonest complication and cause of re-intervention in survivors after ASO is supravalvular stenosis of the neopulmonary artery, with a reported incidence ranging from 8% to 28% of survivors [4–6]. During the Lecompte maneuver, the pulmonary arterial trunk is brought towards the front to facilitate reanastomosis to the former aortic root. This brings the vessel under tension, putting it at risk to become stenotic at the suture line. In theory, this may be alleviated by the surgical technique of reconstruction of the neo-pulmonary root. Reconstruction of the original aorta after excision of the coronary buttons can be achieved in three ways: with two small button patches, with one oversized pantaloon-shaped patch from glutaraldehyde-treated autologous pericardium, or by direct pulmonary arterial anastomosis. The technique of direct pulmonary artery (PA) reconstruction was originally described by Pacifico et al. [7]. Mid-term results, however, have not been reported thus far. We have adopted this technique where feasible and therefore felt challenged to report our experience with a mean observation time of six years. It should also be noted that this is a single-surgeon experience (W.K.).

## Methods

Included in this retrospective study were all patients with a transposition of the great arteries, combined with an atrial septal defect (ASD) or VSD undergoing an arterial switch operation with direct PA reconstruction. Excluded were patients suffering from complex TGA, e.g. Taussig-Bing anomaly or side-by-side position of the great arteries. Coronary patterns were not considered a contraindication for this technique.

Patient data was analyzed from hospital charts, including operative reports, post-operative course, and regular follow-up investigations. The protocol included regular cardiological examination by a sin-

gle pediatric cardiologist (C.K.) after having obtained consent from the parents to include the data in this study. Echocardiographic examinations were carried out, including two-dimensional echocardiography and pulsed or continuous wave Doppler, depending upon the estimated gradient, as well as color Doppler measurements. For gradients below 25 mm Hg, measurements were done using pulsed-wave Doppler; for those above 25 mm Hg, we used continuous-wave Doppler. Studies were performed perioperatively, immediately after arrival in the intensive care unit, before discharge, and then three, six, and 12 months post-operatively, and annually thereafter.

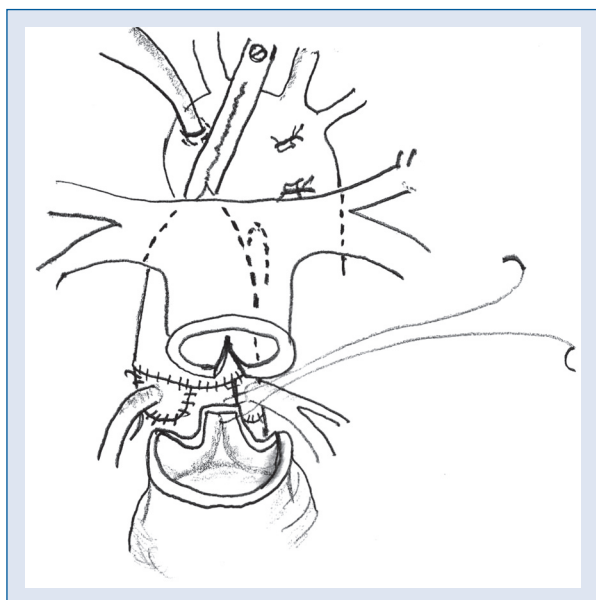
According to conventional clinical use, pulmonary artery stenosis (PAS) was categorized into three groups depending on the Doppler-measured pulmonary gradient: grade I (trivial stenosis) = increased pulmonary flow with a gradient below 25 mm Hg (pulsed-wave); grade II (moderate stenosis) = a gradient ranging from 25 to 49 mm Hg (continuous wave); and grade III (severe stenosis) = a gradient above 50 mm Hg (continuous wave).

Post-operative cardiac catheterization was performed in patients where there was a suspicion of additional lesions, such as MAPCA development, unclear coronary patterns, suspected residual defects or to evaluate markedly increased flow turbulence across the pulmonary anastomosis suggesting a higher degree of pulmonary stenosis on echocardiography. Cardiac catheterization was done routinely from the right femoral artery and femoral vein under mild sedation without intubation.

## Surgical technique

After standard median sternotomy, and before establishing extracorporeal circulation, the main pulmonary artery with its left and right branches was dissected extensively and mobilized well into the lung hilus, including circumferential dissection of the upper lobe arteries. The aortic arch and the supra-aortic branches were also mobilized extensively. Cardiopulmonary bypass was initiated after aortic and bicaval cannulation and the patent ductus arteriosus was then ligated and divided. Corrective surgery was performed under deep hypothermia with a rectal temperature of 18°C and low-flow cardiopulmonary bypass using crystalloid cold cardioplegia.

The aorta was transected approximately 2 to 3 mm above the commissures. The coronary ostia were excised out of the aortic root as 'U-shaped' buttons. In cases of a single coronary ostium, the second corresponding sinus would have to be excised nevertheless to provide the necessary symmetry for the anastomosis. Reimplantation of the coronaries

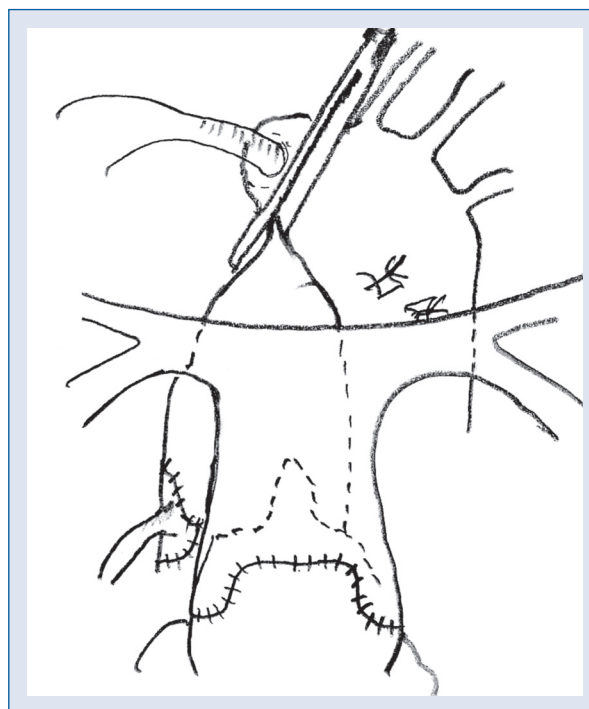


**Figure 1.** Schematic drawing of the operative technique. The distal pulmonary artery has been incised posteriorly after the Lecompte maneuver. The posterior commissure of the pulmonary valve is about to be resuspended into the incision (suture).

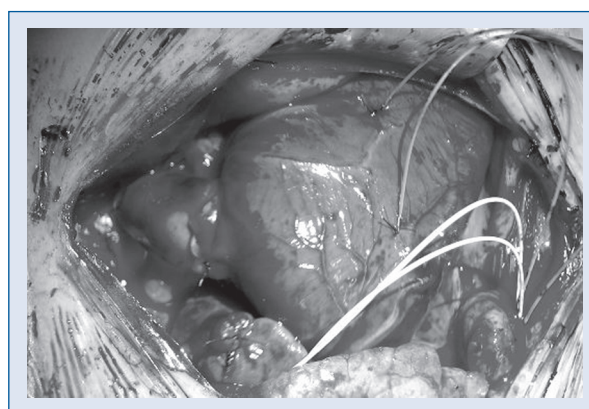
into the neo-aortic root does not interfere with PA-reconstruction even in cases of supra commissural positioning. After transection of the pulmonary trunk approximately 3 to 4 mm below the bifurcation, the coronary arteries were reimplemented into the neo-aortic root. Using the Lecompte maneuver, the distal PA was brought anterior to the aorta. The septal communications were closed in all patients through a right atriotomy during a brief period of hypothermic circulatory arrest (VSD) or in low-flow (ASD).

A crucial part of the technique for a direct pulmonary artery reconstruction is a small posterior incision in the upstream PA towards the pulmonary bifurcation (Fig. 1). Here, appropriate length of the vascular stump is needed, which is determined by the height of the former transection. The posterior commissure of the neo-pulmonary valve is then resuspended within this reversed-V-shaped triangle. The large intact anterior remnant of the aortic wall, corresponding to the non-excised non-coronary former aortic sinus, is incorporated full-length into the anterior circumference of the anastomosis. It can be tailored accordingly to fit a potential caliber mismatch between the proximal neo-pulmonary root and the distal native vessel (Figs. 1–3).

In our series, these anastomoses were performed with a continuous 6.0 absorbable monofilament suture (polydioxanone).



**Figure 2.** Schematic drawing of the operative technique. Completed direct anastomosis of the pulmonary artery. Wide flap of former non-coronary sinus avoids circumferential narrowing.



**Figure 3.** Intraoperative view after completion. Wide anterior flap of the native pulmonary root; relatively proximal position of the distal pulmonary artery part.

The study was approved by the local bioethical committee and all patients gave their informed consent.

## Results

Between June 1999 and February 2008, 17 patients with TGA fulfilled the inclusion criteria and

**Table 1.** Follow-up data at echocardiography and cardiac catheterization.

Pt.	ECHO gradient post-operation	ECHO gradient s/p 3 months	ECHO gradient s/p 6 months	ECHO gradient s/p 12 months	ECHO gradient last follow-up	Total follow-up time (months)	Cardiac catheterization gradient	Time at cardiac catheterization (months)
1	7	7	0	13	10	119		
2	18	14	16	14	16	118	5	9
3	10	18	19	24	22	114		
4	18	15	12	10	10	112	4	6
5	12	12	10	12	10	110	7	23
6	30	26	23	30	15	105	15	12
7	30	30	25	15	25	99	22	6
8	30	35	20	30	20	94	15	8
9	14	12	14	13	12	69		
10	20	30	20	15	12	67	10	34
11	0	0	0	0	0	56		
12	32	42	30	30	10	54	13	28
13	20	20	24	15	10	44	10	28
14	0	0	10	10	10	40	8	14
15	0	0	0	0	0	38	6	14
16	32	30	16	13	15	28		
17	15	10	13	12	0	16		

All echo and catheter gradients are given in mm Hg, all follow-up times are given in months, s/p — status post-operation

underwent an arterial switch operation with direct PA reconstruction by a single surgeon (W.K.). Thirteen (76.5%) of these patients were male and four (23.5%) female. Birth weight ranged from 2.4 to 4.6 kg ( $3.4 \pm 0.4$  kg). Simple TGA was present in ten (58.8%), and TGA with VSD in seven (41.2%) patients. A preoperative balloon-atrioseptostomy was performed in seven (41.2%) patients.

Age at operation ranged from two to ten days (mean: 4.6 days). Weight at operation ranged from 2.2 to 4.7 kg (mean: 3.4 kg). Of the 17 patients, ten (58.8%) underwent a simple ASO and seven (41.2%) underwent an ASO with VSD closure. There were no hospital or late deaths observed.

Follow-up data was available for all patients. The length of follow-up ranged from 1.2 to 9.7 years, with a mean duration of 6.1 years  $\pm$  14 months, and a median value of 7.5 years.

There were no bronchial compressions or coronary artery compressions observed after direct PA anastomosis.

Data from the regular post-operative echocardiographic examinations is presented in Table 1. In summary, no patient with a trivial gradient (12/17 = 70.6%) showed an increase over time. Most patients with an early moderate PA gradient above 25 mm Hg (5/17 = 29.4%) showed a regression over time. No severe gradient above 50 mm Hg was seen.

As mentioned, cardiac catheterization was performed in 11/17 patients (64.7%), for various reasons, between six and 34 months post-operatively. The data is also given in Table 1. The PA-gradient was measured in all of them and showed a good correlation with the echocardiographic findings at that time. The highest gradient measured was 22 mm Hg six months post-operatively. As was to be expected, direct measurements tended to be lower than echocardiographic calculations.

Accordingly, there has been no re-intervention (neither catheter intervention nor surgical procedure) for PAS during the follow-up so far.

## Discussion

Since the description of the first successful arterial switch operation by Jatene et al. [8] in 1975, results have constantly improved. It is among the most intellectually satisfying procedures commonly performed by congenital heart surgeons, because it seems truly curative. Today, the ASO is the procedure of choice for the treatment of newborns suffering from TGA with or without any additional cardiac malformation [1, 9]. Our retrospective study demonstrates that excellent hospital and intermediate-term survival can be achieved for patients undergoing this operation using the direct pulmonary anastomosis technique.



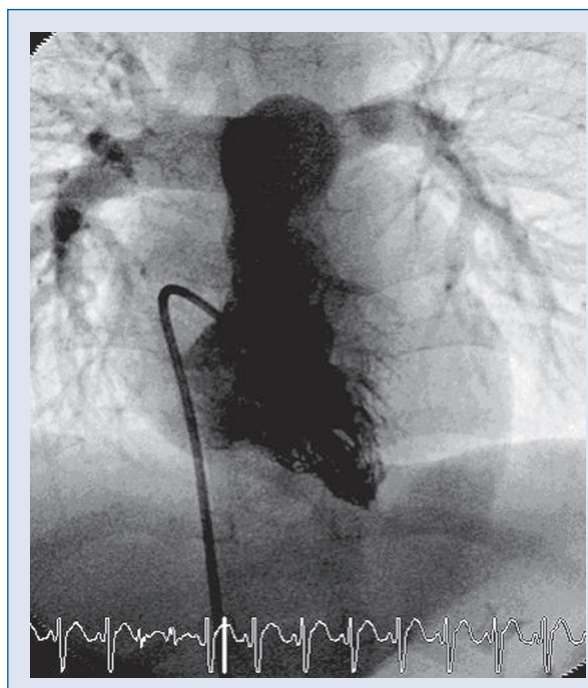
In many series, development of a supra-valvular pulmonary stenosis is the commonest post-operative complication after ASO [5, 6, 10, 11]. Various mechanisms have been suspected. Most of the increased gradient between the right ventricle and the PA system occurs during the first year after ASO, when somatic growth is most rapid. Circumferential narrowing at the suture line, or flattening of the main PA and its branches with reduction of the cross-sectional area caused by intensified anterior tension at the site of the anastomosis, either because of inadequate growth of the main PA or because of the Lecompte maneuver itself, have been reported [12]. In the series we present here, this was not observed. Even during longer-term somatic growth, no increase in gradient over time was detected.

Depending on PAS criteria and length of follow-up, the incidence of PAS eventually necessitating surgical re-intervention reported in the literature differs considerably [4–6, 10]. The data of Yamaguchi et al. [4] suggests that supra-valvular PAS is progressive with age. These findings are supported by Williams et al. [3, 13] who reported a doubling of the re-operation rate for relief of PAS after ASO (from 8% after 7.6 years to 16% after 13.8 years) in the same large study group. This is not evident in our presented series, which, however, is much smaller and has a mean follow-up duration of 6.3 years so far.

The classic PA reconstruction is generally achieved by filling the defects after coronary ostia explantation with a single inverted bifurcated pericardial patch (pantaloon) or with two separate button-shaped pericardial patches. Ullmann et al. [11] reported that an extended pericardial patch reconstruction with augmentation of the neo-pulmonary root and pulmonary artery is associated with a low incidence of late PAS after the ASO. The double pericardial button technique merely closes the holes in the proximal neo-pulmonary root. PAS seems to progress more slowly in patients undergoing the single 'pantaloon patch' technique, which provides enough tissue length for a wide neo-pulmonary circumferential anastomosis [12].

Although no patient in our series presented with a single coronary ostium, this would not have been considered a contraindication. Excision of the corresponding posterior sinus to provide the necessary symmetry for the inverted-V-shaped reconstruction of the back-wall would be the technical solution in these cases.

As the patch material itself may undergo degenerative changes over time, calcifications, consecutive shrinking, and distortion of the distal pul-



**Figure 4.** Right ventricular angiography (P-A projection) of patient no. 13, 28 months post-operatively: invasive gradient 10 mm Hg, straight outflow axis.

monary arteries have been observed, leading to gradient development late post-operatively [14].

This stimulated the interest in techniques trying to minimize or avoid any patch material for neo-pulmonary root reconstruction. An attractive surgical concept seemed the direct anastomosis without any patch material [7, 15]. Independent of the augmentation technique, it is now generally acknowledged that the left and right branches of the PA must be extensively dissected and mobilized to facilitate as tension-free an anastomosis as possible. For the direct PA anastomosis technique (with its relative lack of material) this is an especially crucial detail. Anterior augmentation is facilitated by the described inverted-V-shaped incision posteriorly which allows bringing up the whole root with its posterior commissure well into the back, straightening the outflow axis. This can achieve a surprisingly 'normal' anatomy (Fig. 4), whereas a plain circumferential suture line would again carry the risk of flattening.

Prifti et al. [12] and Serraf et al. [9], however, identified the technique of direct anastomosis without patch insertion as a risk-factor for subsequent development of PAS, which may explain why the technique has not become more widely accepted. In our mid-term single surgeon experience, we have

been able to demonstrate very satisfactory results so far. In our series of 17 patients, 12 (70.6%) had no or only trivial PAS (maximal cw-Doppler gradient < 25 mm Hg). Five patients (29.4%) had moderate stenosis (25 to 49 mm Hg), and no patient had severe PAS (> 50 mm Hg). Cardiac catheterization performed in 11 children revealed a maximum gradient of 22 mm Hg. Interestingly, all initially elevated echo gradients showed a decrease over time, presumably an effect of higher turbulence across the healing anastomosis early post-operatively. We consequently catheterized the five patients with moderate stenosis to obtain objective data. The remaining six children underwent cardiac catheterization for different indications, enabling us to gain additional data concerning the PA-gradients. Accordingly, there was no re-intervention for PAS during follow-up.

### Conclusions

In conclusion, we were able to demonstrate that direct reconstruction of the neo-pulmonary artery is a good option in TGA with antero-posterior position of the great vessels. It bears a very low incidence of development of PAS, at least in the mid-term. Doppler echocardiography is a useful tool for non-invasive follow-up, which has to be supplemented by cardiac catheterization to further evaluate suspected pathologies.

### Acknowledgements

The authors do not report any conflict of interest regarding this work.

### References

- Hövels-Gürich HH, Seghaye MC et al. Long-term results of cardiac and general health status in children after neonatal arterial switch operation. *Ann Thorac Surg*, 2003; 75: 935–943.
- Wetter J, Belli E, Sinzobahamvya N et al. Transposition of the great arteries associated with ventricular septal defect: Surgical results and long-term outcome. *Eur J Cardiothorac Surg*, 2001; 20: 816–823.
- Williams WG, McCrindle BW, Ashburn DA, Jonas RA, Mavroudis C, Blackstone EH. Outcomes of 829 neonates with complete transposition of the great arteries 12–17 years after repair. *Eur J Cardiothorac Surg*, 2003; 24: 1–9.
- Yamaguchi M, Hosokawa Y, Imai Y et al. Early and midterm results of the arterial switch operation for transposition of the great arteries in Japan. *J Thorac Cardiovasc Surg*, 1990; 100: 261–269.
- Haas F, Wottke M, Poppert H, Meisner H. Long-term survival and functional follow-up in patients after the arterial switch operation. *Ann Thorac Surg*, 1999; 68: 1692–1697.
- Kuroczyński W, Kampmann C, Choi YH et al. Die Behandlung supralvalvulärer Pulmonalstenosen nach arteriellen Switch-Operationen (ASO). *Z Kardiol*, 2001; 90: 498–502.
- Pacifico AD, Stewart RW, Barger LM. Repair of transposition of the great arteries with ventricular septal defect by an arterial switch operation. *Circulation*, 1983; 68 (suppl. 2): 49–55.
- Jatene AD, Fontes VF, Paulista PP et al. Successful anatomic correction of transposition of the great vessels. A preliminary report. *Arq Bras Cardiol*, 1975 ; 28: 461–464.
- Serraf A, Lacour-Gayet F, Bruniaux J et al. Anatomic correction of transposition of the great arteries in neonates. *J Am Coll Cardiol*, 1993; 22: 193–200.
- Angeli E, Raisky O, Bonnet D, Sidi D, Vouche PR. Late reoperations after neonatal arterial switch operation for transposition of the great arteries. *Eur J Cardio-Thorac Surg*, 2008; 34: 32–36.
- Ullmann MV, Gorenflo M, Bolenz C et al. Late results after extended pulmonary artery reconstruction in the arterial switch operation. *Ann Thorac Surg*, 2006; 81: 2259–2266.
- Prifti E, Crucean A, Bonacchi M et al. Early and long term outcome of the arterial switch operation for transposition of the great arteries: predictors and functional evaluation. *Eur Cardio-Thorac Surg*, 2002; 22: 864–873.
- Williams WG, Quaegebeur JM, Kirklin JW, Blackstone EH. Outflow obstruction after the arterial switch operation: A multiinstitutional study. *Congenital Heart Surgeons Society. J Thorac Cardiovasc Surg*, 1997; 114: 975–987.
- Bacha EA, Kalimi R, Starr JP, Quinones J, Koenig P. Autologous repair of supralvalvar pulmonic stenosis. *Ann Thorac Surg*, 2004; 77: 734–736.
- Carrel T, Mattila I, Pfammatter JP, Leijala M. Direct reconstruction of the pulmonary artery during the arterial switch operation: An interesting surgical option with excellent hemodynamic results. *Ann Thorac Surg*, 1998; 65: 1115–1119.