

Signs of myocardial ischemia on electrocardiogram correlate with elevated plasma cardiac troponin and right ventricular systolic dysfunction in acute pulmonary embolism

Maciej Kostrubiec, Krzysztof Jankowski, Justyna Pedowska-Włoszek, Blanka Puncewicz, Szymon Pacho, Barbara Lichodziejewska, Andrzej Łabyk, Anna Hryniewicz-Szymańska, Piotr Pruszczyk

Department of Internal Medicine and Cardiology, The Medical University of Warsaw, Poland

Abstract

Background: Plasma cardiac troponins (cTn) are frequently elevated in acute pulmonary embolism (APE). ST-segment abnormalities on electrocardiography are also commonly observed in APE patients. However, it has not been defined which ventricle is a potential source of cTn release. We assessed the potential relationship between electrocardiographic signs of myocardial ischemia, systolic dysfunction of both ventricles at echocardiography and cTn levels in APE.

Methods: We evaluated 94 consecutive patients (42 male, 52 female, aged 63 ± 19 years) with APE. On admission, blood samples were collected for cTnI or cTnT and standard 12-lead electrocardiogram was performed. The following signs of myocardial ischemia were analyzed: T-wave inversion [T (-)] and ST-depression or elevation (≥ 1 mV, at ≥ 2 leads). The assessment of systolic function of both ventricles was performed by echocardiography.

Results: In 33 (35%) patients, cTn exceeded the upper reference limit of our laboratory. The history of coronary artery disease (27% vs. 31%) and previous myocardial infarction (12% vs. 10%) did not differ in patients with elevated cTn [cTn (+)] and non-elevated cTn [cTn (-)]. In cTn (+) group T (-) or ST-depression were observed more frequently than in cTn (-) [32 (97%) vs. 46 (75%), $p < 0.01$]. However, both groups presented similar frequency of ST-elevation [7 (21%) vs. 11 (18%), $p = NS$]. Interestingly, cTn levels correlated with the number of leads with T (-) or ST-depression ($R = 0.30$, $p < 0.01$). Moreover, in cTn (+) group right ventricular systolic dysfunction was more frequent [15 (54%) vs. 4 (7%), $p = 0.0001$], while left ventricle contractility abnormalities occurred similarly in both groups [3 (11%) vs. 8 (15%), $p = NS$].

Conclusions: Signs of myocardial ischemia (ST-segment changes) on electrocardiography in APE correlate with an elevated cTn and with the impairment of right, but not left, ventricle systolic function at echocardiography. (Cardiol J 2010; 17, 2: 157–162)

Key words: pulmonary embolism, electrocardiogram, echocardiography, troponin

Address for correspondence: Maciej Kostrubiec, MD, PhD, Department of Internal Medicine and Cardiology, The Medical University of Warsaw, Lindleya 4, 02–005 Warszawa, Poland, tel: +48 22 502 11 44, fax: +48 22 502 21 42, e-mail: maciej.kostrubiec@wum.edu.pl

Received: 20.06.2009

Accepted: 7.09.2009

Introduction

The electrocardiographic (ECG) signs of pulmonary embolism are well described. They include T-wave inversion, ST-segment depression or elevation (pseudoinfarction), an $S_1Q_3T_3$ or $S_1S_2S_3$ pattern; complete or incomplete right bundle-branch block; and sinus tachycardia [1–3]. It can be assumed that the ECG findings in acute pulmonary embolism (APE) resulted from myocardial ischemia and/or increased right ventricular (RV) wall stress. Cardiac troponin (cTn) levels of both troponin I and T are frequently elevated in APE. Furthermore, troponins are accepted markers of increased risk of short-term mortality and other adverse outcomes, even regardless applied assay and cutoff value [4–6].

It has not been defined which ventricle is a potential source of cTn release. Therefore, we tried to assess the relationship between signs of myocardial ischemia at ECG, systolic dysfunction of both ventricles at echocardiography and plasma cTn levels in patients with diagnosed APE.

Methods

Patients and management of pulmonary embolism

The study population comprised consecutive patients with APE diagnosed and treated in our department. APE was confirmed by contrast-enhanced spiral computed tomography (16 MSCT, GE Bright Speed 'G') showing thromboemboli at least in segmental arteries. APE was diagnosed when symptoms of pulmonary embolism before the diagnosis lasted no longer than 14 days. On admission, clinical data and blood samples were collected. Echocardiography and standard ECG were performed within the first 24 hours after the diagnosis. Severity of APE was assessed according to current European Cardiac Society guidelines [7]. Patients with shock or hypotension formed a high risk group. The intermediate risk group included patients with RV overload at echocardiography and a positive troponin test, while the remaining patients without RV overload or signs of myocardial injury formed a low risk group.

The protocol of this study was approved by the local Bioethical Committee.

Biochemical assays

On admission, venous blood samples were collected for routine assays and for plasma cardiac troponin I or T (troponin T was assayed with ELECSYS, Roche and troponin I with Dimension® RxL, Dade

Behring). Plasma levels of cTnT $> 0.03 \mu\text{g/L}$ and cTnI $> 0.07 \mu\text{g/L}$ indicated myocardial injury and were considered a 'positive' test. The physicians evaluating the echocardiography were unaware of troponin results.

Electrocardiography analysis

Original ECG tracings were analyzed independently by two experienced cardiologists who were unaware of the patients' history, laboratory and echocardiographic results. The following ECG abnormalities suggestive of myocardial ischemia were evaluated [8]: T-wave inversion ($\geq 1 \text{ mV}$), ST-depression or elevation ($\geq 1 \text{ mV}$), at least in two contiguous leads [9]; right bundle branch block (QRS $> 0.11 \text{ s}$ and S wave in lead I and terminal R wave in V1 with amplitude $> 0.15 \text{ mV}$); $S_1S_2S_3$ pattern (S wave in leads I, II and III with amplitude $> 0.15 \text{ mV}$) or $S_1Q_3T_3$ pattern (S wave in lead I and Q wave in lead III with amplitude $> 0.15 \text{ mV}$, associated with T-wave inversion in lead III). Leads I, aVL and V5, V6 were considered as lateral leads, II, III and aVL inferior and V1–V4 anterior ones.

Echocardiography

Transthoracic echocardiography (TTE) for the assessment of ventricular systolic abnormalities and RV overload was performed using a Philips iE33 echocardiographic system (Bothell, WA, USA). The examinations were digitally recorded by an experienced echocardiographer blinded to biochemical and ECG results. Right ventricular overload was diagnosed when echocardiography showed RV/LV > 0.6 with RV free wall hypokinesis, and/or elevated tricuspid valve pressure gradient exceeding 30 mm Hg with a shortened acceleration time of pulmonary ejection below 80 ms.

Right ventricular systolic function was assessed quantitatively. Hypokinesis of RV free wall was reported. Segmental analysis of left ventricular (LV) systolic function was performed. The 17 segments eligible for analysis were assessed as normokinetic, hypokinetic, akinetic or dyskinetic [10]. Left ventricular systolic dysfunction was diagnosed when abnormalities affected at least one segment.

Statistical analysis

Data characterized by a normal distribution is expressed as mean followed by the standard deviation. Parameters without such distribution are expressed as a median with a range. Student's or Mann-Whitney's tests were used for comparing the two groups. The χ^2 test was used to compare dis-

Table 1. Patient characteristics according to plasma troponin levels.

	All patients (n = 94)	cTn (-) (n = 61)	cTn (+) (n = 33)	p
Age (years)	63 ± 19	62 ± 21	67 ± 16	NS
Sex (male/female)	42 (45%)/52 (55%)	27 (44%)/34 (56%)	15 (45%)/18 (55%)	NS
Heart rate [bpm]	95 ± 26	94 ± 24	98 ± 30	NS
Left/right axis deviation	29 (31%)/8 (8%)	17 (28%)/3 (5%)	12 (36%)/5 (15%)	NS
Right bundle branch block	21 (22%)	8 (13%)	13 (39%)	0.01
S ₁ Q ₃ T ₃	19 (20%)	7 (11%)	12 (36%)	< 0.01
T (-) or ST depression in lateral leads (I, aVL, V5, V6)	39 (41%)	19 (31%)	20 (61%)	< 0.01
T (-) or ST depression in inferior leads (II, III, aVF)	54 (57%)	29 (48%)	25 (76%)	0.01
T (-) or ST depression in anterior leads (V1–V4)	63 (67%)	35 (57%)	28 (85%)	0.01
Number of lead with T (-) or ST-depression	2.1 ± 1.6	1.8 ± 1.5	2.9 ± 1.4	< 0.001
ST-segment elevation	18 (19%)	11 (18%)	7 (21%)	NS
LVSD (n = 87)	11 (13%)	8 (14%)#	3 (11%)*	NS
RVSD (n = 87)	19 (22%)	4 (7%)#	15 (54%)*	0.0001
RV overload	54 (57%)	27 (44%)	27 (82%)	0.001

*n = 28, #n = 59; LVSD — left ventricular systolic dysfunction; RVSD — right ventricular systolic dysfunction; cTn (-) — non-elevated cTn; cTn (+) — elevated cTn, T (-) — T wave inversion; S₁Q₃T₃ — S wave in lead I and Q in III and T wave inversion in III

crete variables. The dependent variables were compared by Friedman ANOVA or Wilcoxon matched pairs test. All tests were two-sided. Data was considered significant at $p < 0.05$. STATISTICA software (StatSoft, Inc. 2008) was used for statistical calculations.

Results

Patients' characteristics

The study included 94 consecutive patients with APE, 42 males and 52 females aged 63 ± 19 years (Table 1). Clinically high-risk APE was diagnosed in five patients, while the remaining 89 patients were normotensive on admission. Low risk APE was found in 34 patients, while 51 normotensive cases with right ventricular dysfunction at echocardiography and four people with elevated cTn formed an intermediate risk subgroup [7].

Cardiac troponin

In 33 (35%) patients cTn indicated myocardial injury. Elevated troponin levels were found in four of five (80%) high risk patients and in 29 of 55 (53%) intermediate risk cases. The frequency of coronary artery disease (27% vs. 31%) and previous myocardial infarction (12% vs. 10%) did not

differ between patients with elevated cTn and non-elevated cTn.

ECG analysis

ECG signs of myocardial ischemia were present in all five (100%) high risk patients, 49 (86%) with intermediate risk and in 27 (75%) low risk cases. In the group with elevated cTn, negative T-waves or ST-depression were observed significantly more often than in patients without myocardial injury, 32 (97%) vs. 46 (75%), $p < 0.01$; number of leads with negative T or ST-depression 2.9 ± 1.4 vs. 1.8 ± 1.5 , $p < 0.001$, respectively. The most infrequent ST-segment changes were found at lateral leads, 39 (41%) patients. Negative T-waves or ST-depressions in inferior leads were found in 54 (57%) patients, while in anterior leads they appeared in 63 (67%; Table 1). It should be underlined that ST changes were more frequent in patients with elevated cTn than in cTnT (-) group [lateral leads 20 (61%) vs. 19 (31%), $p < 0.01$; inferior leads 25 (76%) vs. 29 (48%), $p = 0.01$; anterior leads 28 (85%) vs. 35 (57%), $p = 0.01$; respectively]. Moreover, elevated cTn correlated with the number of leads with negative T-wave or ST-depression ($R = 0.30$, $p < 0.01$).

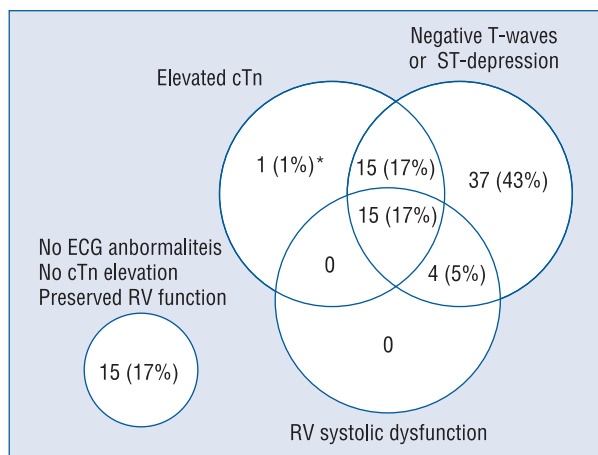


Figure 1. Number of patients with acute pulmonary embolism and troponin (cTn) elevation, right ventricle (RV) systolic dysfunction and negative T wave or ST-segment depression (n = 87); *patient with RV overload.

Echocardiography

Image quality allowed assessment of the systolic function of both ventricles in 87 (93%) patients. Left ventricular regional contractility abnormalities were present in 11 (13%) patients and varied from hypokinesia of one segment to profound abnormalities affecting 11 segments. Global LV systolic dysfunction was found in one (1%) case (ejection fraction 40%). There was no difference in the frequency of LV contractility abnormalities between patients with elevated and non-elevated cTn (Table 1). RV overload was found in 54 (57%) patients. RV contractility abnormalities were present in 19 (22%) cases. Fifteen (79%) patients had only hypokinesia of the free wall (McConnell sign), while the systolic dysfunction of both free wall and apical segments was noted in four (21%) cases. RV overload and RV contractility abnormalities were significantly more frequent in patients with elevated cTn [27 (82%) vs. 27 (44%), $p = 0.001$ and 15 (50%) vs. 4 (7%), $p = 0.0001$, respectively].

Only one patient with regional LV contractility abnormalities on echocardiography presented negative T-waves and ST-segment depression. All patients with RV systolic dysfunction had negative T-waves or ST-depression in at least two contiguous leads, while there was normal RV systolic function in 16 (23%) cases without any signs of ischemia on ECG ($p = 0.02$). Both RV contractility abnormalities and negative T-waves or ST-depression in at least two contiguous leads were found in 15 (54%) patients with elevated cTn (Fig. 1). There was normal RV systolic function and no signs of ischemia

on ECG in the group of 15 (27%) patients with un-elevated cTn levels. Interestingly, only one patient with elevated cTn had normal RV systolic function and no signs of ischemia on ECG; however the RV overload was noticed.

ST-segment elevation

ST-segment elevation of more than or equal to 1 mV in at least two contiguous leads was present in 18 (19%) patients. Seven of these presented elevated cTn levels, while the other 11 cases showed no biochemical signs of myocardial injury ($p = NS$). ST-segment elevation was found in anterior leads in 17 (94%) patients and in one case with simultaneous elevation in lateral leads. One patient had ST-segment elevation in inferior leads. ST-segment elevation was present in two (40%) high risk patients, eight (15%) with intermediate risk and in eight (24%) low risk cases. Interestingly, ST-segment elevation was present on ECG of four patients with a history of coronary heart disease or myocardial infarction and on ECG of 12 patients without such a history. In only one (5%) patient with RV contractility abnormalities was ST-segment elevation found, while it was noticed in five (45%) with LV systolic dysfunction ($p < 0.05$). Interestingly, ten (56%) patients with ST-segment elevation had no detectable RV nor LV systolic dysfunction, including two cases with elevated cTn and other signs of RV overload. There was no correlation between the extent of LV systolic dysfunction and signs of myocardial injury.

Discussion

A physiological explanation of ECG abnormalities associated with acute pulmonary embolism remains difficult to define [11]. When the levels of biomarkers of cardiac injury and ischemia were found to be increased in some patients with APE [4, 5], myocardial injury of RV was suggested to be a potential cause of cTn release. However, studies on animal models showed that RV failure during pulmonary artery constriction develops in spite of increased coronary blood flow and RV oxygen consumption [12]. Thus, mechanisms different from ischemia may contribute to progressive RV failure and myocardial injury after pulmonary embolism.

The study based on creatine kinase assessment, a less sensitive biomarker of myocardial injury, and scintigraphy, failed to demonstrate unequivocal evidence of ischemia in patients with T-wave changes over the anterior precordial leads [11, 13]. However, elevations of creatine kinase that

met enzyme criteria of acute infarction were reported in 7.7% of patients with pulmonary emboli and absence of known ischemic heart disease [14]. In our group, all patients with RV systolic dysfunction showed negative T-wave in the precordial leads. Importantly, all of them had preserved left ventricular systolic function.

Moreover, signs of myocardial ischemia on ECG commonly observed in acute pulmonary embolism, were also suggested to be a useful, simple, inexpensive tool for initial risk stratification of patients with acute major pulmonary embolism [15, 16]. In our study, the presence of ECG signs of myocardial ischemia in all high risk patients, and 86% with intermediate risk, seems to confirm such reports.

Also, cardiac troponins frequently elevated in APE were found to be associated with short-term death and other adverse outcomes [4, 5]. The prognostic value of troponin was consistent for both troponin I and T and allowed the identification of a high risk group even among patients hemodynamically stable on admission [6].

Coronary angiography was reported to be performed in some patients with APE. Despite symptoms suggestive of acute coronary syndrome, with co-existing electrocardiographic abnormalities and elevated troponin levels, unchanged coronary vessels were eventually visualized [17–19]. Some authors suggest that morphology of negative T-waves and their appearance in particular leads (III and V1) allows the differentiation between APE and acute coronary syndrome in patients with negative T-waves in the precordial leads [20, 21].

In our study, ST-segment abnormalities (negative T-waves or ST-segment depression) were the most frequent in anterior leads (67% patients with APE). ST-segment changes appeared more often in patients with elevated cTn than in patients with normal levels. Moreover, elevated cTn correlated with the number of leads with negative T-wave or ST-segment depression. These results suggest that myocardial injury caused by acute RV overload manifests on ECG as negative T-waves or ST-segment depression. Moreover, elevated cTn in APE seems to correspond with the extent of myocardial ischemia on ECG.

RV overload was noticed in 82% of patients with elevated cTn, and RV contractility abnormalities were present in 50% of them. All patients with RV contractility abnormalities had negative T-waves or ST-segment depression in at least two contiguous leads, while only one (9%) patient with LV systolic dysfunction in echocardiography had negative

T waves or ST-segment depression. Such observations indicate that ECG changes are probably caused by injury to the right ventricle. The cause of ST-segment elevation in APE seems to be more complex and can result from the pre-existing LV systolic dysfunction, RV overload with cTn release or a combination of the above.

In our study the S₁Q₃T₃ pattern; S₁S₂S₃ pattern; complete or incomplete right bundle-branch block; and sinus tachycardia were not associated with cTn elevation or RV contractility abnormalities.

The main limitation of our study is the fact that it is a single center study. The diagnosis of APE depended on a spiral computed tomography, and so other pulmonary embolism, perhaps with different characteristics, could have been missed. In some patients we had results of troponin T, while in others results of troponin I. However both were reported as having a similar prognostic value [4]. Moreover, we could not exclude the pre-existing RV or LV systolic dysfunction before the current episode of APE. In our study, due to lack of coronary angiography data, we cannot definitely exclude the significant occlusion of coronary vessels, especially in patients with ST-segment elevation and elevated cTn. However, in most of them, normal LV systolic function and RV overload typical for APE was confirmed on echocardiography. The only patient with ST-segment elevation, LV contractility abnormalities and positive cTn had also significant RV overload. We should also remember that in the PRAGUE trial the observed prevalence of normal coronary angiography in patients presenting with acute chest pain and ST-elevations was 2.6% [19]. Among these, the diagnosis of pulmonary embolism at discharge was also made.

Conclusions

In acute pulmonary embolism, signs of myocardial ischemia on ECG correlate with an elevated cardiac troponin and with the impairment of right (but not left) ventricle contractility at echocardiography. Moreover, elevation of cardiac troponin seems to be related to the extent of changes of ST segment on ECG.

Acknowledgements

This study was supported by research grant KBN: N N402 080934, Warsaw, Poland.

The authors do not report any conflict of interest regarding this work.

References

1. Rodger M, Makropoulos D, Turek M et al. Diagnostic value of the electrocardiogram in suspected pulmonary embolism. *Am J Cardiol*, 2000; 86 (A10): 807–809.
2. Sreeram N, Cheriex EC, Smeets JL, Gorgels AP, Wellens HJ. Value of the 12-lead electrocardiogram at hospital admission in the diagnosis of pulmonary embolism. *Am J Cardiol*, 1994; 73: 298–303.
3. Chan TC, Vilke GM, Pollack M, Brady WJ. Electrocardiographic manifestations: Pulmonary embolism. *J Emerg Med*, 2001; 21: 263–270.
4. Becattini C, Vedovati MC, Agnelli G. Prognostic value of troponins in acute pulmonary embolism: A meta-analysis. *Circulation*, 2007; 116: 427–433.
5. Pruszczyk P, Bochowicz A, Torbicki A et al. Cardiac troponin T monitoring identifies high-risk group of normotensive patients with acute pulmonary embolism. *Chest*, 2003; 123: 1947–1952.
6. Kostrubiec M, Pruszczyk P, Bochowicz A et al. Biomarker-based risk assessment model in acute pulmonary embolism. *Eur Heart J*, 2005; 26: 2166–2172.
7. Torbicki A, Perrier A, Konstantinides S et al. Guidelines on the diagnosis and management of acute pulmonary embolism: The Task Force for the Diagnosis and Management of Acute Pulmonary Embolism of the European Society of Cardiology (ESC). *Eur Heart J*, 2008; 29: 2276–2315.
8. Thygesen K, Alpert JS, White HD. Universal definition of myocardial infarction. *Eur Heart J*, 2007; 28: 2525–2538.
9. Hathaway WR, Peterson ED, Wagner GS et al. Prognostic significance of the initial electrocardiogram in patients with acute myocardial infarction. GUSTO-I Investigators. Global Utilization of Streptokinase and t-PA for Occluded Coronary Arteries. *JAMA*, 1998; 279: 387–391.
10. Schiller NB, Shah PM, Crawford M et al. Recommendations for quantitation of the left ventricle by two-dimensional echocardiography. American Society of Echocardiography Committee on Standards, Subcommittee on Quantitation of Two-Dimensional Echocardiograms. *J Am Soc Echocardiogr*, 1989; 2: 358–367.
11. Wood KE. Major pulmonary embolism: review of a pathophysiologic approach to the golden hour of hemodynamically significant pulmonary embolism. *Chest*, 2002; 121: 877–905.
12. Schmitto JD, Doerge H, Post H et al. Progressive right ventricular failure is not explained by myocardial ischemia in a pig model of right ventricular pressure overload. *Eur J Cardiothorac Surg*, 2009; 35: 229–234.
13. Ferrari E, Imbert A, Darcourt J. No scintigraphic evidence of myocardial abnormality in severe pulmonary embolism with electrocardiographic signs of anterior ischemia. *Eur Heart J*, 1995; 16 (suppl.): 269.
14. Adams JE, III, Siegel BA, Goldstein JA, Jaffe AS. Elevations of CK-MB following pulmonary embolism. A manifestation of occult right ventricular infarction. *Chest*, 1992; 101: 1203–1206.
15. Geibel A, Zehender M, Kasper W, Olschewski M, Klima C, Konstantinides SV. Prognostic value of the ECG on admission in patients with acute major pulmonary embolism. *Eur Respir J*, 2005; 25: 843–848.
16. Kaczynska A, Bochowicz A, Kostrubiec M, Szulc M, Pruszczyk P. Electrocardiography and prediction of myocardial damage in patients with acute pulmonary embolism. *Pol Arch Med Wewn*, 2004; 112: 1039–1046.
17. Ludwik B, Lewczuk J, Piszko P et al. Normal coronary angiogram in patient with diagnosis of acute coronary syndrome with ST segment elevation. Was it possible to recognise acute pulmonary embolism earlier? *Kardiol Pol*, 2006; 64: 68–71.
18. Pruszczyk P, Szulc M, Horszczaruk G, Gurba H, Kobylecka M. Right ventricular infarction in a patient with acute pulmonary embolism and normal coronary arteries. *Arch Intern Med*, 2003; 163: 1110–1111.
19. Widimsky P, Stellova B, Groch L et al. Prevalence of normal coronary angiography in the acute phase of suspected ST-elevation myocardial infarction: experience from the PRAGUE studies. *Can J Cardiol*, 2006; 22: 1147–1152.
20. Hayden GE, Brady WJ, Perron AD, Somers MP, Mattu A. Electrocardiographic T-wave inversion: differential diagnosis in the chest pain patient. *Am J Emerg Med*, 2002; 20: 252–262.
21. Kosuge M, Kimura K, Ishikawa T et al. Electrocardiographic differentiation between acute pulmonary embolism and acute coronary syndromes on the basis of negative T waves. *Am J Cardiol*, 2007; 99: 817–821.