

Wpływ mostków mięśniowych na odległy wynik zabiegów angioplastyki wieńcowej przeprowadzonych w proksymalnych segmentach gałęzi zstępującej przedniej

Influence of myocardial bridging on the long-term results of coronary angioplasty performed in the proximal segment of the left anterior descending artery

Robert Gil¹, Tomasz Pawłowski¹, Artur Krzywkowski²,
Sebatian Ciuka², Rafał Żurawski²

¹Central Hospital for the Ministry of Home Affairs and Administration in Warsaw

²Pomeranian Medical University in Szczecin

Abstract

Background: *Myocardial bridging (MB) is defined as an intra-myocardial course of the epicardial portion of the coronary artery which occurs mostly in the area of the left anterior descending artery (LAD). The aim of this study was to evaluate the influence of MB on immediate and late outcomes of percutaneous coronary intervention in comparison with results for a population without MB.*

Material and methods: *For the purposes of this study, 94 patients (mean age 54.5 ± 9.3 years) with a proximal LAD lesion were included. They were divided into Group 1 (42 patients with MB) and Group 2 (50 patients without MB). Off-line quantitative coronary angiography was performed at the lesion and MB sites before and after the coronary intervention. The analysis included minimal lumen and reference diameters (MLD and Ref.D respectively) and also a percentage of diameter stenosis (%DS). Systolic MB compression (MBcomp) was defined as the %DS at the narrowest point of the MB during the systolic phase. Patients underwent clinical and angiographic follow-up studies between 5 and 7 months after the initial procedure.*

Results: *There were no differences between the groups studied in terms of clinical, demographic and angiographic characteristics. QCA results were similar for both groups. Mean LAD compression by MB arose from $55 \pm 21\%$ to $72 \pm 18\%$ ($p = NS$) after angioplasty. A significant correlation was found between the degree of myocardial bridging compression and post-procedural MLD ($r = 0.79$; $p < 0.01$). During the follow-up there was no significant difference between Group 1 and Group 2 in the occurrence of restenosis in groups (14.2 and 14%, respectively), although the groups varied in the presence of angina recurrence and positive exercise test results (50% and 20% respectively; $p < 0.05$).*

Adres do korespondencji: Dr hab. med. Robert J. Gil

Klinika Kardiologii Inwazyjnej, CSK MSWiA

ul. Wołoska 137, 02-507 Warszawa

e-mail: shortytom@o2.pl

Nadesłano: 10.01.2005 r

Przyjęto do druku: 14.02.2005 r.

Conclusions: *Our results showed that the presence of MB has no major influence on restenosis rates and that the electrocardiographic stress test has a low predictive value for the detection of restenosis.* (Folia Cardiol. 2005; 12: 284–290)

myocardial bridging, quantitative coronary angiography, stress test

Introduction

From the anatomical point of view, myocardial bridging (MB) is defined as an intra-myocardial course of the epicardial portion of the coronary artery. Although coronary angiography only reveals evidence of MB in 0.5–12% [1] of the population, pathologists report an incidence of 15–85% [2, 3]. The left anterior descending artery (LAD) is involved in the majority of cases and the typical angiographic presentation of MB is the so-called „milking effect” [4], which occurs during cardiac systole. The presence of the MB phenomenon has been described in earlier reports in relation to myocardial ischaemia, infarction, arrhythmias and sudden death [4–6]. Recent studies using intracoronary ultrasound have shown that vessel compression exists not only during systole, but also at the end of diastole [8]. Intracoronary Doppler examinations have shown that MB is responsible for retrograde flow into proximal portions of the artery, which may be responsible for atheroma formation [9].

We hypothesised that a late outcome of percutaneous treatment of coronary stenoses located proximally to the portion of the artery involved by MB may be unfavourable in this subset of patients. The aim of this study, therefore, was to evaluate the influence of MB on immediate and late outcomes of percutaneous coronary intervention and to compare them with the results for a population without MB.

Material and methods

Patient selection

Between January 1997 and March 2000 4,652 diagnostic angiographies were performed in our institution. MB was observed in 278 patients (5.9%), although only in 42 (15%) of them was atherosclerotic lesion found proximally to MB (Group 1). These were compared with the second group of 50 consecutive patients who underwent percutaneous coronary intervention for lesion of the proximal LAD (Group 2). All patients were referred for diagnostic coronary angiography as a result of previous myocardial infarction (48.8%) or a history of stable angina pectoris (51.2%). Baseline and angiographic characteristics are shown in Tables 1 and 2.

Coronary procedures and quantitative coronary angiography

All patients underwent the procedure with femoral access, using 6 and 7 Fr guiding catheters. At 48 h before the procedure the patients received acetylsalicylic acid (300 mg/24 h) and 500 mg/24 h of ticlopidine. After insertion of the arterial sheath each patient received heparin (70–100 IU per kg) intravenously and additional bolus to maintain an activated clotting time (ACT > 300 s).

Coronary angioplasty procedures in both groups were conducted using the conventional balloon technique and coronary stenting if necessary. Procedural endpoints were residual diameter stenosis < 30% by visual estimation and no major dissection in the case of plain balloon angioplasty and < 15% in cases followed by stenting. Angiographic runs were recorded after intra-coronary administration of ~300 µg of nitroglycerin to achieve maximal MB compression.

Only projections with a proper lesion and MB visualisation were chosen for analysis (AP view with cranial deviation or right oblique view) in Group 1. Off-line quantitative coronary angiography (QCA) analyses were performed at the core laboratory by experienced technicians. Angiographic measurements were performed with a computer-assisted system using an automated edge detection algorithm (MEDIS Co, Eindhoven, Netherlands). The QCA analyses were performed separately for the coronary obstruction site and MB in Group 1. Systolic MB compression (MBcomp) was defined as the %DS of the narrowest point of myocardial bridging during the systolic phase.

Table 1. Baseline characteristics

Tabela 1. Wstępna charakterystyka

	Group 1	Group 2	p
Mean age (years)	54 ± 10	55 ± 8	NS
Hypertension (%)	42	38	NS
Diabetes mellitus (%)	6.25	9.5	NS
Dyslipidemia (%)	43	51	NS
Current smoking (%)	38	32	NS

Follow-up assessment

Patients underwent clinical and angiographic follow-up studies between 5 and 7 months after the initial procedure. Follow-up evaluation of patients was to consist of physical examination, an electrocardiographic stress test and control coronary angiography. The criteria used for positive results of the stress test followed those previously described [7]. Restenosis was considered if the percentage of diameter stenosis was $> 50\%$ on quantitative coronary angiography. However, if the patient was unable to come back for follow-up assessment, a precise clinical history was obtained by a telephone call.

Intra-observer variability

All angiographic recordings were analysed by one independent observer. To assess the intra-observer variability a repeat analysis was performed 3 weeks later. None of the procedural data or information on the patients was made available to the observer. For the measurement of the minimal lumen diameter by angiography intra-observer correlation coefficient and error were 0.94 and $4.5 \pm 3.1\%$, respectively. As for the degree of MB compression analysed by QCA, intra-observer correlation coefficient and error were 0.95 and $5.4 \pm 3.8\%$, respectively.

Statistical analysis

All values were expressed as mean standard deviation. Continuous variables were compared with a 2-tailed Student's t-test. A linear regression analysis was made to calculate correlations between study parameters. A value of $p < 0.05$ was considered statistically significant.

Results

Immediate procedural outcomes

The two homogeneous populations were compared with regard to demographic, angiographic, and procedural data. There were no peri-procedural complications related to the procedures in either group. A total of 15 patients in Group 1 (35%) and 21 (42%) in Group 2 required stent implantation.

Table 2 refers to quantitative coronary angiography analyses obtained in both groups after the procedure. There was no difference between the groups in terms of luminal and reference segment diameter. Furthermore, separate analyses were performed for cases with and without stent implantation. There were no post-procedural differences between the two groups in minimal lumen diameter either after stenting or balloon angioplasty (2.86 ± 0.12 and 2.75 ± 0.40 mm respectively, $p = \text{NS}$ in Group 1 and 2.82 ± 0.15 and 2.71 ± 0.25 mm, $p = \text{NS}$ in Group 2), although a trend to a higher reference diameter in the stented subgroup was observed in comparison to the plain balloon angioplasty subgroup (3.19 ± 0.47 and 2.95 ± 0.29 mm respectively, $p = \text{NS}$ in Group 1 and 3.11 ± 0.39 and 2.89 ± 0.56 mm in Group 2, $p = \text{NS}$).

Angiographic presence of myocardial bridging

Mean systolic LAD compression by MB before a procedure in Group 1 was $55 \pm 21\%$. After the procedure the increase in a degree of MB compression was seen in 20 patients (57.1%)

Table 2. Angiographic results obtained in both groups

Tabela 2. Wyniki badań angiograficznych, uzyskane w obu grupach

	Group 1	Group 2	p
QCA measurements pre procedure			
MLD [mm]	1.1 ± 0.26	1.08 ± 0.48	NS
Ref. D [mm]	2.96 ± 0.37	2.86 ± 0.51	NS
%DS (%)	73.1 ± 15.4	68.8 ± 11.7	NS
Lesion length [mm]	10.9 ± 2.4	9.7 ± 2.1	NS
QCA measurements post procedure			
MLD [mm]	2.82 ± 0.36	2.96 ± 0.52	NS
Ref. D [mm]	3.12 ± 0.25	3.19 ± 0.58	NS
%DS (%)	9.2 ± 2.41	11.2 ± 3.14	NS
Percentage of stents (%)	35	42	NS
Stent size [mm]	3.15 ± 0.39	3.21 ± 0.51	NS
Stent length [mm]	14.9 ± 1.4	13.5 ± 4.11	NS
Max. balloon pressure [atm]	14.4 ± 3.79	13.9 ± 2.5	NS

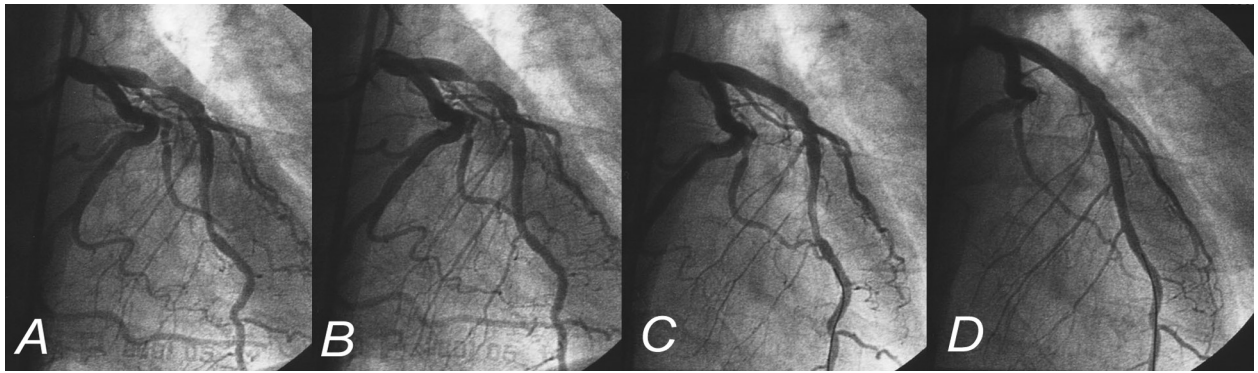


Figure 1. The left anterior descending artery with a significant lesion in its proximal segment and myocardial bridging in the systole (A) and diastole (B) before the intervention. (C) and (D) present angiograms in the systole and diastole after the procedure. Note the difference in the systolic compression of the MB between the pre and post-procedural vessel images

Rycina 1. Gałąź zstępująca lewej tętnicy wieńcowej z istotnym zwężeniem w odcinku proksymalnym i mostkiem mięśniowym w skurczu (A) i rozkurczu (B) przed zabiegiem (C) i przedstawiają angiogramy w skurczu i rozkurczu po zabiegu (D). Należy zwrócić uwagę na różnicę skurczowego zwężenia pod mostkiem mięśniowym w obrazach naczyń przed zabiegiem i po nim

(Fig. 1) and in the remaining patients there was no change in this parameter. The mean value of MBcomp increased to $72 \pm 18\%$ after the procedure (pre vs. post, $p = \text{NS}$). In contrast, there was a trend to a larger MBcomp in the stented patients of Group 1 in comparison with patients in whom plain balloon angioplasty was performed, although the differences were not statistically significant ($73 \pm 19\%$ and $65 \pm 15\%$ respectively, $p = \text{NS}$). Regression analysis showed that the degree of myocar-

dial bridging compression was correlated with MLD post procedure ($r = 0.79$, $p < 0.01$) (Fig. 2).

Follow-up results

There were no major adverse cardiac events such as death, myocardial infarction and emergency revascularisation in the population as a whole during hospital stay and at early 30-day follow-up. Only in 3 (5.4%) cases was a small haematoma found at the femoral artery cannulation site.

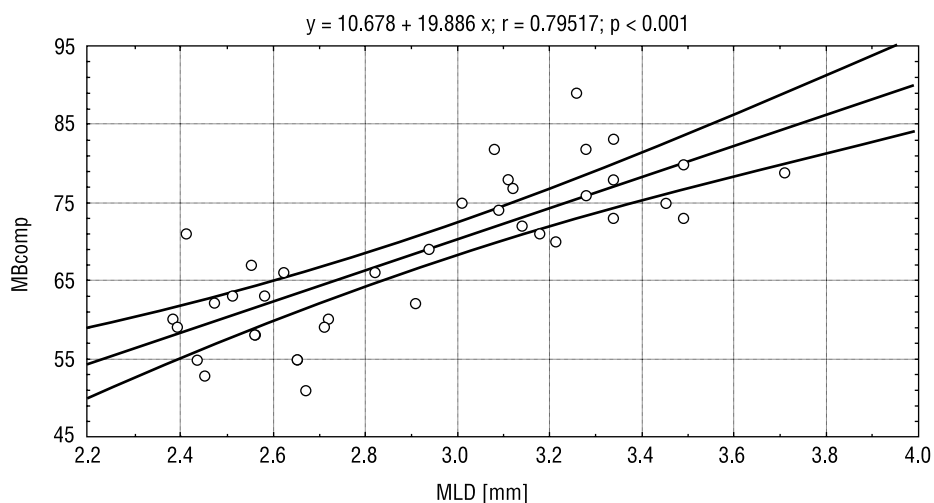


Figure 2. Correlation between the degree of myocardial bridging (MB) compression and the minimal lumen diameter (MLD) achieved after the procedure

Rycina 2. Związek pomiędzy stopniem ucisku przez mostek mięśniowy (MB) a najmniejszym wymiarem światła naczynia (MLD) uzyskanym po zabiegu

Clinical follow-up was obtained for all the patients studied. There were no deaths, but one patient (2.3%) in Group 1 and two patients (4%) in Group 2 experienced Q-wave myocardial infarctions. In all 21 (50%) patients from Group 1 complained of persistent angina and the result of their stress test was considered positive. Only in 10 (20%) patients in Group 2 was angina found to persist ($p < 0.05$ between groups). When a multivariable regression model was used, neither clinical nor angiographic predictors of angina persistence were found at follow-up.

During follow-up angiography was performed on 39 (94%) patients of Group 1 and 44 (88%) patients of Group 2 (mean angiography time 6.7 ± 2.6 months; range 4–9 months). Recurrent stenosis in a previously dilated site (restenosis) was found in 6 (14.2%) patients of Group 1 and 7 patients of Group 2 (14%), $p = \text{NS}$. The calculated sensitivity of the exercise test was 83% and 85%, Group 1 and Group 2 respectively. The specificity of the test was 51% and 90% respectively.

Table 3 depicts a multivariable regression analysis of the occurrence of coronary restenosis in Group 1.

Discussion

The major findings of this paper are: 1) the presence of MB does not influence the restenosis rate after percutaneous coronary intervention, 2) successful percutaneous coronary intervention at the site proximal to the MB augments the squeezing on the systolic vessel and 3) an electrocardiographic stress test does not assist the discrimination of chest pain causes in patients with MB.

Intravascular ultrasound studies have shown that atherosclerotic formation in the proximal segment of LAD is present in 88% of cases with MB [8]. As a possible explanation it has been postula-

ted that under these circumstances increased wall shear stress is responsible for atheroma development. Experimental and clinical studies have shown that MB is associated with increased coronary pressure in the arterial segment proximal to MB [9], which leads to an increase in wall stress. In addition, MB presence is related to a disturbed blood flow pattern, such as an increased systolic to diastolic ratio as a result of retrograde flow [8]. Klues et al. [10], using invasive Doppler assessment, showed that average peak velocity (APV) proximal to MB was significantly lower than within MB and, as mentioned above, was associated with focal retrograde flow. These two phenomena can theoretically be responsible for higher shear stress in the proximal part of LAD that is associated with atherosclerotic plaque formation. A recent study by Dirksen et al. [11] showed that flow direction may also influence shear stress. Smooth muscle cell proliferation, responsible for in-stent restenosis, mainly occurs at the downstream part of the plaque exposed to low shear stress, in contrast to the proliferation of macrophages that occurs in the upstream regions exposed to high shear stress. On the other hand, shear stress is inversely proportional to vessel size [12] and it is therefore reasonable to speculate that good results of balloon angioplasty or stent implantation obtained in the proximal part of LAD may normalise the flow pattern, the turbulent flow possibly being caused by the coexistence of MB and atherosclerotic stenosis.

Similarly, it is likely that the same blood flow disturbances may provoke restenosis development after percutaneous interventions proximally to MB. Our study did not demonstrate any relation between the occurrence of restenosis and MB, but it should be borne in mind that different pathological mechanisms are involved in atheroma and restenosis development.

A strong correlation was found between post-procedural minimal lumen diameter and the degree of MB squeezing. Hongo et al. showed that the use of nitroglycerin enhanced the squeezing of MB during coronary angiography [13]. Nitroglycerin augments basic coronary flow by increasing myocardial wall compliance. Successful coronary revascularisation improves blood flow and myocardial wall contractility, which are related to higher oxygen consumption and reversal of myocardial hibernation [14]. As a consequence, augmentation of MB squeezing of the dilated epicardial artery may appear, as was observed.

One of the most characteristic clinical features of patients with isolated MB is angina. This is ge-

Table 3. Results of the multivariable analysis of the occurrence of restenosis and angiographic parameters in Group 1

Tabela 3. Wyniki analizy wielozmiennej ujawnienia się restenozji i parametrów angiograficznych w grupie 1

	r	p
MLD pre [mm]	0.05	0.13
MLD post [mm]	0.25	0.09
Ref. D pre [mm]	0.38	0.15
Ref. D post [mm]	0.41	0.75
MBcomp post (%)	0.45	0.08

nerally not related to ischaemia [15], although non-invasive tests are positive relatively often [13, 15]. In the population studied by us 50% of the patients had a positive result from the electrocardiographic stress test at a 6-month follow-up. However, only 28% of them had angiographic signs of restenosis. Our results suggest that the electrocardiographic stress test is not the ideal method for ischaemia detection in MB patients, especially as a low specificity and sensitivity of these stress tests was reported in the control population [16].

Limitations

Firstly, the number of patients analysed is relatively small. Although this was not a randomised

study, two homogenous populations were compared. We were not able to perform angiography at follow-up in all patients, so we are not able to exclude the possibility that latent restenosis had developed in some of them. Furthermore, we did not use advanced techniques to assess coronary blood flow (intracoronary Doppler) and plaque formation (intracoronary ultrasound).

Conclusions

Our results showed that the presence of MB has no major influence on restenosis rate and that an electrocardiographic stress test has a low predictive value for the detection of restenosis.

Streszczenie

Wstęp: Mostek mięśniowy to część tętnicy wieńcowej przebiegającej pod warstwą mięśnia sercowego, które w przeważającej większości obserwujemy w obrębie gałęzi przedniej zstępującej. Celem poniższej pracy była ocena wpływu obecności mostka mięśniowego na bezpośrednie i późne wyniki przezskórnych zabiegów rewaskularyzacyjnych w porównaniu z populacją chorych, u których nie stwierdza się mostków mięśniowych.

Materiał i metody: Do populacji badanej włączono 94 pacjentów (średnia wieku $54,5 \pm 9,3$ roku), u których w koronarografii stwierdzono zmianę w proksymalnym segmencie gałęzi przedniej zstępującej. Podzielono ich na dwie grupy — grupę 1, którą stanowiło 42 chorych z mostkami mięśniowymi, oraz grupę 2 złożoną z 50 chorych bez tych mostków. U wszystkich badanych przeprowadzono ilościową analizę angiograficzną w obrębie zmiany miażdżycowej i mostków mięśniowych przed zabiegiem i po nim. Do analizy włączono minimalną średnicę naczynia, wymiar referencyjny (Ref.D) oraz stopień redukcji światła naczynia (%DS). Stopień zawężania mostków mięśniowych (MBcomp) określano jako %DS w najwęższym miejscu podczas fazy skurczowej cyklu serca. W okresie obserwacji odległej przeprowadzono ocenę kliniczną oraz kontrolne koronarografie pomiędzy 5 a 7 miesiącem.

Wyniki: Nie stwierdzono żadnych różnic w charakterystyce demograficznej, klinicznej i angiograficznej między badanymi grupami. Wyniki uzyskane z ilościowej analizy angiograficznej były zbliżone w obu grupach. Średni stopień zawężania mostków mięśniowych wzrósł z $55 \pm 21\%$ do $72 \pm 18\%$ ($p = NS$) po zabiegu. Stwierdzono istotną korelację między MBcomp a minimalną średnicą naczynia zanotowaną po zabiegu ($r = 0,79$; $p < 0,01$). W okresie obserwacji odległej nie stwierdzono istotnej różnicy w występowaniu restenozy między obiema grupami (14,2 vs. 14%; odpowiednio grupa 1 vs. grupa 2; $p = NS$), choć w obu badanych grupach stwierdzono istotne różnice w występowaniu nawrotu dolegliwości stenokardialnych i dodatnich wyników testów wysiłkowych (50% vs. 20; odpowiednio grupa 1 vs. grupa 2; $p < 0,05$).

Wnioski: Obecność mostka mięśniowego nie wpływa na występowanie restenozy po zabiegach przezskórnej angioplastyki wieńcowej. Elektrokardiograficzny test wysiłkowy ma niską wartość diagnostyczną w wykrywaniu restenozy w tej populacji chorych. (Folia Cardiologica. 2005; 12: 284–290)

mostki mięśniowe, angiografia ilościowa, testy wysiłkowe

References

1. Angelini P., Trivellato M., Donis J., Leachman R.D. Myocardial bridges: a review *Prog Cardiovasc. Dis.* 1983; 89: 75–88.
2. Edwards J.C., Burnrides C., Swarm R.L. Intracoronary Doppler in the intramural and extramural portions of coronary arteries in the human heart. *Circulation* 1956; 13: 235.
3. Grainicianu A. Anatomische studien uber die coronararterien and expermentelle untersuchugen uber ihre durchgangigkeit. *Virchow's Arch.* 1922; 238: 1.
4. Kramer J.R., Kitazume H., Proudfit W.L. Clinical significance of isolated coronary bridges: a benign and frequent condition involving the left anterior descending artery. *Am. Heart J.* 1982; 103: 282–289.
5. Taught J., Sullebaxger J.T. Myocardial infarction associated with myocardial bridging; a case history and review of the literature. *Catheter Cardiovasc. Diagn.* 1997; 40: 364–372.
6. den Dulk K., Brugada P., Braat S., Heddle B., Wellens H.J. Myocardial bridging as a cause of paroxymal atrioventricular block. *J. Am. Coll. Cardiol.* 1983; 1: 965–969.
7. Gibbons R.J., Balady G.J., Bricker J.T. et al. ACC/AHA 2002 guideline update for exercise testing: a report of the American College of Cardiology/American Heart Association Task Force on Practice Guidelines (Committee on Exercise Testing). 2002. American College of Cardiology Web site. *J. Am. Coll. Cardiol.* 2002; 40: 1531.
8. Ge J., Jeremias A., Rupp A. et al. New signs characteristic of myocardial bridging demonstrated by intracoronary ultrasound and Doppler. *Eur. Heart J.* 1999; 20: 1707–1716.
9. Ge J., Erbel R., Gorge G., Haude M., Meyer J. High wall shear stress proximal to myocardial bridging as a cause of atherosclerosis demonstrated by intracoronary ultrasound and pressure measurements. *Br. Heart J.* 1995; 73: 462–465.
10. Klues H.G., Schwarz E.R., vom Dahl J. et al. Disturbed intracoronary hemodynamics in myocardial bridging early normalization by intracoronary stent placement. *Circulation* 1997; 96: 2905–2913.
11. Dirksen M.T., van der Wal A.C., van den Berg F.M., van der Loos C.M., Becker A.E. Distribution of inflammatory cells in atherosclerotic plaques related to the direction of flow. *Circulation* 1998; 19: 2000–2003.
12. Gnasso A., Carallo C., Bace C. et al. Association between intima-media thickness and wall shear stress in common carotid arteries in healthy male subjects. *Circulation* 1996; 94: 3257–3262.
13. Hongo Y., Tada H., Ito K. Yasumura Y., Miyatake K., Yamagishi M. Augmentation of vessel squeezing at coronary myocardial bridge by nitroglycerin: study by quantitative coronary angiography and intravascular ultrasound. *Am. Heart J.* 1998; 138: 345.
14. Kloner R., Jennings R. Consequences of brief ischemia: stunning, preconditioning, and their clinical implications. *Circulation* 2001; 104: 2981–2989.
15. Gil R., Goracy J., Krzywkowski A. et al. Should myocardial bridging be treated with coronary stents? Role of the intracoronary Doppler in clinical decision making. *Eur. Heart J.* 2000; 21: 388 (abstract).
16. Borer J.S., Brensike J.F., Redwood D.R. et al. Limitations of the electrocardiographic response to exercise in predicting coronary artery disease. *New Engl. J. Med.* 1975; 193: 367–375.