

# Echocardiography findings in patients with ST segment elevation myocardial infarction and type 2 diabetes mellitus treated with primary percutaneous coronary angioplasty

Leszek Markuszewski<sup>1</sup>, Robert Pietruszyński<sup>1</sup>,  
Grzegorz Kamiński<sup>2</sup> and Włodzimierz Grabowicz<sup>1</sup>

<sup>1</sup>Department of Interventional Cardiology, Cardiometabolism and Cardiac Rehabilitation,  
1<sup>st</sup> Chair of Cardiology and Cardiosurgery, Medical University of Łódź, Poland

<sup>2</sup>Department of Endocrinology and Isotope Therapy, Military Institute of the Health Services,  
Central Clinical Hospital of the Department of National Defence, Warsaw, Poland

## Abstract

**Background:** *The development of heart failure following myocardial infarction (MI) in patients with diabetes mellitus (DM) is related to the extent of the infarction zone and underlying primary diabetic cardiomyopathy. Echocardiography allows the monitoring of systolic dysfunction following MI. Left ventricular ejection fraction (LVEF) is one of the most important prognostic indicators in patients after MI.*

**Methods:** *The aim of the study was to assess the effect of type 2 DM on postinfarct left ventricular (LV) remodeling in patients with acute ST segment elevation MI treated with primary percutaneous transluminal coronary angioplasty. One hundred and ten patients were enrolled to the study and divided into two groups: group 1 included 41 subjects with type 2 DM, and group 2 included 57 subjects without DM. Echocardiographic parameters of LV systolic function including LVEF, LV end-diastolic volume (LVEDV), and LV end-systolic volume (LVESV) were compared between the study groups.*

**Results:** *Both study groups showed statistically significant decrease in LVEF. However, significant LV dilatation was seen only in patients without DM but not in patients with DM.*

**Conclusion:** *Long-term DM leads to the remodeling and the fibrosis of cardiac interstitial tissue, limiting acute ventricular dilatation and resulting in stiffening of the heart. (Folia Cardiol. 2006; 13: 414–418)*

**Key words:** diabetes mellitus, remodeling, primary angioplasty, myocardial infarction, echocardiography, ejection fraction

---

Address for correspondence: Dr med. Włodzimierz Grabowicz  
Department of Interventional Cardiology, Cardiometabolism  
and Cardiac Rehabilitation, 1<sup>st</sup> Chair of Cardiology  
and Cardiosurgery, Medical University of Łódź  
Żeromskiego 113, 90–549 Łódź, Poland  
Tel./fax: +48 42 63 93 563,  
e-mail: cathlab@usk2wam.internetdsl.pl  
kardiolog@skwam.lodz.pl  
Received: 2.06.2005    Accepted: 26.03.2006

## Introduction

Ischemic heart disease is one of the major problems in current cardiology practice. The most dangerous form of ischemic heart disease is an acute myocardial infarction (MI), resulting from the acute occlusion of a coronary artery by a thrombus developing on an atherosclerotic plaque. Acute coronary occlusion for just 30 minutes may result in

myocardial necrosis with all its biochemical, histological, and functional sequelae. The extent of myocardial necrosis and resulting left ventricular (LV) systolic dysfunction is the major factor affecting both early and late prognosis following MI. The extent of myocardial necrosis is related to many factors including the coronary artery involved, the extent of myocardium supplied by the involved artery and the level of occlusion [1]. In addition, the heart may be “protected” against ischemia, e.g. by the presence of collateral vessels or preconditioning [2]. Remodeling following MI is a dynamic process leading to multiple changes in myocardium at the molecular and cellular level and also in the interstitial space. Remodeling is affected by the patency of the infarct-related artery, the degree of hemodynamic load, myocardial cell viability in the infarct area and neurohormonal activation [3]. Factors contributing to the adverse remodeling include anterior wall localization of MI, significant early MI expansion, persistent occlusion of the infarct-related artery, renin-angiotensin system activation, and diabetes mellitus (DM) [3, 4]. In particular, DM is associated with the accumulation of numerous additional cardiovascular risk factors and also contributes to the adverse remodeling following MI. Long-lasting DM leads to significantly increased ventricular wall stiffness, often with increased myocardial thickness [4, 5].

Primary diabetic cardiomyopathy is defined as abnormal LV myocardial function in diabetic patients with no coronary atherosclerosis, hypertension, and clinical symptoms of ischemic heart disease, eventually leading to heart failure [2, 5]. According to this definition, diabetic cardiomyopathy does not result from the effects of coronary atherosclerosis, hypertension or cardiac degenerative changes related to aging. Thus, MI superimposed on primary diabetic cardiomyopathy should lead to somewhat different remodeling following MI compared to patients without DM. Ventricular remodeling following MI involves an early and a late phase. The early phase is associated with increased end-diastolic pressure and increased wall tension due to impaired systolic function. This leads to stretching, thinning, and the separation of cardiomyocytes that is collectively termed infarct expansion [5, 6]. Chronic increase in end-diastolic cardiac load activates compensatory hemodynamic and neurohormonal mechanisms, leading to cardiomyocyte hypertrophy and interstitial fibrosis. The abnormal function of hypertrophied cardiomyocytes, manifested by their delayed contraction and relaxation, results in further increase in end-diastolic

volume and pressure, thus additionally contributing to LV dilatation. This is the so-called late phase of ventricular remodeling [7, 8].

Primary percutaneous transluminal coronary angioplasty (PTCA) is a superior therapeutic strategy in acute MI [9, 10], with significant benefits seen both during the early and long-term follow-up.

The echocardiographic assessment of LV function allows the monitoring of systolic dysfunction following MI. Left ventricular ejection fraction (LVEF) is a major indicator of cardiac function and prognosis following MI.

Events triggering and accompanying ventricular remodeling following MI in patients with DM are similar to those in patients without DM. However, underlying primary diabetic cardiomyopathy may be expected to affect the process of remodeling. The aim of this study was to assess the effect of type 2 DM on remodeling following ST segment elevation myocardial infarction (STEMI) in patients treated with primary PTCA.

## Methods

The study group consisted of 110 patients (72 men, 38 women) aged 43 to 70 years (mean age  $59.4 \pm 5.4$  years) undergoing primary PTCA in STEMI. Patients with normal LV systolic function prior to MI, defined as LVEF  $> 50\%$  as assessed using the Simpson method, were included. The patients in our study remained under the care of our center prior to the occurrence of MI and had an echocardiogram performed on an outpatient basis within 6 months before MI.

The patients were divided into two groups. Group I included 41 patients with type 2 DM and group II included 57 patients without DM. The duration of type 2 DM was  $\geq 5$  years. Characteristics of the study groups is shown in Table 1.

**Table 1.** Patient characteristics in the study groups.

	Group I	Group II	P
Men	41 (65.09%)	31 (65.96%)	NS
Women	22 (34.92%)	16 (37.21%)	NS
Age (years)	$57.2 \pm 9.8$	$60.1 \pm 7.5$	NS
LVEF prior to MI	$56.3 \pm 4.75$	$57.04 \pm 5.4$	NS
HbA <sub>1c</sub>	$6.45 \pm 0.91$	$5.1 \pm 0.73$	$< 0.05$
Peak troponin I level	$39.7 \pm 3.6$	$34.9 \pm 4.3$	NS
Anterior wall MI	30 (47.62%)	21 (44.68%)	NS

MI — myocardial infarction; LVEF — left ventricular ejection fraction

The echocardiographic assessment of cardiac function was performed in day 1 and subsequently in 3 months following MI. Evaluated parameters included LVEF, LV end-diastolic volume (LVEDV) and LV end-systolic volume (LVESV). Biplane Simpson method was used. The echocardiographic studies were performed using the Acuson Sequoia C 512 system. Only patients with the total occlusion (TIMI 0 flow) of a single major coronary artery (i.e. 1-vessel disease) before the invasive treatment and TIMI 3 flow in the infarct-related artery following the invasive treatment were included. Patients were selected based on the degree of myocardial damage as assessed by peak troponin I level. Patients with peak troponin I level of 30–50  $\mu\text{g/L}$  were included in the study.

We evaluated changes in LV systolic function parameters (LVEF, LVEDV, LVESV) at 3 months following MI compared to day 1. Both within-group and between-group comparisons were performed. Results are expressed as arithmetical means  $\pm$  standard deviation (SD). The distribution of continuous variables was evaluated using Shapiro-Wilk test. The statistical significance of the differences was evaluated using Student *t* test for parametric data and Mann-Whitney test for nonparametric data.  $P < 0.05$  was considered statistically significant.

### Results

The study groups were compared with regard to age, gender, LVEF before MI, HbA<sub>1c</sub> level, troponin level and the percentage of patients with anterior wall MI. Significant difference between the study groups was seen only in HbA<sub>1c</sub> level with elevated HbA<sub>1c</sub> values in patients with type 2 DM in group I. The results are shown in Table 1.

Significant decrease in LVEF and increase in LVESV at 3 months following MI was seen in the patients with DM (Fig. 1, 2). No change of LVEDV was seen in this group. In the patients without DM, significant decrease in LVEF and increase in both LVESV and LVEDV were seen at 3 months following MI (Fig. 3–5).

The comparison of evaluated echocardiographic parameters between the study groups at 3 months revealed significantly higher LVEDV in patients without DM compared to the patients with DM (Fig. 6). No significant difference in LVEF and LVESV between the study groups was seen at 3 months. The results are shown in Table 2.

We also compared relative changes in the evaluated echocardiographic parameters in the study groups between baseline and 3 months following MI.

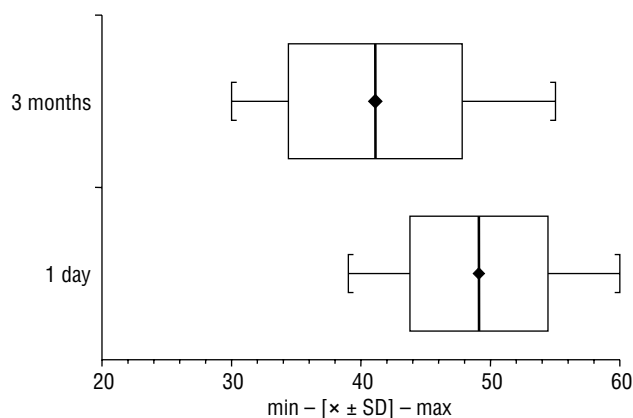


Figure 1. Comparison of left ventricular ejection fraction in Group I.

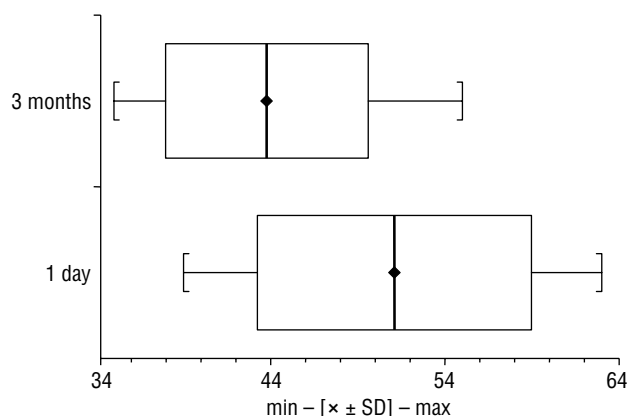


Figure 2. Comparison of left ventricular ejection fraction in Group II.

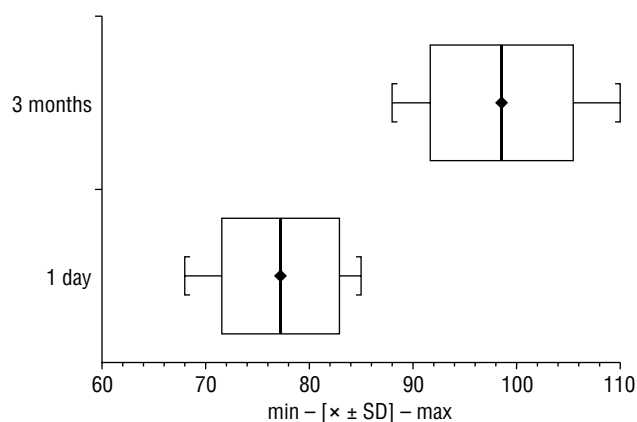
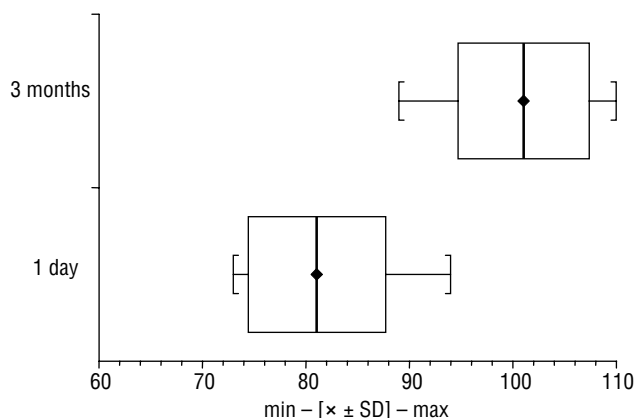
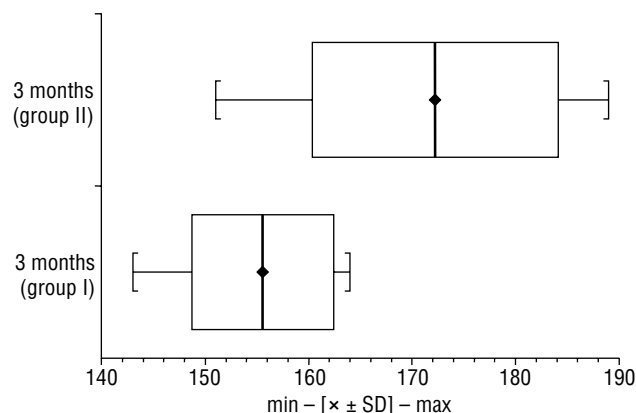


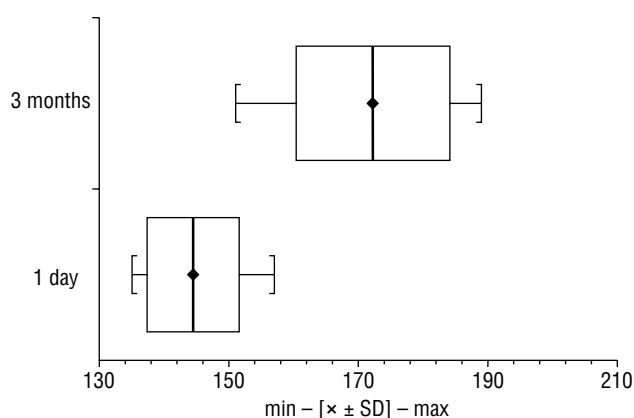
Figure 3. Comparison of left ventricular end-systolic volume in Group I.



**Figure 4.** Comparison of left ventricular end-systolic volume in Group II.



**Figure 6.** Comparison of left ventricular end-diastolic volume between the study groups at 3 months.



**Figure 5.** Comparison of left ventricular end-diastolic volume in Group II.

A statistically significant difference was seen only for the change in LVEDV, with higher increase in LVEDV in patients without DM compared to the patients with DM. No significant difference in the change in LVEF and LVESV between the study groups was seen. The results are shown in Table 3.

**Table 2.** Echocardiographic parameters of left ventricular systolic function in patients with diabetes mellitus (Group I) compared to patients without diabetes mellitus (Group II)

	Group I		Group II		Group I vs. Group II
	Day 1	3 months	Day 1	3 months	
LVEF	49.2 ± 5.35	41.1 ± 6.69*	51.1 ± 7.9	43.7 ± 5.82*	NS
LVEDV	151.0 ± 8.1	155.4 ± 6.8	144.4 ± 7.11	172.2 ± 11.8*	Significant
LVESV	77.2 ± 5.82	98.5 ± 6.91*	81.1 ± 6.63	101.1 ± 6.3*	NS

LVEF — left ventricular ejection fraction; LVEDV — left ventricular end-diastolic volume; LVESV — left ventricular end-systolic volume; \*p < 0.05

### Discussion

Impaired LV systolic function and post-infarction cardiomyopathy are adverse late sequelae of MI. Patients with DM may develop diabetic cardiomyopathy and heart failure independently from MI [11, 12]. This results from premature atherogenesis, including the development of both micro- and macroangiopathy. In addition, patients with DM are more commonly affected with hypertension, obesity and cardiac autonomic neuropathy. Biochemical

**Table 3.** Comparison of relative changes in evaluated echocardiographic parameters (difference between values at 3 months and baseline values) in patients with diabetes mellitus (Group I) and patients without diabetes mellitus (Group II)

	Group I	Group II
ΔLVEF	8.0 ± 8.4	7.3 ± 10.3
ΔLVEDV	4.6 ± 11.9	27.8 ± 13.5*
ΔLVESV	21.3 ± 8.1	20.0 ± 8.1

ΔLVEF — change in left ventricular ejection fraction; ΔLVEDV — change in left ventricular end-diastolic volume; ΔLVESV — change in left ventricular end-systolic volume; \*p < 0.05

abnormalities include nonenzymatic protein and lipid glycation, increased ATP synthesis from free fatty acids and the increased levels of toxic products of these processes. At the same time, fibroblast proliferation and collagen production are increased, leading to increased fibrosis [7, 11]. All these mechanisms impair LV diastolic function, manifested by increased isovolumic relaxation time, increased E wave deceleration time, and the reversal of the E/A ratio [13]. In summary, mechanisms leading to LV diastolic dysfunction are related to dysfunction and morphological changes in both cardiomyocytes and the extracellular matrix. In particular, abnormal calcium homeostasis and energy balance is seen in cardiomyocytes, as manifested by abnormal ADP/ATP ratio and the major pathogenic factor in the extracellular matrix is the change in fibrillar collagen. These processes lead to increased cardiac stiffness. Changes in cardiac wall stiffness may be assessed by measuring the pressure-volume relationship during the diastole [8]. Increasing cardiac wall stiffness leads to the increased end-diastolic pressure regardless of end-diastolic volume and progressively decreasing LVEF, i.e. the impairment of systolic function. The increase in ratio of end-diastolic pressure to LVEF is a measure of increasing LV wall stiffness. Long-lasting DM leads to significantly increased wall stiffness, often with increased myocardial thickness [8, 11, 12]. Infarction occurring in structurally and functionally abnormal myocardium in a patient with DM may be expected to result in a variant of ventricular remodeling [14] and the present study attempted to evaluate such differences. The evaluation of selected echocardiographic parameters of LV systolic function showed that a decrease in LVEF in patients with type 2 DM is not associated with significant LV dilatation. Increased cardiac wall stiffness in DM counteracts this ventricular remodeling, at least in the early phase following MI. A major factor affecting cardiac function impairment in patients with DM was an increase in LVESV. In contrast, decrease in LVEF with significant LV dilatation and increase in LVESV were seen in patients without DM. Similar changes in hemodynamic parameters in patients with DM developing heart failure were reported by Giles [13]. Future studies will establish whether changes in hemodynamic parameters seen at 3 months following MI in patients with DM are maintained during a longer-term follow-up.

In the present study, decrease in LVEF was found in both study groups but ventricular remodeling in patients without DM resulted in significant LV dilatation that was not seen in patients with DM.

Long-term DM leads to the remodeling and fibrosis of cardiac interstitial tissue, limiting acute ventricular dilatation and resulting in stiffening of the heart.

## References

1. McNamara RF, Carleen E, Moss AJ. Estimating left ventricular ejection fraction after myocardial infarction by various clinical parameters. *Am J Cardiol*, 1988; 62: 192–196.
2. Dauterman KW, Massie BM, Gheorghade M. Heart failure associated with preserved systolic function: a common and costly clinical entity. *Am Heart J*, 1998; 135: S-310–S-319.
3. Spector KS. Diabetic cardiomyopathy. *Clin Cardiol*, 1998; 21: 885–887.
4. Sutton MG, Sharpe N. Left ventricular remodeling after myocardial infarction. *Pathophysiology and therapy. Circulation*, 2000; 101: 2981–2988.
5. Piątkowski R, Filipiak K, Opolski G. Zapobieganie remodelingowi lewej komory po zawale serca. *Terapia* Nr 9, 2001.
6. Drożdżiak E, Piwowarska W. Przebudowa lewej komory po zawale serca. *Pol Merk Lek*, 1996; 4: 219–222.
7. Filipiak KJ, Opolski G. Lek hamujące układ renina-angiotensyna-aldosteron. *Urban & Partner, Wrocław* 2000: 143–60.
8. Dahalla NS, Liu X, Panagia V. Subcellular remodeling and heart dysfunction in chronic diabetes. *Cardiovasc Res*, 1998; 40: 239–247.
9. Grines CL. Coronary angioplasty with or without stent implantation for acute myocardial infarction. *N Eng J Med*, 1999; 341: 1949–1956.
10. Berger AK. Primary coronary angioplasty vs. thrombolysis for the management of acute myocardial infarction in elderly patients. *JAMA*, 1999; 282: 341–348.
11. Haffner SM. Mortality from coronary heart disease In subjects with type 2 diabetes and In non-diabetic subjects with and without priori myocardial infarction. *NEJM*, 1998; 39: 229–234.
12. Ziloe MR, Brutseart DL. New concepts in diastolic dysfunction and diastolic heart failure: Diagnosis, prognosis, and measurements of diastolic function. *Circulation*, 2002; 105: 1387–1393.
13. Giles TD. The patient with diabetes mellitus and heart failure: at risk issues. *Am J Med*, 2003; 8A (Suppl): S-107–S-110.
14. Northammar A, Malmberg K, Diderholm E. Diabetes mellitus: the major risk factor in unstable coronary artery disease even consideration of the extent of coronary artery disease and benefits of revascularization. *J Am Coll Cardiol*, 2004, 43: 585–591.