

# Assessment of right ventricular function by tissue Doppler in relation to plasma NT-proBNP concentration in patients with dilated cardiomyopathy

Witold Streb<sup>1</sup>, Jolanta Nowak<sup>2</sup>, Anna Śliwińska<sup>1</sup>, Beata Spinczyk<sup>2</sup>, Mariola Szulik<sup>1</sup>, Agata Duszańska<sup>1</sup>, Ewa Uszok-Stenzel<sup>2</sup>, Mariusz Kalinowski<sup>1</sup>, Zbigniew Kalarus<sup>1</sup>, Lech Poloński<sup>2</sup> and Tomasz Kukulski<sup>1</sup>

<sup>1</sup>st Department of Cardiology, Medical University of Silesia, Zabrze, Poland

<sup>2</sup>3<sup>th</sup> Department of Cardiology, Medical University of Silesia, Zabrze, Poland

## Abstract

**Background:** *Impairment of right ventricular function is a common finding in patients with dilated cardiomyopathy (DCM). The aim of the study was to assess the function of the right ventricle by tissue Doppler imaging (TDI) in relation to NT-proBNP concentration in patients with DCM.*

**Methods:** *29 patients with DCM were studied. Group I (n = 21) constituted of subjects with a NT-proBNP concentration > 500 pg/ml and group II (n = 8) constituted of patients with NT-proBNP < 500 pg/ml. In all patients the TDI parameters for the free-wall of the right ventricle were analysed: velocity of myocardium (VEL), strain ( $\epsilon$ ) and strain rate (SR).*

**Results:** *There were no significant differences between the two groups with respect to clinical characteristics, parameters of global and regional left ventricular systolic function or between indicators of global right ventricular function. In group I the maximal values of  $\epsilon$  in the apical and medial segments of the right ventricular free wall were significantly lower than in group II ( $-17 \pm 10$  vs.  $-29 \pm 7\%$ ;  $p = 0.0168$  and  $-13 \pm 6$  vs.  $-25 \pm 5\%$ ;  $p = 0.0023$  respectively). Moreover, in group I the maximal SR in the apical and medial segments of the right ventricular free wall were significantly lower than in group II ( $1.56 \pm 0.6$  s<sup>-1</sup> vs.  $-1.071 \pm 0.5$  s<sup>-1</sup>;  $p = 0.0358$  and  $-0.99 \pm 0.38$  s<sup>-1</sup> vs.  $-1.55 \pm 0.37$  s<sup>-1</sup>;  $p = 0.0044$  respectively).*

**Conclusions:** *Impairment of right ventricular function is most visible in the apical and medial segments. The maximal values of  $\epsilon$  and SR for the right ventricle free wall are lower in patients with DCM and NT-proBNP > 500 pg/ml. (Cardiol J 2007; 14: 167–173)*

**Key words:** dilated cardiomyopathy, ventricular function, Doppler echocardiography, NT-proBNP

Address for correspondence: Dr med. Witold Streb  
1<sup>st</sup> Department of Cardiology  
Medical University of Silesia  
Szpitalna 2, 41–800 Zabrze, Poland  
Tel: +48 32 271 34 14, fax: +48 32 271 92 76  
e-mail: [streb@wp.pl](mailto:streb@wp.pl)  
Received: 20.08.2006 Accepted: 27.01.2006

## Introduction

Disturbances in the systolic as well as the diastolic left ventricular function in patients suffering from dilated cardiomyopathy (DCM) are well documented and correlate with clinical symptoms of heart failure. Moreover, it is postulated by some authors that they are independent predictors of survival in patients with DCM [1, 2]. It is also well known that during the progression of DCM it is not only the function of the left ventricle (LV) but also that of the right ventricle (RV) that is impaired. This may be a result of LV dysfunction, alternations of interventricular interdependence or of the RV myocardium being primarily affected by the disease [3]. Assessment of RV function in patients with dilated cardiomyopathy is important because there is evidence of a relation between the function of the RV and exercise capacity. It is also apparent that RV function influences the prognosis of patients with DCM [4, 5]. However, the possibilities of RV function evaluation by commonly used imaging modalities are limited.

The introduction of new imaging techniques such as tissue Doppler imaging (TDI) into clinical practice allows the regional function of the RV myocardium to be assessed objectively and quantitatively [6, 7]. However, the usefulness of TDI in the examination of the RV in patients with DCM has not been documented.

Measurement of the N-terminal fragment of brain natriuretic peptide (NT-proBNP) serum concentration in patients with heart failure is nowadays a clinical standard in the evaluation of the progression of the disease. Some authors have reported that this peptide is also an indicator of impaired RV in patients with LV heart failure [8]. Therefore it is essential to evaluate the relationship between NT-proBNP concentration and the parameters of RV function.

The aim of the study was to evaluate RV function by TDI in comparison with serum NT-proBNP concentration in patients with DCM.

## Methods

### Study group

A total of 29 consecutive patients with diagnosed DCM were enrolled to the study. The diagnosis of DCM was made on the basis of World Health Organisation criteria. In all cases the presence of significant change in the epicardial arteries was excluded by angiography. All the patients received optimal pharmacological treatment, including ACE inhibitors, beta blockers, diuretics and, where justified, digitalis glycosides. The NT-proBNP concentration in each patient was estimated using ElectroChemiLuminescence ImmunoAssay (the ECLIA method). Depending on the NT-proBNP concentration the patients were assigned to one of the following two groups:

- group I (21 patients) — those with NT-proBNP concentration > 500 pg/ml;
- group II (8 patients) — those with NT-proBNP concentration < 500 pg/ml.

The characteristics of each group are shown in the Table 1.

### Echocardiographic examination

An echocardiographic examination in standard views, including M-mode and two-dimensional presentations, was performed in all patients. Tissue Doppler imaging data were also recorded in these patients. All examinations were performed by one experienced echocardiographer on a VIVID 5 (General Electric) machine equipped with a 2.5 MHz transducer.

The dimensions of the LV and RV were measured according to recommendations of the American Society of Echocardiography. Left ventricular ejection fraction (LVEF) was calculated on the basis of the Simpson formula in the apical four-chamber view. Similarly the end-diastolic volume, end-systolic volume and EF for the RV were calculated in the same view, as well as fractional area change (FAC), which by definition is a ratio of the

**Table 1.** Characteristics of the study groups.

|                                 | Group I (n = 21) | Group II (n = 8) | Significance level p |
|---------------------------------|------------------|------------------|----------------------|
| Age [years]                     | 46.47 ± 13.25    | 48.37 ± 10.83    | NS                   |
| NYHA I                          | 1 (4.78%)        | 2 (25%)          | NS                   |
| NYHA II                         | 16 (76%)         | 6 (75%)          | NS                   |
| NYHA III                        | 4 (19.22%)       | 0 (0%)           | NS                   |
| NT-proBNP concentration [pg/ml] | 2372 ± 1723      | 240 ± 1 77       | 0.0018               |
| QRS duration [ms]               | 145 ± 39         | 146 ± 26         | NS                   |

**Table 2.** Assessment of left ventricle.

|  | Group I (n = 21) | Group II (n = 8) | Significance level p |
|--|------------------|------------------|----------------------|
| Left ventricular diastolic dimension [mm]  | 72.14 ± 5.06     | 69 ± 8.66        | NS                   |
| Left ventricular systolic dimension [mm]   | 58.95 ± 5.32     | 54.37 ± 9.84     | NS                   |
| Left ventricular ejection fraction [%]     | 27.76 ± 5.89     | 31.25 ± 8.66     | NS                   |
| Left ventricular end-diastolic volume [ml] | 253.85 ± 46.42   | 248.62 ± 79.63   | NS                   |
| Left ventricular end-systolic volume [ml]  | 183.71 ± 37.83   | 170.75 ± 66.64   | NS                   |

difference of end-diastolic and systolic RV area to end-diastolic area M-mode presentation was also used for the assessment of tricuspid annulus plane systolic excursion (TAPSE) by the placement of the M-mode line perpendicularly to the plane of the tricuspid valve in the four-chamber view [9].

Tissue Doppler images were recorded for the RV free wall in the apical four-chamber view, with special attention given to obtaining the narrowest angle between the ultrasound beam and the long axis of the RV free wall. All the images in TDI mode were recorded during a short period of apnoea during three consecutive ECG cycles, with pulse repetition frequency exceeding 120 frames per second. The data were digitally recorded and then analysed with SPEQLE software (Software Package for Echocardiographic Quantification, Leuven, Belgium).

### Tissue Doppler imaging analysis

Tissue Doppler imaging data were analysed for basal segment (the inflow part of the RV) and for the medial and apical segments, which reflect the outflow part of the RV free wall in the long axis. The localisation of a sample volume within the free RV wall was based upon tissue tracking in a two-dimensional presentation. The intervals of the cardiac cycle were established on the basis of detection of aortic valve closure, reflecting the end of the ejection period of the LV, and on detection of mitral valve opening, the beginning of LV filling. During the ejection period the maximal velocity (VEL), maximal strain ( $\epsilon$ ) and maximal strain rate (SR) of the RV free wall were assessed. Strain was defined as the difference between the final and initial lengths in relation to the initial length expressed as a percentage, whereas the SR reflects the regional gradient of myocardial velocity, and its measure unit is  $s^{-1}$  [10].

### Statistical analysis

Statistica 6 software (StatSoft, Tulsa, USA) was used for statistical analysis. To compare the two

groups the non-parametric Mann-Whitney test was used. The significance level was taken as  $p < 0.05$ . All the values were presented as the arithmetic mean values and standard deviations.

## Results

The two groups did not differ significantly either with regard to age ( $46.7 \pm 13$  vs.  $48.37 \pm 10$  years) or NYHA class (Table 1). No differences were found either with respect to the duration of QRS complexes ( $145 \pm 39$  vs.  $146 \pm 26$  ms). The mean NT-proBNP serum concentration in group I was  $2372 \pm 1723$  pg/ml and in group II  $240 \pm 177$  pg/ml.

The study did not show any significant differences between the parameters of global LV function such as end-diastolic volume, end-systolic volume, LVEF and the end-diastolic and systolic LV dimensions measured in the parasternal long axis (Table 2). With respect to the LV, no differences were found regarding the regional function (VEL,  $\epsilon$ , SR) analysed for the interventricular septum and for the anterior wall in the four-chamber view (longitudinal shortening) and for the posterior wall in the short axis (radial shortening). The results of regional systolic function assessment of the LV are shown in Table 3.

The study revealed that the parameters of global RV function (FAC, TAPSE, RVEF) were decreased in both groups compared to the reference values for normal subjects. Moreover, in group I the values of FAC were lower than in group II ( $26 \pm 11\%$  vs.  $30 \pm 10\%$ ), as were the TAPSE ( $1.6 \pm 0.4$  cm vs.  $1.7 \pm 0.4$  cm) and the RVEF ( $34 \pm 16.5\%$  vs.  $43 \pm 13\%$ ), although these differences were not statistically significant (Table 4).

In group I the maximal strain of free RV wall during systole was significantly lower than that of group II in the apical segment ( $-17 \pm 10\%$  vs.  $-29 \pm 7\%$ ;  $p = 0.0168$ ) and the same applied to the medial segment ( $-13 \pm 6\%$  vs.  $-24.6 \pm 5\%$ ;  $p = 0.023$ ),

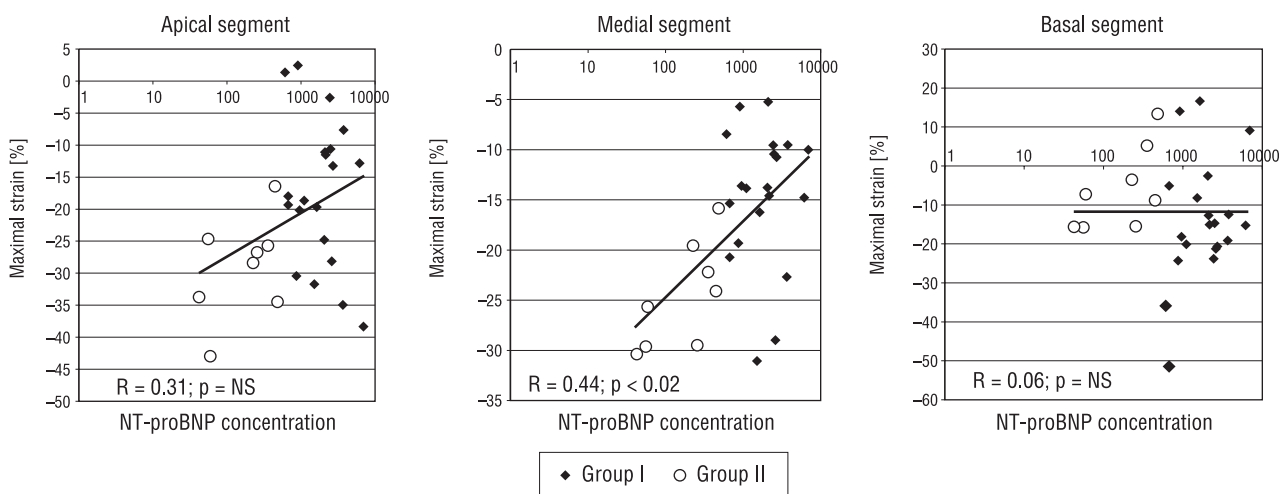
**Table 3.** Assessment of regional left ventricular function.

|                                 | Group I                     |            |                           | Group II                    |            |                           |
|---------------------------------|-----------------------------|------------|---------------------------|-----------------------------|------------|---------------------------|
|                                 | VEL max [ms <sup>-1</sup> ] | ε max [%]  | SR max [s <sup>-1</sup> ] | VEL max [ms <sup>-1</sup> ] | ε max [%]  | SR max [s <sup>-1</sup> ] |
| <b>Anterior wall</b>            |                             |            |                           |                             |            |                           |
| Apical segment                  | 0.0085 ± 0.02               | -5.22 ± 7  | -0.4662 ± 0.66            | 0.0047 ± 0.02               | -9.00 ± 8  | -1.0061 ± 1.19            |
| Medial segment                  | 0.0127 ± 0.31               | -2.45 ± 7  | -0.4451 ± 0.53            | 0.0060 ± 0.02               | -6.15 ± 4  | -0.1188 ± 0.83            |
| Basal segment                   | 0.0151 ± 0.02               | -1.50 ± 7  | -0.6980 ± 0.07            | 0.0179 ± 0.02               | -0.97 ± 4  | -0.8139 ± 0.44            |
| <b>Interventricular septum</b>  |                             |            |                           |                             |            |                           |
| Apical segment                  | 0.0225 ± 0.02               | -4.5 ± 9   | -0.5137 ± 0.65            | 0.0213 ± 0.01               | -7.6 ± 9   | -0.68 ± 0.60              |
| Medial segment                  | 0.025 ± 0.018               | -5.68 ± 6  | -0.715 ± 0.518            | 0.0260 ± 0.015              | -6.83 ± 6  | -0.7240 ± 0.23            |
| Basal segment                   | 0.0271 ± 0.02               | -2.28 ± 12 | -0.6885 ± 0.31            | 0.0263 ± 0.02               | -2.8 ± 1   | -0.4327 ± 0.36            |
| <b>Short axis</b>               |                             |            |                           |                             |            |                           |
| Basal segment of posterior wall | 0.0212 ± 0.008              | 11.13 ± 14 | 0.8534 ± 0.86             | 0.0306 ± 0.009              | 10.24 ± 15 | 1.05 ± 0.77               |

**Table 4.** Global right ventricular function assessment.

|   | Group I    | Group II   | Significance level p |
|---|------------|------------|----------------------|
| RV dimension in parasternal view [mm]           | 30.4 ± 4.3 | 30.5 ± 4.3 | NS                   |
| RV area in diastole [cm <sup>2</sup> ]          | 24.2 ± 6   | 23.5 ± 4.2 | NS                   |
| RV area in systole [cm <sup>2</sup> ]           | 18 ± 5.8   | 16.1 ± 2.4 | NS                   |
| Fractional area change of RV [%]                | 26 ± 11    | 30 ± 10    | NS                   |
| Diastolic RV volume [ml]                        | 56.3 ± 20  | 55 ± 14    | NS                   |
| Systolic RV volume [ml]                         | 37.5 ± 18  | 30.9 ± 8.3 | NS                   |
| RV ejection fraction [%]                        | 34 ± 16.5  | 43 ± 13    | NS                   |
| Tricuspid annular plane systolic excursion [cm] | 1.6 ± 0.4  | 1.7 ± 0.4  | NS                   |

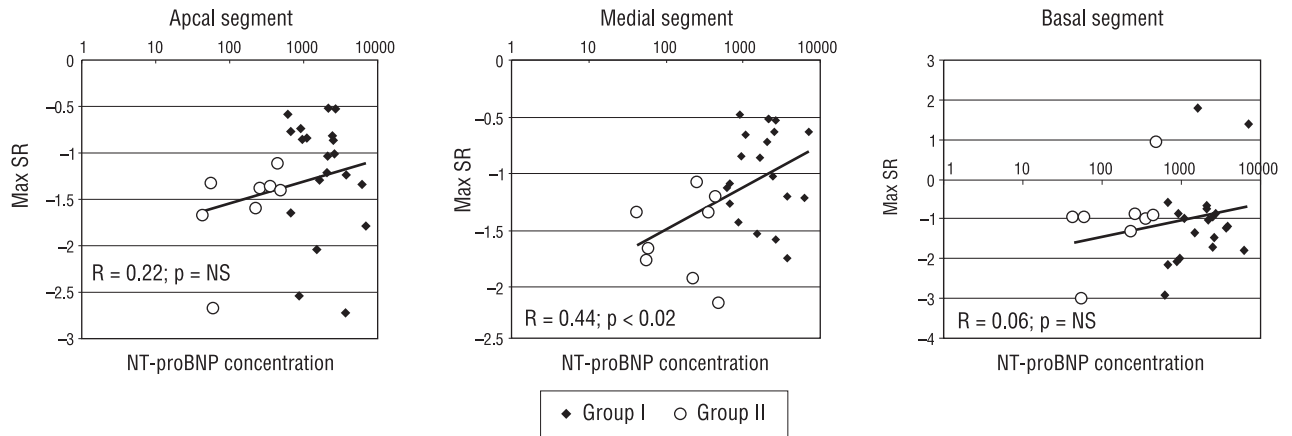
RV — right ventricle



**Figure 1.** Maximal strain (ε) during systole for apical, medial and basal segments of the right ventricle free wall.

whereas no such differences in maximal ε were found for the basal segments (group I  $-0.14 \pm 0.1$  vs.  $-0.06 \pm 0.1$ ; NS). Figure 1 shows the results for

maximal ε measured for respective segments and the trends of correlation between maximal ε and NT-proBNP concentration for the RV.



**Figure 2.** Maximal strain rate (SR) during systole for apical, medial and basal segments of the right ventricle free wall.

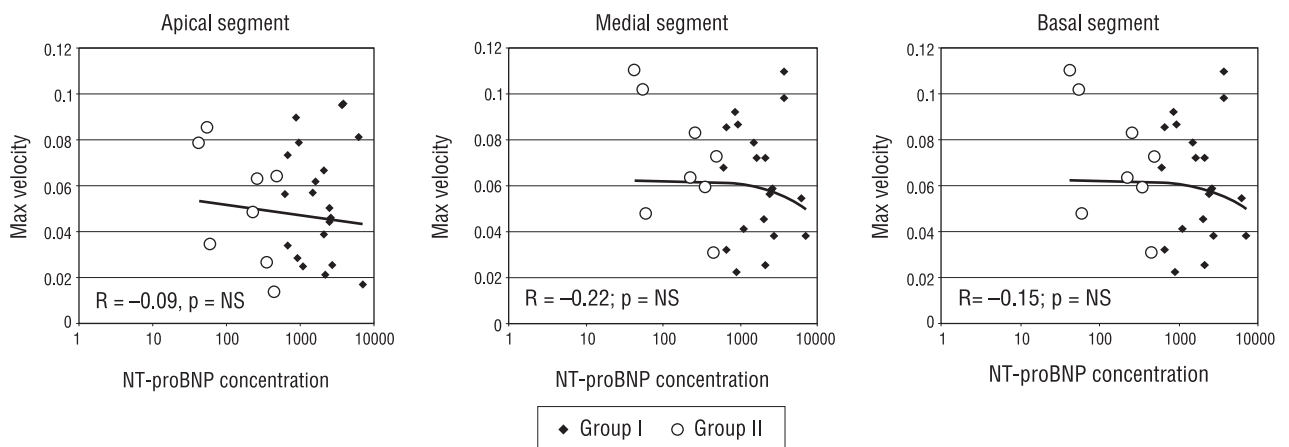
The maximal SR values measured in the apical segment were also higher in group II than in group I and were respectively:  $-1.56 \pm 0.6$  and  $-1.071 \pm 0.5 \text{ s}^{-1}$ ;  $p = 0.0358$ . Significant differences were also detected for values of maximal SR in the medial segments of RV ( $-0.989 \pm 0.38 \text{ s}^{-1}$  in group I and  $-1.551 \pm 0.37 \text{ s}^{-1}$  in group II;  $p = 0.0044$ ). However, no such alternations were found with respect to maximal SR in the basal segments of the RV ( $-1.073 \pm 1.06$  vs.  $-0.966 \pm 1.05 \text{ s}^{-1}$ ; NS). Figure 2 illustrates the differences in maximal SR in particular segments of the RV free wall of the two groups and the relationship of maximal SR and NT-proBNP serum concentration.

The analysis performed did not reveal any statistically significant differences between the two groups regarding the maximal velocity of the myocardium during systole in the apical, medial and basal segments

of the RV free wall. The mean maximal VEL in the apical segment was  $0.049 \pm 0.03 \text{ m/s}$  in group I and  $0.052 \pm 0.03 \text{ m/s}$  in group II, while in the medial segment it was  $0.063 \pm 0.02 \text{ m/s}$  and  $0.071 \pm 0.02 \text{ m/s}$  respectively and in the basal segment  $0.075 \pm 0.03$  and  $0.082 \pm 0.02 \text{ m/s}$ . The results of maximal velocity assessment for the RV free wall are given in the Figure 3.

### Discussion

Only isolated studies have so far documented the fact that impairment of RV function is frequent in patients with congestive heart failure. Polak et al. [11] showed that patients with RVEF of less than 35% at rest had a significantly higher mortality during two-year observation. Di Salvo et al. [12] revealed that RV function had a stronger influence on the prognosis in patients with advanced heart failure



**Figure 3.** Maximal systolic velocity of the myocardium for apical, medial and basal segments of the right ventricle free wall.

than maximal oxygen consumption during the exercise stress test. Assessment of RV function is therefore indisputably useful in the establishment of a prognosis in the group of patients with DCM.

However, no single imaging technique is optimal in the evaluation of RV function. There have been attempts to examine RV function by means of thermodilution, ventriculography, magnetic resonance imaging, scintigraphy and echocardiography. Each of these methods has some advantages and disadvantages. Since echocardiography is a widely available and non-invasive imaging technique, it is the most commonly used modality in the assessment of RV function. In patients with congestive heart failure the following echocardiographic parameters of RV function have been analysed: RV volume, RVEF, RV fractional area change during diastole and systole, tricuspid annular plane systolic excursion and RV long axis shortening [13, 14]. However, it was the introduction of the tissue Doppler imaging modality which first allowed regional RV function to be quantitatively evaluated [15].

In contrast to the conventional Doppler echocardiographic study, the Doppler signals recorded for the myocardium are characterised by relatively low velocities and high amplitudes. Modern echocardiographic scanners make it possible to record simultaneously the images in two-dimensional presentation as well as TDI mode with a temporal resolution of about 10 ms, which is enough to identify and analyse most of the events in the cardiac cycle [16]. It has also been shown that the strain rate correlates with myocardial contractility. The values of regional velocity, strain and strain rate in healthy subjects for RV free wall were described by Kowalski et al. [10].

In the study conducted by us the maximal velocities of the RV myocardium during systole were lower in both groups compared to the normal values accessible in the literature. The velocity gradient along the long axis of the RV free wall from the base to the apex reflected that described in healthy subjects. The recorded velocities did not differ significantly between groups I and II. The measurement of velocities showed the impairment of RV mechanical function in patients suffering from DCM, whereas no relationship was found between the myocardial velocity of the RV free wall and RV overload as expressed by N-proBNP serum concentration.

In contrast to the velocities, the strain and strain rate reflect deformation of the myocardium rather than its motion. The superiority of these

parameters in the assessment of myocardial function results from the fact that they measure the deformation on its own instead of its translation along the transducer, and this has already been demonstrated by some authors [17, 18].

The study conducted by us showed that in the patients with DCM maximal  $\epsilon$  during systole was decreased for all segments of the LV and RV compared with values in a healthy population. The two groups analysed differ significantly from each other with respect to the mean values of  $\epsilon$  for the medial and apical segments. In group II the values were slightly lower than the reference values, whereas in group I the  $\epsilon$  values were significantly decreased.

Similar changes were observed for values of SR. In both groups analysed the SR was lower for all segments of the RV free wall than in the healthy population, but the SR was significantly decreased in the medial and apical segments of the RV free wall in group I.

On the basis of the observations made during this study, it may be concluded that the alternations in SR values are secondary to the increased vascular resistance in the pulmonary circulation which accompanies LV failure, because the most remarkable changes in the TDI parameters were observed in the segments of the RV constituting the right ventricular outflow tract.

The study demonstrates that echocardiography incorporating the TDI method is useful in the analysis of the RV in patients with heart failure due to DCM. The study groups did not differ significantly with regard to clinical characteristics, global and regional LV function or global RV function. However, only the TDI parameters revealed the significantly lower values for the medial and apical segments of the RV in patients with a higher NT-proBNP serum concentration.

### Study limitations

Strain and strain rate were calculated on the basis of the Doppler velocity vector recorded along the ultrasound beam. It is known that the differences in angle of ultrasound beam can result in values of velocity, strain and strain rate different from those derived from newer techniques based on SPEQLE tracking.

The study did not allow the predictive value of the deformation parameters in patients with DCM to be established, since no follow-up data were gathered.

The small number of individuals, especially in group II, may have influenced the statistical interpretation of the results obtained.

## Conclusions

1. In patients with left ventricular heart failure the impairment of right ventricular deformation parameters (strain and strain rate) have a stronger relationship with NT-proBNP than the indices of regional function of the left ventricle.
2. Disturbances in right ventricular function are predominantly present in the medial and apical segments.
3. Tissue Doppler imaging can be a useful modality in the assessment of deterioration of right ventricular function in patients with dilated cardiomyopathy. Moreover either  $\epsilon$  or SR is superior to myocardial velocity.

## References

1. Xie G, Berk M, Smith M, Gurley J, DeMaria A. Prognostic value of Doppler transmitral flow patterns in patients with congestive heart failure. *J Am Coll Cardiol*, 1994; 24: 132–139.
2. Rihal C, Nishimura R, Hatle L, Bailey K, Tajik A. Systolic and diastolic dysfunction in patients with clinical diagnosis of dilated cardiomyopathy: relation to symptoms and prognosis. *Circulation*, 1994; 90: 2772–2779.
3. Guarracino F, Cariello C, Danella A et al. Right ventricular failure: physiology and assessment. *Minerva Anestesiol*, 2005; 71:307–312.
4. Baker B, Wilen M, Boyd C, Dinh H, Franciosa J. Relation of right ventricular ejection fraction to exercise capacity in chronic left ventricular failure. *Am J Cardiol*, 1984; 54: 596–599.
5. Di Salvo T, Mathier M, Semigran M, Dec W. Preserved right ventricular ejection fraction predicts exercise capacity and survival in advanced heart failure. *J Am Coll Cardiol*, 1995; 25: 1143–1153.
6. Kukulski T, Hubbert L, Arnold M, Wranne B, Hatle L, Sutherland G. Normal regional right ventricular function and its change with age: a Doppler myocardial imaging study. *J Am Soc Echocardiogr*, 2000; 13: 194–204.
7. Lopez-Candales A, Dohi K, Bazaz R, Edelman K. Relation of right ventricular free wall mechanical delay to right ventricular dysfunction as determined by tissue Doppler imaging. *Am J Cardiol*, 2005; 96: 602–606.
8. Mariano-Goulart D, Eberlé M, Boudousq V et al. Major increase in brain natriuretic peptide indicates right ventricular systolic dysfunction in patients with heart failure 2003. *Eur J Heart Fail*, 2003; 5: 481–488.
9. Kurzyna M, Torbicki A, Pruszczyk P. Ocena prawej komory. In: Hoffman P, Kasprzak J eds. *Echokardiografia*. Via Medica, Gdańsk 2005: 52–58.
10. Kowalski M, Kukulski T, Jamal F et al. Can natural strain and strain rate quantify regional myocardial deformation? A study in healthy subjects. *Ultras Med Biol*, 2001; 27: 1087–1097.
11. Polak J, Holman L, Wynne J, Colucci W. Right ventricular ejection fraction: an indicator of increased mortality in patients with congestive heart failure associated with coronary artery disease, *J Am Coll Cardiol*, 1983; 2: 217–224.
12. Di Salvo T, Mathier M, Semigran M, Dec W. Preserved right ventricular ejection fraction predicts exercise capacity and survival in advanced heart failure. *J Am Coll Cardiol*, 1995; 25: 1143–1153.
13. La Vecchia L, Zanolla L, Karoto L et al. Reduced right ventricular ejection fraction as a marker for idiopathic dilated cardiomyopathy compared with ischemic left ventricular dysfunction. *Am Heart J*, 2001; 142: 181–189.
14. Karatasakis G, Karagounis L, Kalyvas P et al. Prognostic significance of echocardiographically estimated right ventricular shortening in advanced heart failure. *Am J Cardiol*, 1998; 82: 329–334.
15. Kowalski M, Kukulski T, Ionescu A. The right ventricle. W: Sutherland G, Hatle L, Rademakers F, Claus P, D'Hooge J, Bijnens B eds. *Doppler myocardial imaging*. Leuven University Press. Leuven 2003.
16. Hatle L, Sutherland G. Regional myocardial function — a new approach. *Eur Heart J*, 2000; 21: 1337–1357.
17. Abraham T, Laskowski C, Zhan W et al. Myocardial contractility by strain echocardiography: comparison with physiological measurements in an in vitro model. *Am J Physiol Heart Circ Physiol*, 2003; 285: H2599–H2604.
18. Pislaru C, Abraham T, Belohlavek M. Strain and strain rate echocardiography. *Curr Opin Cardiol*, 2002; 17: 443–454.