

# New monitoring techniques to diagnose the cause of syncope

Suneet Mittal

Arrhythmia Institute of the Valley Hospital Health System, Ridgewood,  
NJ and New York, NY, United States

## Abstract

*Syncope is a very common clinical problem. Given the extensive differential diagnosis, we have developed a structured approach for the evaluation and management of patients with unexplained syncope. Patients with overt cardiac, neurologic, or metabolic disturbances are identified and treated accordingly. However, the remaining patients with high-risk characteristics are hospitalized for risk stratification. After excluding patients who can benefit from pacemaker or implantable cardioverter-defibrillator implantation, an implantable loop recorder (ILR) appears to be a very effective diagnostic tool. The recent availability of a small ILR that can be implanted within minutes and provides daily data wirelessly for over 3 years appears to have elevated the ILR over short-term external electrocardiography (ECG) monitoring techniques in patients with unexplained syncope. Herein, using specific case examples, we review how we use a structural pathway at our institution to guide the evaluation and management of patients presenting with unexplained syncope, identify the types of patients who benefit from long-term ECG monitoring, and show how this strategy has positively affected clinical care in these patients. (Cardiol J 2014; 21, 6: 625–630)*

**Key words:** monitoring, syncope

## Introduction

Syncope (derived from the Greek term *syn-coptein* [“to cut short”]) is a very common clinical problem with an overall incidence of a first report of syncope being 6.2 per 1,000 person-years [1]. The incidence rate increases with age, especially after age 70; the estimated 10-year cumulative incidence of syncope is 6% and up to 22% of patients experience recurrent syncope [1]. The differential diagnosis of syncope is extensive [2]. Thus, a structured approach is needed for the evaluation and management of patients with unexplained syncope.

### Case vignette no. 1

A 62-year-old male with hypertension (well controlled with valsartan 160 mg daily) presented

to our emergency department following a syncopal episode. The patient was well, on his way from his bedroom to the kitchen, when he suffered his first-ever episode of syncope. There was no prodrome. The patient remembered heading to the kitchen; the next thing that he remembered was walking up on the floor in a pool of blood. In the emergency room, the patient was alert and oriented. The blood pressure was 130/80 mm Hg and the heart rate was 64 bpm and regular. There was no orthostasis. The physical examination was remarkable only for a small laceration across his forehead. His electrocardiogram (ECG) showed sinus rhythm at 68 bpm; there was underlying left bundle branch block (LBBB). Routine blood tests were within normal limits. Does this patient require hospitalization for further evaluation?

**Address for correspondence:** Suneet Mittal, MD, Director, Electrophysiology Laboratory, The Valley Hospital, 223 N. Van Dien Avenue, Ridgewood, NJ 07450, USA, tel: 201-432-7837, fax: 201-432-7830, e-mail: mittsu@valleyhealth.com  
Received: 18.09.2014 Accepted: 09.10.2014



**Table 1.** Features suggesting arrhythmic syncope. Adapted from [4].

Syncope during exertion or while supine
Palpitations at the time of syncope
Family history of sudden cardiac death
Non-sustained ventricular tachycardia
Bifascicular block (LBBB or RBBB combined with left anterior or left posterior fascicular block) or other intraventricular conduction abnormalities with QRS duration $\geq 120$ ms
Severe sinus bradycardia
Manifest pre-excitation
Short or long QT interval
RBBB pattern with coved ST-elevation in leads V1–V2 (Brugada pattern)
Negative T waves in right precordial leads and epsilon waves (ARVC)

ARVC — arrhythmogenic right ventricular cardiomyopathy; LBBB — left bundle branch block; RBBB — right bundle branch block

We also hospitalize patients with an OESIL score  $\geq 2$  since these patients have a high 1-year mortality. Our patient, who had underlying LBBB, was hospitalized for further evaluation.

Patients in whom a decision is made to pursue hospitalization undergo at least 24-h of continuous ECG (telemetry or Holter) monitoring as well as baseline echocardiography. The latter identifies patients who may benefit from implantable cardioverter-defibrillator (ICD) implantation on the basis of underlying structural heart disease (e.g., hypertrophic cardiomyopathy, arrhythmogenic right ventricular cardiomyopathy, left ventricular dysfunction) or require an intervention to relieve an “obstruction to flow” (e.g., critical aortic stenosis, aortic dissection, severe pulmonary hypertension, acute pulmonary embolism, left atrial myxoma, pericardial tamponade). In the remaining patients, the implantable loop recorder (ILR) is the most promising monitoring tool for helping make an ultimate diagnosis in patients presenting with unexplained syncope. The currently accepted criteria for ILR implantation are summarized in Table 2.

In patients with recurrent unexplained syncope, guidelines now advocate the “early” use of ILRs since recurrent syncope occurs sporadically and because ECG documentation at time of recurrent syncope is an extremely important diagnostic modality [5]. The diagnostic yield of any ECG monitoring strategy increases as the monitoring period is increased; ILRs have a significantly greater diagnostic yield than 24-h Holter, 30-day

**Table 2.** Indications for an implantable loop recorder (ILR) in patients with unexplained syncope. Adapted from [5].**Class I.** ILR is indicated:

- In an early phase of evaluation of patients with recurrent syncope of uncertain origin who have (level of evidence: A):
  - absence of high-risk criteria that require immediate hospitalization or intensive evaluation, and
  - a likely recurrence within battery longevity of the device
- In high-risk patients in whom a comprehensive evaluation did not demonstrate a cause of syncope or lead to specific treatment (level of evidence: B)

**Class IIA.** ILR may be indicated:

- To assess the contribution of bradycardia before embarking on cardiac pacing in patients with suspected or certain neurally-mediated syncope presenting with frequent or traumatic syncopal episodes (level of evidence: B)

**Class IIB.** ILR may be indicated:

- In patients with transient loss of consciousness of uncertain syncopal origin in order to definitely exclude an arrhythmic mechanism (level of evidence: C)

event, or 30-day ambulatory cardiovascular telemetry monitoring [6]. The PICTURE registry was a prospective, multicenter, observational study that followed 570 patients with recurrent unexplained pre-syncope or syncope who received an ILR [7]. It was shown that these patients were evaluated on average by 3 different specialists and underwent a median of 13 non-diagnostic tests (range 9–20). Within the first year, syncope recurred in a third of the patients; the ILR provided a diagnosis in 78% of the patients, most commonly a cardiac etiology.

In some patients, an ILR may be appropriate following a first episode of syncope. An example is a patient (like ours) with unexplained syncope whose ECG shows bifascicular AV block (i.e., right bundle branch with an associated hemiblock or LBBB). A prior study evaluated 52 patients with syncope and a bundle branch block who underwent ILR implantation following an unremarkable initial evaluation, which included an electrophysiological study [8]. Syncope recurred in 42% of these patients; the ILR showed that recurrent syncope was commonly (but not always) attributable to paroxysmal AV block. Our patient had a normal echocardiogram and underwent ILR placement; 6 weeks later, recurrent syncope was shown to correlate with an episode of complete heart block with ventricular asystole.

A multicenter, randomized, clinical trial is currently underway to assess whether a strategy of empiric permanent pacemaker implantation in patients with syncope ( $\geq 1$  syncopal episode in the preceding year), bifascicular block, and preserved left ventricular function improves future outcome more effectively than a strategy of therapy guided by prolonged monitoring with an ILR [9]. The primary outcome measure will be a composite of adverse events, such as death, syncope, asymptomatic diagnostic bradycardia, symptomatic bradycardia, and acute and chronic device complications; secondary endpoints will include syncope symptoms, quality of life, and economic burden. Finally, in patients with recurrent vasovagal syncope, the ILR provides information about the characteristics of the heart rhythm during recurrent syncope and may help guide decisions regarding specific therapy [10, 11].

A critical need in ILRs has been for the device to transmit acquired data of clinical significance wirelessly to providers. We reported the clinical utility of a wireless ILR, which was commercially available in the United States for a brief period, in 50 consecutive patients in whom syncope was either recurrent, associated with trauma or an abnormal ECG [6]. A diagnosis was made in nearly a third of our patients. An arrhythmia was responsible for syncope in 69% of these patients; all arrhythmias were captured within the first 6-months of ILR implantation. Of note, had ECG monitoring been limited to 30 days (as is typical of currently available ambulatory external ECG monitors), the diagnosis would have been missed in the majority of patients. The most common etiology for recurrent syncope was a bradyarrhythmia, either due to sinus node dysfunction or complete heart block. We found that these patients frequently did not activate their ILR at the time of recurrent syncope. The wireless ILR transferred ECG data (automatically) to a central monitoring station within minutes to hours of the arrhythmic event, virtually eliminating the possibility of data loss. This facilitated clinical decision making in these patients.

The recent release of a third generation loop recorder (Medtronic Reveal LINQ™) has fundamentally altered the landscape of diagnostic monitoring in patients with unexplained syncope [12]. This device is small (measures approximately  $7 \times 45 \times 4$  mm, or 1 cc), has an over 3-year battery capacity, can be implanted within minutes (subcutaneously 2 cm from the left lower border of the sternum at the fourth intercostal space and at a 45° angle from the plane of the sternum) using only

local anesthesia, and wirelessly transfers acquired data to providers nightly. In addition, it has automated algorithms for the detection and storage of significant brady- and tachyarrhythmias, including atrial fibrillation. The following are examples of how this new technology has facilitated clinical decision making in our practice.

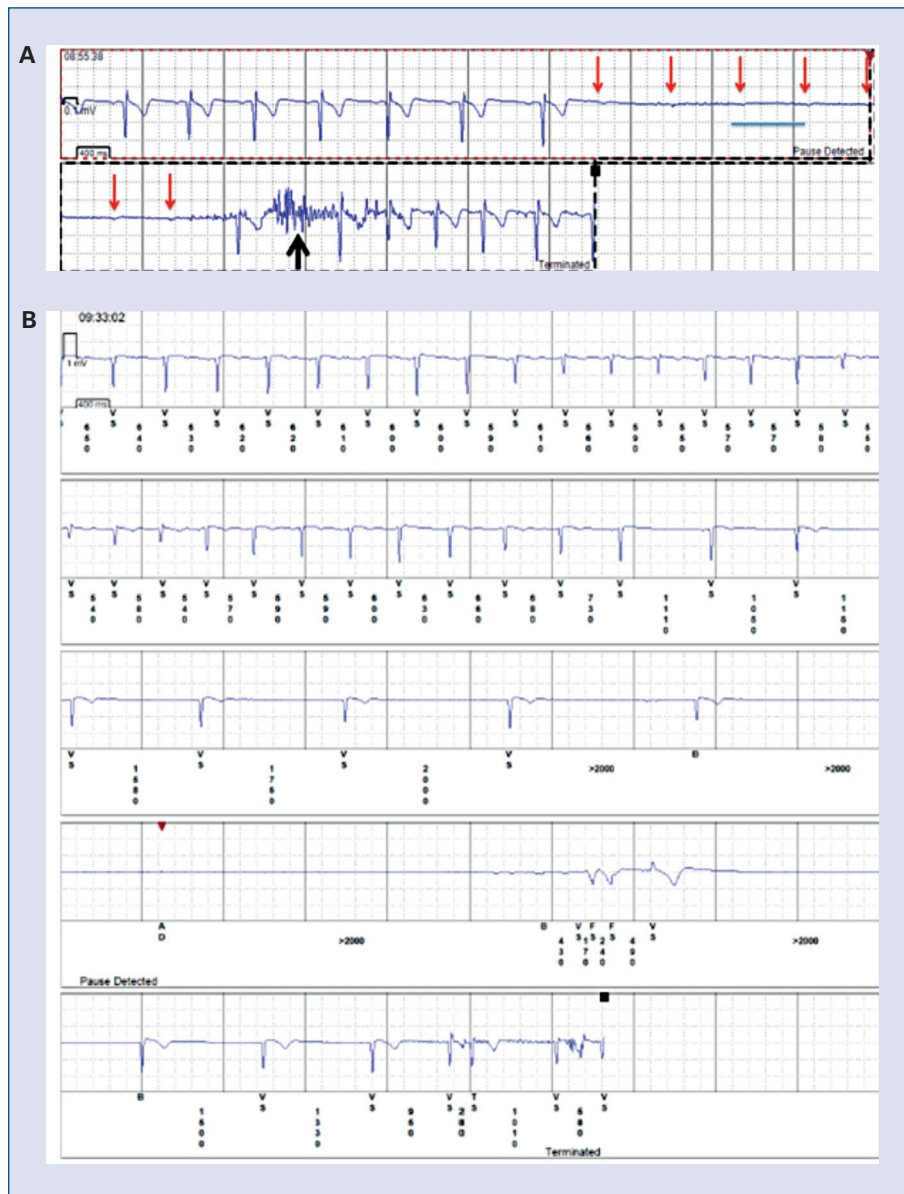
### Case vignette no. 2

A 46-year-old male presented for evaluation because of frequent episodes of palpitations (typically during periods of exertion) as well as frequent episodes of pre-syncope (typically when he is lying down). He denied any episodes of syncope. In addition, he had a strong family history of sudden death. His brother died suddenly at age 25 and his father died suddenly at age 44; an autopsy demonstrated a ruptured aortic aneurysm in the father. The patient had previously used a 30-day event recorder; no symptoms occurred during the monitoring period. Therefore, he underwent ILR implantation. Three weeks following the device implantation, he reported another episode of near-syncope while driving; the ILR recorded an episode of complete heart block with ventricular asystole (Fig. 2A). The ILR was explanted and a dual chamber pacemaker was implanted; the patient has been asymptomatic since.

### Case vignette no. 3

A 70-year-old female was referred in April 2014 for evaluation following 2 episodes of syncope. She had known moderate mitral regurgitation and LBBB. In September 2012, she was diagnosed with breast cancer and underwent bilateral radical mastectomy followed by chemotherapy and radiation. Unfortunately, in early 2014 she was diagnosed with acute myelogenous leukemia. While in the midst of chemotherapy, she had 2 episodes of syncope. The second episode resulted in a subdural hematoma, subarachnoid hemorrhage, and a laceration to her forehead. An echocardiogram showed mild left ventricular dysfunction (ejection fraction 40–45%); a nuclear stress test showed no perfusion defects and confirmed the mild left ventricular dysfunction. She was advised by another consultant to consider dual chamber ICD implantation. Following a second opinion, she received an ILR for long-term ECG monitoring. Four months later, she suffered another syncopal episode while walking from her bed to the bathroom. She suffered a fracture of her left arm. The patient's husband immediately used the patient activator to store the patient's ECG. **No arrhythmia** was recorded during the episode.





**Figure 2. A.** Transient complete heart block. The patient is in sinus rhythm. The PR interval is normal and the QRS complex is narrow. There is abrupt development of complete heart block with ventricular asystole; the red arrows mark the P waves representing the underlying and unperturbed sinus rhythm. The black arrow likely reflects myoclonus occurring during a brief period of altered consciousness; **B.** Abrupt sinus slowing followed by sinus arrest, which resulted in syncope.

#### Case vignette no. 4

An 83-year-old obese female with hypertension and diabetes was admitted following her fourth syncopal episode in the past 2 years. Her baseline ECG and echocardiogram were normal. During her most recent episode, she was standing in her kitchen talking with her daughter when she started to feel light-headed and then had frank syncope. She hit the back of her head but quickly regained consciousness; there was no post-ictal state. She received an ILR for long-term ECG monitoring.

Four months later, she had another witnessed episode of syncope. Interrogation of the device showed an episode of abrupt sinus slowing followed by sinus arrest (Fig. 2B); the ILR was removed and a dual chamber pacemaker was implanted. The patient has been asymptomatic since.

#### Conclusions

The evaluation of the patient who presents with unexplained syncope should incorporate

a structured approach. Unfortunately, recent data from a survey of 43 countries suggest that only 42% of centers had a specific standardized protocol or algorithm for the assessment of patients with unexplained syncope [13]. Thus, it is not surprising that there was a wide variability in the likelihood that patients would be hospitalized at these centers for further evaluation. Early risk stratification of patients is necessary to determine those who will benefit from either pacemaker or ICD implantation as well as to identify those patients who require additional medical or neurologic evaluation. In the remaining patients, we have found ILRs to have significant diagnostic utility. Surprisingly, recent data from a survey of 45 centers showed a relatively low use of ILRs in patients with recurrent syncope with no underlying structural heart disease, in high-risk patients in whom a comprehensive evaluation could not clarify the cause of syncope, and in patients with suspected neurally-mediated syncope to assess the contribution of bradycardia before embarking on specific therapy [14]. It remains to be determined, however, whether the acceptance of the ILR will change dramatically given the recent availability of the miniaturized Reveal LINQ™ system.

**Conflict of interest:** Consultant to Biotronik, Boston Scientific, Medtronic, Scottcare, Sorin, and St. Jude Medical.

## References

1. Soteriades ES, Evans JC, Larson MG et al. Incidence and prognosis of syncope. *N Engl J Med*, 2002; 347: 978–885.
2. Brignole M. Diagnosis and treatment of syncope. *Heart*, 2007; 93: 130–136.
3. Colivicchi F, Ammirati F, Melina D, Guido V, Imperoli G, Santini M, for the OESIL (Osservatorio Epidemiologico sulla Sincope nel Lazio) study investigators. Development and prospective validation of a risk stratification system for patients with syncope in the emergency department: The OESIL risk score. *Eur Heart J*, 2003; 24: 811–819.
4. Guidelines for the diagnosis and management of syncope (version 2009): The task force for the diagnosis and management of syncope of the European Society of Cardiology. *Eur Heart J*, 2009; 30: 2631–2671.
5. Brignole M, Vardas P, Hoffman E et al. Indications for the use of diagnostic implantable and external ECG loop recorders. *Europace*, 2009; 11: 671–687.
6. Paruchuri V, Adhaduk M, Garikipati NV, Steinberg JS, Mittal S. Clinical utility of a novel wireless implantable loop recorder in the evaluation of patients with unexplained syncope. *Heart Rhythm*, 2011; 8: 858–863.
7. Edvardsson N, Frykman V, van Mechelen R et al.; on behalf of the PICTURE Study Investigators. Use of an implantable loop recorder to increase the diagnostic yield in unexplained syncope: Results from the PICTURE registry. *Europace*, 2011; 13: 262–269.
8. Brignole M, Menozzi C, Moya A et al.; on behalf of the International Study on Syncope of Uncertain Etiology (ISSUE) Investigators. Mechanism of syncope in patients with bundle branch block and negative electrophysiological test. *Circulation*, 2001; 1004: 2045–2050.
9. Krahn AD, Morillo CA, Kus T et al. Empiric pacemaker compared with a monitoring strategy in patients with syncope and bifascicular conduction block – rationale and design of the Syncope: Pacing or Recording in The Later Years (SPRITELY) study. *Europace*, 2012; 14: 1044–1048.
10. Brignole M, Menozzi C, Moya A et al. Pacemaker therapy in patients with neurally mediated syncope and documented asystole: Third International Study on Syncope of Uncertain Etiology (ISSUE-3): A randomized trial. *Circulation*, 2012; 125: 2566–2571.
11. Brignole M, Donato P, Tomaino M et al. Benefit of pacemaker therapy in patients with presumed neurally mediated syncope and documented asystole is greater when tilt test is negative: An analysis from the Third International Study on Syncope of Uncertain Etiology (ISSUE-3). *Circ Arrhythm Electrophysiol*, 2014; 7: 10–16.
12. Tomson TT, Passman R. The Reveal LINQ insertable cardiac monitor. *Expert Rev Med Devices*, 2014; Aug 26. [Epub ahead of print].
13. Dagues N, Bongiorni MG, Dobeanu D, Madrid A, Svendsen JH, Blomstrom-Lundqvist C; conducted by the Scientific Initiatives Committee, European Heart Rhythm Association. Current investigation and management of patients with syncope: Results of the European Heart Rhythm Association survey. *Europace*, 2013; 15: 1812–1815.
14. Sciaraffia E, Chen J, Hocini M, Larsen TB, Potpara T, Blomstrom-Lundqvist C. Use of event recorders and loop recorders in clinical practice: Results of the European Heart Rhythm Association Survey. *Europace*, 2014; 16: 1384–1386.