

# Sustained ventricular tachycardia in structural heart disease

Claudio Hadid

Arrhythmias and Electrophysiology Section, Division of Cardiology,  
Hospital Cosme Argerich, Buenos Aires, Argentina

## Abstract

*Ventricular arrhythmias are responsible for the majority of sudden cardiac deaths (SCD), particularly in patients with structural heart disease. Coronary artery disease, essentially previous myocardial infarction, is the most common heart disease upon which sustained ventricular tachycardia (VT) occurs, being reentry the predominant mechanism. Other cardiac conditions, such as idiopathic dilated cardiomyopathy, Chagas disease, sarcoidosis, arrhythmogenic cardiomyopathies, and repaired congenital heart disease may also present with VT in follow-up. Analysis of the 12-lead electrocardiogram (ECG) is essential for diagnosis. There are numerous electrocardiographic criteria that suggest VT with good specificity. The ECG also guides us in locating the site of origin of the arrhythmia and the presence of underlying heart disease. The electrophysiological study provides valuable information to establish the mechanism of the arrhythmia and guide the ablation procedure, as well as to confirm the diagnosis when dubious ECG. Given the poor efficacy of antiarrhythmic drug therapy, adjunctive catheter ablation contributes to reduce the frequency of VT episodes and the number of shocks in patients implanted with a cardioverter-defibrillator (ICD). ICD therapy has proven to be effective in patients with aborted SCD or sustained VT in the presence of structural heart disease. It is the only therapy that improves survival in this patient population and its implantation is unquestioned nowadays. (Cardiol J 2015; 22, 1: 12–24)*

**Key words:** ventricular tachycardia, electrocardiogram, implantable cardioverter-defibrillator, catheter ablation

## Introduction

Cardiovascular disease remains the leading cause of death. About half of all cardiovascular deaths occur suddenly [1, 2], mostly due to sustained ventricular arrhythmias [3, 4]. Coronary artery disease (CAD), primarily a history of myocardial infarction (MI), represents the most common underlying heart disease upon which sustained monomorphic ventricular tachycardia (SMVT) and ventricular fibrillation (VF) develop. However, they can also

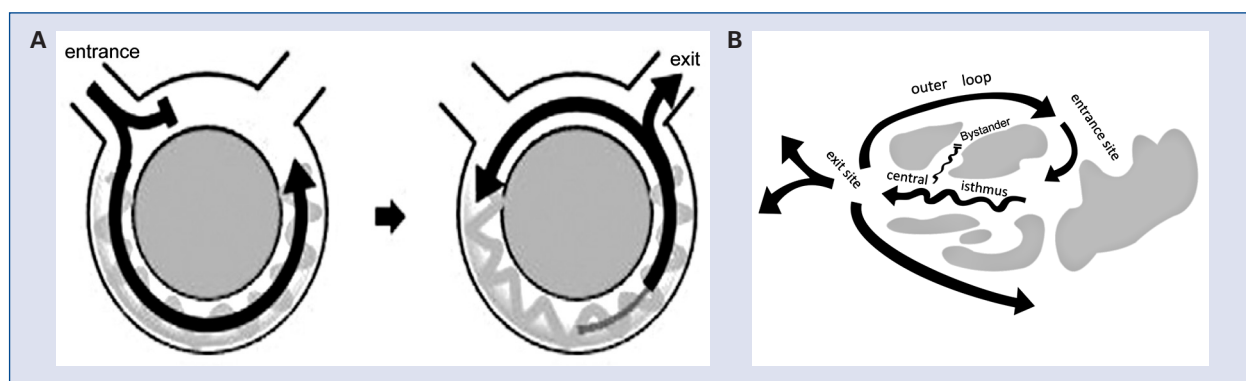
occur in patients with other cardiac conditions, such as non-ischemic idiopathic dilated cardiomyopathy, Chagas disease, sarcoidosis, arrhythmogenic cardiomyopathies or repaired congenital heart disease [5–7]. SMVT can also happen in the absence of structural heart disease (i.e. outflow tract ventricular arrhythmias; idiopathic left ventricular [LV] tachycardia, but rarely has a fatal outcome.

This paper reviews the most relevant aspects of sustained VT associated to structural heart disease.

**Address for correspondence:** Claudio Hadid, MD, Arrhythmias and Electrophysiology Section, Division of Cardiology, Hospital Cosme Argerich, Cuba 2370. 9th floor. Apt A. CABA. 1428. Buenos Aires, Argentina, tel: +541141210821, e-mail: [claudio.hadid@gmail.com](mailto:claudio.hadid@gmail.com)

Received: 23.12.2013

Accepted: 24.08.2014



**Figure 1.** A. Simplified scheme of a reentrant circuit. When local block occurs during sinus rhythm (unidirectional block), the propagated impulse activates the zone of block (already repolarized) retrogradely and the reentry circuit initiates; B. Schematic circuit of ventricular tachycardia (and its components). Conduction pathways can be seen surrounded by areas of scar.

### Substrate and mechanisms of sustained ventricular tachycardia

VT occurring in the chronic phase of MI is usually topographically related to the infarcted region. Post-MI scarring represents the arrhythmogenic substrate for the development of a reentry circuit. Whereas the VT associated with a healed MI constitutes the clinical paradigm of reentry, focal activation by abnormal automaticity is the main mechanism involved in the VT arising from the ischemic border zone during acute ischemia [8–10].

In Chagas disease, areas of myocardial fibrosis, resulting from focal myocarditis processes, also constitute a predisposing substrate for generation of reentrant ventricular arrhythmias. These fibrotic zones are usually located in the epicardium or subepicardium, which has important implications for the ablation procedure [11, 12]. Unlike CAD, in Chagas disease SMVT can occur with minimal or no structural heart disease [13].

It is accepted that reentrant VT occurring in patients with previous MI originates mainly in bundles of viable myocardium within the scar. In this setting, local heterogeneity of conduction times and duration of cellular refractory periods predispose to unidirectional block and enables the beginning of a reentrant circuit (Fig. 1).

Although focal VT has been described, scar-related reentry is the most common VT mechanism in the majority of the cardiac conditions that lead to VT: non-ischemic dilated cardiomyopathy (small intramural scars); arrhythmogenic right ventricular cardiomyopathy (areas of fibrofatty replacement); sarcoidosis (intramyocardial granulomas); surgically repaired congenital heart disease

(ventriculotomy, patches) [7, 14, 15]. In non-ischemic dilated cardiomyopathy, bundle branch reentry can also occur, especially in patients with His-Purkinje disease (i.e. left bundle branch block [LBBB]; prolonged HV interval) [16].

### Clinical presentation

Clinical presentation of patients with VT is variable. If the arrhythmia is slow and stable, patients may experience palpitations, chest pain, dyspnea, or be completely asymptomatic. The clinical impact of the arrhythmia depends on several factors such as the VT cycle length, the LV systolic function, and the autonomic tone. In patients with Chagas disease SMVT can also occur in the absence of severe LV dysfunction and, hence, be hemodynamically stable. Nonetheless, 2 retrospective analyses of the AVID Registry showed that the hemodynamic impact of the qualifying arrhythmia was not a predictor of outcome [17, 18]. VT is often poorly tolerated leading to syncope and sudden cardiac death. Incessant VT (defined as recurrent episodes of VT that persist for hours), even if well tolerated, can lead to hemodynamic deterioration, heart failure, and death [14, 19]. It may become dramatic in patients with implantable cardioverter-defibrillator (ICD). This situation is named electrical storm when three or more episodes of sustained VT occur within 24 h, each requiring termination by an intervention (usually ICD shock) [7, 19, 20]. A recent meta-analysis confirmed that patients with electrical storm have an adverse prognosis, including higher mortality [21]. Moreover, repeated ICD shocks have been shown to contribute to LV impairment and additionally

**Table 1.** Electrocardiographic criteria for ventricular tachycardia.

|                        |  |  |
|------------------------|--|--|
| VA relationship        | <ul style="list-style-type: none"> <li>• VA dissociation</li> <li>• Capture and fusion beats</li> <li>• VA relationship &gt; 1</li> </ul>  |  |
| Precordial leads       | <ul style="list-style-type: none"> <li>• Absence of RS complexes (positive or negative concordance)</li> <li>• R to nadir S interval &gt; 100 ms</li> </ul>  |  |
| Specific QRS patterns  | <i>“Right BBB”-type morphology</i>   | <i>“Left BBB”-type morphology</i>  |
| Duration:              | <ul style="list-style-type: none"> <li>• &gt; 140 ms</li> </ul>  | <ul style="list-style-type: none"> <li>• &gt; 160 ms</li> </ul>  |
| V1:                    | <ul style="list-style-type: none"> <li>• Monophasic R wave</li> <li>• R wave &gt; R' wave</li> <li>• qR or RS complex</li> </ul>   | <ul style="list-style-type: none"> <li>• r wave &gt; 30 ms</li> <li>• &gt; 60 ms to nadir S</li> <li>• Notched S wave</li> </ul> |
| V6:                    | <ul style="list-style-type: none"> <li>• R/S &lt; 1</li> <li>• QS or QR complex</li> </ul>   | <ul style="list-style-type: none"> <li>• Q wave</li> </ul>   |
| aVR lead               | <ul style="list-style-type: none"> <li>• Initial R wave</li> <li>• Initial r or q wave &gt; 40 ms</li> <li>• Notch on the descending limb of a negative onset and predominantly negative QRS</li> <li>• <math>v_i / v_t &lt; 1</math></li> </ul> |  |
| If BBB in sinus rhythm | <ul style="list-style-type: none"> <li>• Contralateral BBB during VT</li> <li>• Narrower QRS complex during VT</li> </ul>  |  |

VA — ventriculo-atrial; BBB — bundle branch block;  $v_i$  — voltage of the initial 40 ms of the QRS complex;  $v_t$  — voltage of the terminal 40 ms of the QRS complex; VT — ventricular tachycardia

worsen patient’s prognosis, in terms of increased risk of hospitalization for heart failure and death [22–25]. Reduction in cardiac index and troponin I release have been attributed to ICD discharges [26–28]. Pathology studies showed that ICDs can cause direct myocardial injury, contraction band necrosis, fibrosis, myocardial cell damage and possibly persistent inflammation [29, 30].

### Electrocardiographic manifestations

The first electrocardiographic (ECG) challenge we face is to make the diagnosis of VT. Although this arrhythmia may show some irregularity, SMVT in the presence of CAD is usually regular. Differential diagnosis should be made with other wide QRS complex regular tachycardias, such as supraventricular tachycardia (SVT) with bundle branch block (permanent or associated to rapid heart rate) and antidromic tachycardia (QRS fully preexcited).

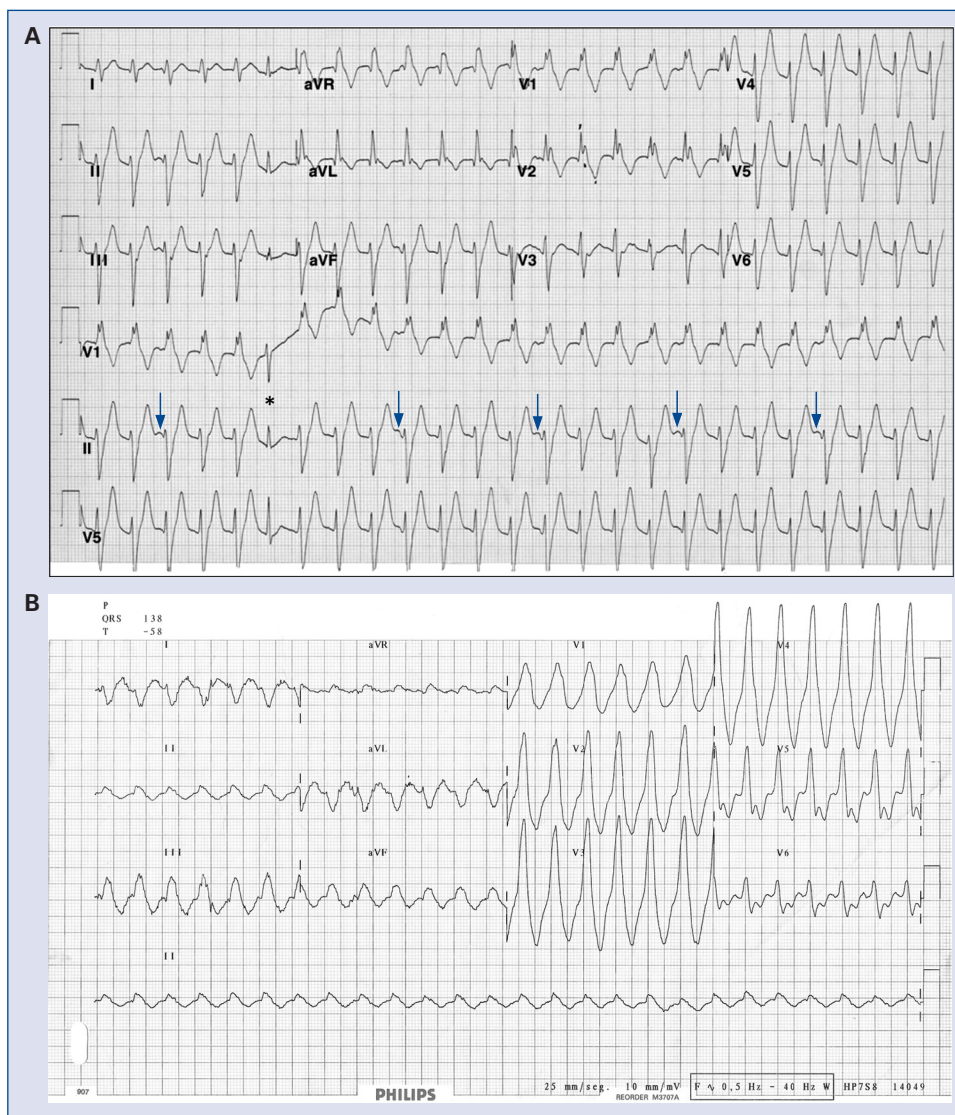
Antidromic tachycardia occurs in patients with Wolff-Parkinson-White syndrome, usually young and without history of cardiovascular disease. The ECG shows high voltage QRS complexes in precordial leads and not as wide as in VT. The diagnosis is easier after interruption of the tachycardia when a pattern of preexcitation during sinus rhythm (SR)

(short PR interval, widened QRS with delta wave and repolarization disorders) can be seen.

The diagnosis of a wide QRS tachycardia is a real challenge for the physician, not only for the difficulty in recognizing certain ECG criteria, but also for the circumstances in which it occurs (often requiring a rapid diagnosis) and the consequences of an incorrect conclusion, which could be harmful for the patient. For example, a hemodynamically well-tolerated tachycardia can induce the physician to think of a supraventricular origin. If the tachycardia is actually VT, verapamil administration in order to treat SVT can produce hypotension and transform a stable situation into a poorly tolerated VT requiring immediate electrical cardioversion. When evaluating a wide complex QRS tachycardia, it is important to remember that VT is the most common diagnosis (up to 80% of cases) [31].

Different ECG criteria for differentiating VT from SVT with aberrancy have been described [32–35]. The presence of any of them strongly suggests the diagnosis of VT (high specificity), but their absence does not rule it out (modest sensitivity). Table 1 summarizes the main proposed criteria.

P wave visualization allows us to establish the atrioventricular (AV) relationship. The lack of relationship between p waves and QRS complexes (AV dissociation) is virtually diagnostic of VT.



**Figure 2. A.** Right bundle branch block-type ventricular tachycardia (VT) with dissociated p waves (arrows) and a capture beat (\*); **B.** VT in a patient with Chagas cardiomyopathy. Some electrocardiographically criteria that indicate VT can be observed such as r nadir to S > 100 ms, pure R wave in V1, R/S ratio < 1 in V6, QRS duration 240 ms.

If more QRS complexes than p waves are observed, the diagnosis of VT is also very likely. The existence of capture (narrow QRS and equal to that during SR) or fusion beats (QRS of intermediate duration between those the during SR and during tachycardia) is synonymous to AV dissociation, and therefore, indicates VT (Fig. 2A). The absence of AV dissociation does not indicate SVT, i.e. VT with 1:1 retrograde conduction or with underlying atrial fibrillation. In the latter case, a wide QRS, regular tachycardia is always VT.

The VT morphology in precordial leads gives us important information for diagnostic purposes. The absence of an RS complex from V1 to V6

(positive or negative concordance) showed 100% specificity for the diagnosis of VT, except for very rare cases (i.e. patients with a history of previous extensive MI and QS complexes from V1 to V6 during SR) it is unlikely for a conduction disorder to cause such an ECG pattern.

In the presence of RS complexes in precordial leads, an interval between the onset of the R wave and the deepest part of the S wave (namely, R to nadir S) > 100 ms also indicates VT (Fig. 2B). This criterion is based on the concept that ventricular beats originate in the diseased myocardium, far from the Purkinje fibers, with longer conduction times. Hence, the QRS complexes exhibit a slow upstroke and long duration.

According to QRS configuration in precordial leads (primarily in V1), VT morphology can be “classified” as “right bundle branch block (RBBB) like” or “LBBB like”. For each of these situations there are ECG patterns in V1 and V6 that suggest VT (Table 1). When these criteria are met in both V1 and V6 it is indicative of VT (Fig. 2B). Brugada et al. [33] developed a diagnostic algorithm using the aforementioned criteria, with good sensitivity (98.7%) and specificity (96.5%).

Recently, Vereckei et al. [34] focused attention on aVR lead and proposed a different algorithm using only this lead. The presence of an initial dominant R wave, an initial r or q wave lasting > 40 ms or a notch on the initial descendent wave of a predominantly negative QRS complex in aVR are indicative criteria of VT. The fourth criterion of the algorithm is a voltage ratio ( $v_i/v_t$ ) measured in millivolts between the initial 40 ms ( $v_i$ ) and the terminal 40 ms ( $v_t$ ) of the QRS. A ratio < 1 would indicate a slower initial activation (less myocardial mass is activated in the same period of time) and indicates VT. Identification of an R wave in a VR lead as diagnostic of VT matches older concepts in that extreme right axis deviation (between  $-90^\circ$  and  $-180^\circ$ ) is unlikely produced by a conducted beat and suggests a ventricular origin.

Another useful clue is to compare the QRS morphology during SR and during tachycardia. In the presence of bundle branch block during SR, a narrower QRS during tachycardia is suggestive of VT. Importantly, QRS duration should be measured in the lead that shows the widest QRS complex. Similarly, a QRS morphology with contralateral bundle branch block-like configuration than that during SR is more likely to be produced by VT. If no changes in the electrical axis or QRS morphology are seen, SVT may be assumed [36]. An exception to this rule is VT due to bundle-branch reentry, in which the QRS morphology during tachycardia and SR is often similar [37].

The ECG during SR also allows us to identify Q waves from remote MI. When the location of these Q waves matches that of negative QRS complexes during tachycardia it also suggests VT [38].

By ECG analysis, more than 1 SMVT morphology can be identified. In the latest consensus document on VT ablation the term multiple monomorphic VTs was established for more than 1 morphologically distinct monomorphic VT, occurring as different episodes [7]. On the other hand, pleomorphic VT was defined as more than 1 morphologically distinct QRS complex spontaneously occurring during the same VT episode,

but the QRS is not continuously changing (i.e. 2 or more “stable” morphologies) [7]. This phenomenon (that differs from polymorphic VT) can be seen at the onset of a monomorphic VT, when a change in QRS configuration occurs towards a different but stable morphology. In contrast, polymorphic VT has a continuously changing QRS configuration from beat to beat [7]. By analyzing 1,881 SMVT episodes in patients with ICD (> 80% with coronary heart disease) we found an incidence of 6% of spontaneous pleomorphism and 19% of multiple morphologies [39]. Both phenomena were associated to increased overall mortality, but only pleomorphism was an independent predictor of total mortality. The appearance of these morphological changes should be identified in patients’ follow-up in order to apply therapy changes towards prevention of progressive clinical worsening. In this setting, we reported the case of a patient with Chagas disease who had multiple VT morphologies (2 different VTs) and developed electrical storm with LV ejection fraction (LVEF) deterioration and decompensated heart failure. After radiofrequency catheter ablation of the 2 spontaneous VT, our patient remained free from VT episodes, with LVEF recovery [40].

#### Location of the origin of ventricular tachycardia

The ECG obtained during VT provides essential information about the region of origin of the arrhythmia [41]. Importantly, surface ECG from a reentrant VT tends to locate the exit site of the circuit, rather than the circuit in which it is generated.

In general, the location must be defined on 3 axes: (a) septal and lateral wall, (b) anterosuperior wall and inferior wall, (c) apical vs. basal region [35]. The bundle branch block pattern is related to ventricular activation sequence. VTs arising from LV lateral wall exhibit a RBBB-type pattern with wider QRS complexes due to sequential activation of both ventricles. VTs with septal origin can show LBBB-type pattern in V1 and narrower QRS complexes due to early involvement of the His-Purkinje fibers and simultaneous activation of the 2 ventricles. In the absence of CAD, most LBBB-VTs originate in the RV. In patients with previous MI, QRS polarity in inferior leads indicates the activation sequence between the anterior and inferior wall. An inferior MI leaves a scar on the diaphragmatic wall that is the source of a VT with superior axis (negative QRS in aVF) in 80% of cases. Instead, VT originated in a previous anterior MI may have superior (55% of cases) or

inferior axis deviation (positive QRS in aVF, 45% of cases) [9]. Finally, the dominant polarity of the QRS complexes in precordial leads may be useful to differentiate VTs originating in basal regions of the LV from those arising from the apex. In apical VTs, ventricular activation spreads away from all precordial leads and surface ECG shows a pattern of negative concordance. The opposite situation happens in VTs originating in basal regions that are characterized by a positive concordance in the precordial leads.

### **Evaluation of patients with ventricular tachycardia**

In patients with VT, the presence of underlying heart disease should be evaluated. Cardiac ultrasound provides excellent information in this regard. In addition to the assessment of ventricular systolic function, ventricular hypertrophy (indicative of hypertrophic cardiomyopathy) can be found, as well as regional wall motion abnormalities suggestive of previous MI (topographic correlation with coronary anatomy) or Chagas disease (usually anteroapical or posterobasal dyskinesia).

The 24-h ECG monitoring (Holter) does not provide additional information in patients with documented sustained VT. In patients with no history of VT, asymptomatic episodes of non-sustained VT (< 30 s duration) may be found. Nevertheless, Holter monitoring has not been useful in guiding antiarrhythmic drug (AAD) therapy [42].

In patients with ischemic cardiomyopathy and suspected VT (because of palpitations, presyncope or syncope), the aim of the electrophysiological study (EPS) is to induce sustained VT by programmed ventricular stimulation (class I recommendation, level of evidence B) [14]. In the rest of cardiomyopathies above mentioned (other than ischemic cardiomyopathy) the EPS plays a minor role due to its low positive and negative predictive values (non-ischemic dilated cardiomyopathy) or lack of clinical evidence (Chagas disease) [14]. In the presence of a wide QRS tachycardia of difficult diagnosis, an EPS should be performed to distinguish VT from SVT with aberrant conduction (class I recommendation, level of evidence C) [14]. In patients with SMVT candidates to catheter ablation, the EPS permits an identification of the tachycardia mechanism and helps to guide the ablation procedure (class I recommendation, level of evidence B) [14]. Although focal VTs can be initiated by burst pacing, the ability to reproducibly start and finish a VT by programmed ventricular

stimulation is suggestive of reentry [8]. In the same way, a reentrant mechanism can be confirmed by entrainment maneuvers. Indeed, entrainment with manifest fusion in surface ECG can only occur in reentrant VT. Finally, the EPS can also be performed for risk stratification of sudden death in patients with previous MI, non-sustained VT and LVEF  $\leq$  40% (class IIa recommendation, level of evidence B) [14, 43, 44].

### **Therapy**

The goals of therapy in patients presenting with VT are to decrease VT related symptoms and morbidity and to reduce the risk of death.

Treatment with AAD cannot be considered a sole therapy (see trails of ICD vs. AAD therapy below), except for special populations such as patients who did not meet criteria for ICD implantation or those with mildly symptomatic VT and no structural heart disease.

However, AADs are usually prescribed as adjunctive therapy of ICD. Beta-blockers and sotalol confer clinical benefit in terms of reducing arrhythmia recurrences and ICD shocks [45, 46]. The OPTIC study compared 3 therapeutic schemes (beta-blockers; sotalol or amiodarone + beta-blockers) in patients implanted with an ICD [47]. The combination of amiodarone + beta-blockers was superior the other schemes in reducing ICD shocks but with an increased risk of drug-related adverse effects. Since 70% of patients assigned to the beta-blocker arm were free from ICD shocks, it is reasonable to keep patients with beta-blockers only and “wait” for the first shock to add amiodarone. Finally, dofetilide has also shown to decrease the frequency of VT/VF episodes in patients with ICD, even after failure of other AAD [48].

### **Implantable cardioverter-defibrillator**

Early clinical studies that demonstrated benefit with ICD therapy enrolled patients with LV dysfunction and aborted sudden cardiac death or poorly tolerated VT. Three randomized clinical trials (Table 2) compared the efficacy of ICD therapy and AAD in this group of patients (secondary prevention) [49–51].

The first study was the AVID trial, which included the largest number of patients (n = 1,016) resuscitated from VF; VT with syncope or poorly tolerated VT with LVEF < 40% [52]. This study was prematurely stopped because of a clear benefit of ICD therapy (significant 31% reduction of total mortality).

**Table 2.** Implantable cardioverter-defibrillator trials for secondary prevention of sudden death.

|                                  | AVID   | CIDS   | CASH  |
|----------------------------------|--|--|---|
| Year of publication              | 1997   | 2000   | 2000  |
| N                                | 1016   | 659  | 288   |
| Inclusion criteria               | <ul style="list-style-type: none"> <li>• Resuscitated from near-fatal VF</li> <li>• Sustained VT with syncope</li> <li>• VT with hemodynamic compromise and LVEF &lt; 40%</li> </ul> | <ul style="list-style-type: none"> <li>• Documented VF</li> <li>• Out-of-hospital cardiac arrest</li> <li>• Sustained VT with syncope</li> <li>• Symptomatic SVT and LVEF &lt; 35%</li> <li>• Syncope and inducible SVT</li> </ul> | <ul style="list-style-type: none"> <li>• Resuscitated from cardiac arrest secondary to sustained ventricular arrhythmias</li> </ul> |
| Mean LVEF [%]                    | 31   | 33   | 46  |
| Follow-up [months]               | 18   | 36   | 57  |
| Mortality control group [%]      | 36   | 10.2/year  | 45  |
| Mortality ICD group [%]          | 25   | 8.3/year   | 36  |
| Mortality relative reduction [%] | 31   | 19.7   | 23  |
| Mortality absolute reduction [%] | 11   | 6  | 9   |
| NNT                              | 9  | 17   | 11  |

ICD — implantable cardioverter-defibrillator; LVEF — left ventricular ejection fraction; NNT — number of patients needed to be treated to save one life; SVT — supraventricular tachycardia; VF — ventricular fibrillation; VT — ventricular tachycardia

The CIDS study enrolled 659 patients with similar characteristics, although it included 14% of patients with unexplained syncope and inducible VT on EPS [49]. There was a non-significant reduction in total (19.7%) and arrhythmic (32.8%) death. A later report of 1 enrolling center of this study showed a significant reduction in mortality with extended follow-up [53].

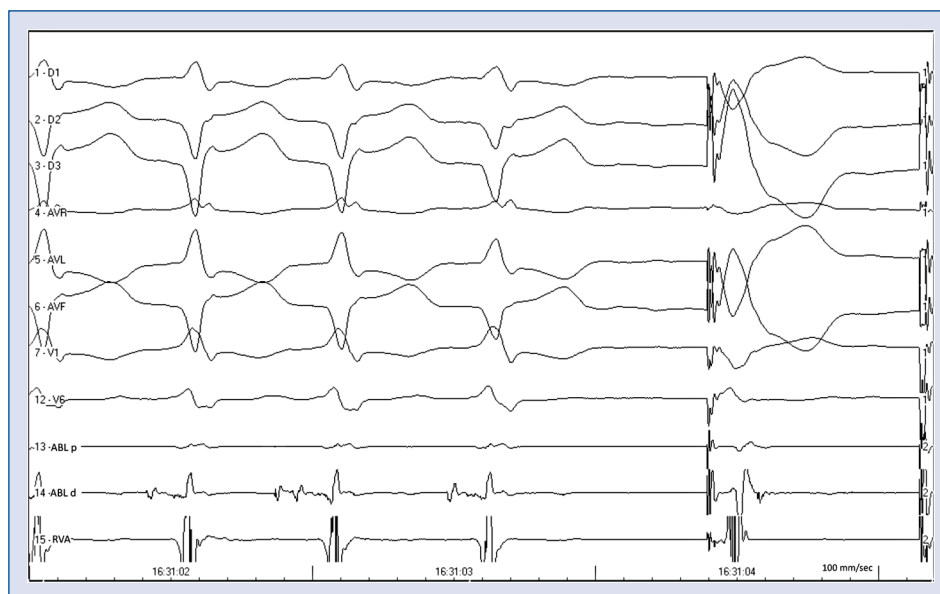The CASH study was the smallest one (n = 346) and included only patients with resuscitated sudden arrhythmic death [50]. Patients were younger (58 vs. 65 years old) and had higher LVEF (46% vs. 31–33%) than in the above-mentioned studies and up to 10% of patients had no structural heart disease. After excluding patients assigned to drug therapy with propafenone (who had increased mortality), the analysis of the remaining 288 patients showed a non-significant 23.4% reduction in overall mortality with ICD compared to AAD therapy (amiodarone or metoprolol) [51].

Although the reduction in mortality was only significant in AVID, probably due to a greater sample size, it was consistent in the 3 studies. A meta-analysis that combined the databases from these 3 studies showed a significant reduction in overall (RRR 28%, 95% CI 13–40%) and arrhythmic mortality (RRR 50%, 95% CI 33–63%). Further subgroup analysis showed that the benefit was greatest in patients with low LVEF (< 30–35%) [54–56].

As shown in Table 2, inclusion criteria in these 3 trials were similar but not the same. As opposed to the CASH study, in AVID and CIDS studies VT was differentiated from VF or cardiac arrest as entry criteria. Both studies reported subgroup analyses and showed no different ICD benefit in patients presented with VT or VF [49, 52]. The inclusion CASH study did not make any distinction in the qualifying rhythm.

The results of these studies were so overwhelming that international guidelines recommend ICD implantation in these patients as class I [57–60]. Nowadays, nobody questions the implantation of an ICD in a patient with aborted cardiac arrest, documented VF or VT with hemodynamic compromise.

As stated above, stable VT is not considered a benign rhythm and poorly tolerated arrhythmia recurrences can occur [61, 62]. The adverse outcome of these patients is similar to that of patients with unstable VT [17, 18]. Moreover, benefit of ICD therapy appears to be not different in patients presenting with VT or VF. All these considerations make appropriate the indication of ICD therapy in patients with hemodynamically stable VT and LVEF ≤ 40% [60]. In patients with tolerated VT and LVEF > 40% recommendation of ICD implantation is more weak and catheter ablation may be helpful in preventing arrhythmia recurrences.



**Figure 3.** Surface electrocardiogram and intracardiac recordings showing abnormal electrograms at the site of origin of ventricular tachycardia (VT). A fractionated prepotential is recorded with the ablation catheter in the first 3 beats (VT). During radiofrequency delivery at that point VT is interrupted and ventricular pacing from the implantable cardioverter-defibrillator begins. This ventricular site that was recording a presystolic electrogram during VT, is now recording low-amplitude late potential at the end of the QRS. The abnormal potential recorded during VT identified a critical component of the reentry circuit; ABL — ablation catheter; RVA — right ventricular apex.

### Catheter ablation

Given the poor efficacy of drug therapy, percutaneous ablation becomes the more attractive option to reduce the frequency of VT episodes and ICD shocks in these patients, including those with incessant VT [14].

The objectives of the ablation procedure are: (1) the non-induction of clinical VT (clinical VT refers to the spontaneous SMVT presented by the patient), (2) the non-induction of any SMVT, and (3) modification of the cycle length of induced VT (elimination of all VTs with cycle lengths equal to or greater than that of the clinical VT) [7].

As discussed previously, reentry is the predominant mechanism in VT associated with structural heart disease. Inducible VT and a good hemodynamic tolerance are 2 conditions that help for the ablation procedure, since catheter mapping should be performed during VT. This mapping allows the identification of the ventricular region from which the impulse arises (through sequences of activation and electrogram prematurity), scar areas (absence of electrograms), healthy myocardium (normal electrograms) and viable regions surrounding and within the scars (abnormal, diastolic and fractionated electrograms with multiple components, low voltages and prolonged duration). Areas with such

abnormal electrograms are often related to the VT circuit, especially when recorded before the onset of the QRS during VT (Fig. 3).

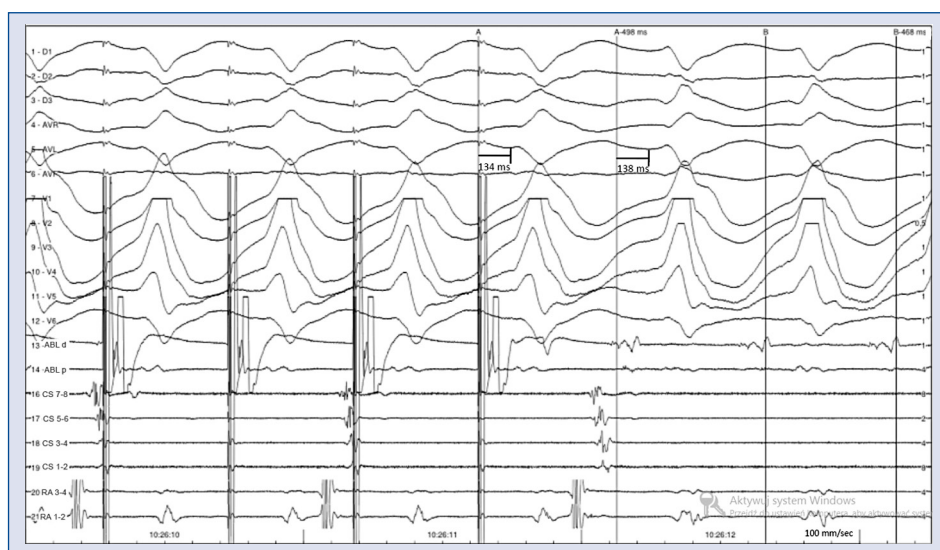
By overdrive ventricular pacing techniques (resetting and entrainment of the tachycardia) the VT circuit can be defined, as well as its critical components (entrance and exit sites, shared isthmus of slow conduction, outer loops of the circuit, etc.) (Fig. 1B). Entrainment of VT can be performed by pacing at sites that are either within or outside the reentry circuit. Thus, analysis of the QRS configuration and intracardiac electrograms during entrainment, as well as the postpacing interval after the last entrained beat can be used to identify the target sites for radiofrequency ablation (Table 3) [63]. The interval from the last stimulus that entrains the VT to the next local electrogram at the pacing site (postpacing interval — PPI) is equal ( $\pm 30$  ms) to the tachycardia cycle length (TCL) when the pacing site is within the reentry circuit. When the interval from the last stimulus that entrains the tachycardia to the beginning of the last entrained QRS complex is equal ( $\pm 20$  ms) to that from the local electrogram to the beginning of the QRS complex during VT it is also indicative that the pacing site is within the reentry circuit (Fig. 4). The configuration of the QRS complex during



**Table 3.** Different patterns of response to entrainment mapping.

| $PPI - TCL = 0 \pm 30 \text{ ms}$ or $(S-QRS) - (EGM-QRS) = 0 \pm 20 \text{ ms}$ |                    |                                |
|--|--------------------|--------------------------------|
|  | NO                 | YES                            |
| Manifest fusion  | Remote bystander   | Outer loop                     |
| Concealed fusion   | Adjacent bystander | $(S-QRS) \times 100 / TCL$     |
|  |                    | < 30% Exit site/distal isthmus |
|  |                    | 30–50% Central isthmus         |
|  |                    | 50–70% Proximal isthmus        |
|  |                    | > 70% Inner loop               |

PPI — post-pacing interval; TCL — tachycardia cycle length; S-QRS — time from stimulus to QRS onset; EGM — time from local electrogram to QRS onset

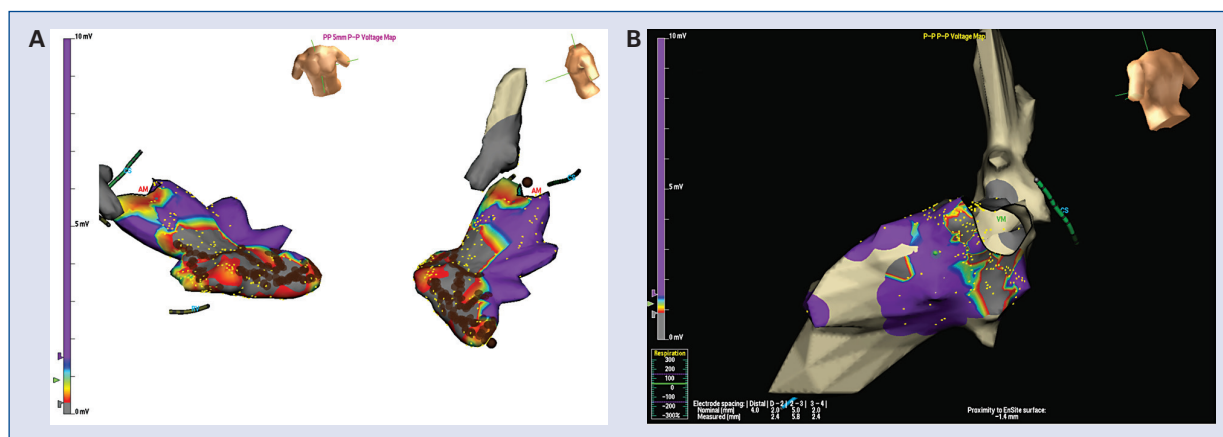


**Figure 4.** Surface electrocardiogram and intracardiac recordings showing entrainment with concealed fusion of sustained monomorphic ventricular tachycardia.  $PPI - TCL = 30 \text{ ms}$  and  $S-QRS - EGM-QRS = 4 \text{ ms}$ . These findings suggest a critical isthmus site. See text for discussion; ABL — ablation catheter; CS — coronary sinus; RA — right atrium; PPI — post-pacing interval; TCL — tachycardia cycle length; S-QRS — time from stimulus to QRS onset; EGM — time from local electrogram to QRS onset.

entrainment also provides useful information. Surface ECG fusion during entrainment occurs due to collision between the stimulated wavefront and the tachycardia. It can be seen when pacing outside the reentry circuit (PPI greater than TCL by  $> 30 \text{ ms}$ ) or at an outer loop of the circuit ( $PPI = TCL \pm 30 \text{ ms}$ ). When the QRS morphology during entrainment is identical to that during VT, collision of both wavefronts occurs near the pacing site or in the zone of slow conduction of the circuit. It has been called entrainment with concealed fusion and together with a  $PPI = TCL$  identifies the central isthmus of the circuit, which is the main target for ablation (Fig. 4) [64]. Isolated mid-diastolic potentials are typically recorded at these points. A stimulus that fails to capture

the ventricles but interrupts the tachycardia is also indicative that the pacing site is at a protected zone that composes or is near the critical isthmus [65].

New technologies allow us to perform 3-dimensional (3D) electroanatomical geometry of the ventricular chamber and visualize the position of the ablation catheter in real time. Areas of scar, healthy and viable myocardium (voltage map) as well as regions near to and far from the site of origin of the tachycardia (activation and propagation maps) can be identified and displayed by color-coding (Fig. 5) [66, 67]. This information, in conjunction with intracardiac recordings and entrainment techniques, is a valuable guide for VT ablation and contributes decisively to the success of the procedure.



**Figure 5.** Electroanatomic voltage 3-dimensional maps from EnSite Navx (St. Jude Medical). **A.** Large scar (grey zone) in the apical anterolateral region of the left ventricle in a patient with previous myocardial infarction. Viable zones surrounding and within the dense scar (red-yellow) and healthy zones (purple) can be observed, as well as, radiofrequency lesions (brown dots); **B.** Basal posterolateral scar in a patient with Chagas cardiomyopathy.

In general, the ablation is effective acutely, and produces the abolition of 1 or more scar-related SMVT in up to 77–95% of cases [68, 69]. However, VT recurrence with the same morphology, or more often with a different morphology, may occur in 12–50% of patients, and further ablation procedures may be needed. In consequence, successful VT ablation does not eliminate the need for ICD therapy or AAD. Epicardial ablation, through percutaneous access of the pericardial space guided by fluoroscopy and contrast injection, may also be needed, especially in Chagas disease [69, 70].

In cases of unmappable (non-inducible, poorly tolerated, or morphology-changing) VT, substrate ablation during SR can be performed by the use of 3D navigation systems. With this technique, radiofrequency energy is delivered in regions with scar tissue that topographically correlate to the region of origin of VT, as suggested by the ECG, where abnormal (fractionated, late, low voltage) potentials are recorded [7]. Areas of extremely low voltage ( $< 0.5$  mV) are designated as “dense scar”, but it is important to recognize that these regions can still contain viable myocytes and reentry circuit isthmuses [71]. Linear radiofrequency lesions extended from the dense scar to anatomic boundaries or normal endocardium are effective in controlling unmappable VT [72, 73]. Local stimulation at that point during SR (“pacemapping technique”) can reproduce the VT morphology if the catheter is located near the exit site of the reentrant circuit. This technique is often combined with substrate mapping to define the potential exit, which can

be identified along the border of the scar [72, 74]. Radiofrequency lesions can then be placed parallel to the infarct border zone (where bipolar electrogram amplitude is typically between 0.5 mV and 1.0 mV). Sites where pacing produces a long S-QRS but matches the VT morphology are seen at some reentry circuit isthmus sites and can also be targeted for ablation [75]. However, pacemapping is more useful in cases of focal VT, and can be confusing in reentrant VT. Abnormal potentials recorded during sinus or paced rhythm allow the identification of potential channels within the dense scar and have been targeted for ablation with good results [76–78].

Substrate ablation was evaluated in patients with previous MI and ICD implantation for secondary prevention of SCD in the SMASH-VT study [79]. Patients ( $n = 128$ ) were randomized to ICD alone or ICD + substrate ablation. The ablation group showed a significant 65% reduction in ICD therapies for VT/VF and a non-significant 47% improvement in survival, without procedure-related mortality. More recently, local abnormal ventricular activities (so-called LAVAs) have been identified as a new target for substrate ablation in patients with scar-related VT [80]. LAVAs were defined as high-frequency ventricular potentials occurring during or after the far-field ventricular electrogram (not necessary late potentials) and their abolition was associated with lower VT recurrence. Another end-point described for substrate modification is the endo-epicardial homogenization of the scar (ablation of all abnormal potentials recorded within

the scar). In patients with ischemic cardiomyopathy and electrical storm, this technique was superior to limited substrate ablation in terms of freedom from arrhythmia [81]. In non-inducible patients without ECG documentation of clinical VT, elimination of all areas with late potentials has also proved to reduce arrhythmia recurrence [82].

For patients with non-tolerated VT, hemodynamic support systems (so-called LV assist devices) are increasingly used. These percutaneous devices are retrogradely placed via aorta and basically extract blood from LV and deliver it in the proximal aorta. It results in a better hemodynamic tolerance of the arrhythmia and allows mapping [83]. Both Impella and TandemHeart devices gave a good hemodynamic support and were superior to intra-aortic balloon pump [84, 85].

An understanding of anatomy is important for mapping and ablation. Pre-procedural imaging (magnetic resonance imaging [MRI], computed tomography [CT] or positron emission tomography [PET]-CT) is usually obtained to identify the arrhythmia substrate and anatomic obstacles to ablation. Magnetic resonance is perhaps the more accurate imaging method to define scar extension and tachycardia-related conducting channels [86, 87]. Unfortunately, MRI is limited in these patients since many of them have implanted devices. Contrast-enhanced CT and PET can be performed in patients with cardiac devices and have also been used to guide VT ablations [88, 89]. The images obtained by these methods can be incorporated into the 3D navigator systems to help the anatomic reconstruction.

In the case of bundle-branch reentry VT, ablation of the RBBB is the treatment of choice [90]. However, given that it usually occurs in patients with dilated cardiomyopathy, the occurrence of myocardial VT in follow-up usually requires additional interventions such as ICD implantation or further ablation.

## Conclusions

Evaluation of patients with VT should begin with a thorough analysis of the ECG. The EPS is essential to establish the arrhythmia mechanism and to guide the ablation procedure. ICD therapy improves survival in secondary prevention of sudden death. Catheter ablation of VT reduces the number of VT episodes and ICD shocks.

**Conflict of interest:** None declared

## References

1. Myerburg RJ, Kessler KM, Castellanos A. Sudden cardiac death: Epidemiology, transient risk, and intervention assessment. *Ann Intern Med*, 1993; 119: 1187–1197.
2. Myerburg RJ, Interian A Jr, Mitrani RM, Kessler KM, Castellanos A. Frequency of sudden cardiac death and profiles of risk. *Am J Cardiol*, 1997; 80: 10F–19F.
3. Myerburg RJ, Castellanos A. Cardiac arrest and sudden cardiac death. In: Braunwald E ed. *Heart disease: A text book of cardiovascular medicine*. 4 Ed. WB Saunders, Philadelphia 1992: 756–789.
4. Hallstrom AP, Eisenberg MS, Bergner L. The persistence of ventricular fibrillation and its implication for evaluating EMS. *Emerg Health Serv Q*, 1982; 1: 41–49.
5. Dias E, Laranja FS, Miranda A, Nobrega G. Chagas' disease; a clinical, epidemiologic, and pathologic study. *Circulation*, 1956; 14: 1035–1060.
6. Di Toro D, Muratore C, Aguinaga L et al. Predictors of all-cause 1-year mortality in implantable cardioverter defibrillator patients with chronic Chagas' cardiomyopathy. *Pacing Clin Electrophysiol*, 2011; 34: 1063–1069.
7. Aliot EM, Stevenson WG, Almendral-Garrote JM et al. EHRA/HRS Expert Consensus on Catheter Ablation of Ventricular Arrhythmias: Developed in a partnership with the European Heart Rhythm Association (EHRA), a Registered Branch of the European Society of Cardiology (ESC), and the Heart Rhythm Society (HRS); in collaboration with the American College of Cardiology (ACC) and the American Heart Association (AHA). *Heart Rhythm*, 2009; 6: 886–933.
8. Josephson ME, Almendral JM, Buxton AE, Marchlinski FE. Mechanisms of ventricular tachycardia. *Circulation*, 1987; 75 (4 Part 2): III41–III47.
9. Josephson M. Recurrent ventricular tachycardia. In: *Clinical cardiac electrophysiology. Technics and interpretations*. 4 Ed. Lippincott Wilkins & Williams, Philadelphia 2008: 446–642.
10. Carmeliet E. Cardiac ionic currents and acute ischemia: from channels to arrhythmias. *Physiol Rev*, 1999; 79: 917–1017.
11. Benvenuti LA, Gutierrez PS. Epicardial lesions in Chagas' heart disease reflect an inflammatory process. *Arq Bras Cardiol*, 2007; 88: 496–498.
12. Sosa E, Scanavacca M, D'Avila A et al. Endocardial and epicardial ablation guided by nonsurgical transthoracic epicardial mapping to treat recurrent ventricular tachycardia. *J Cardiovasc Electrophysiol*, 1998; 9: 229–39.
13. Rassi A Jr, Rassi A, Little WC. Chagas' heart disease. *Clin Cardiol*, 2000; 23: 883–889.
14. Zipes DP, Camm AJ, Borggrefe M et al. ACC/AHA/ESC 2006 Guidelines for Management of Patients With Ventricular Arrhythmias and the Prevention of Sudden Cardiac Death: a report of the American College of Cardiology/American Heart Association Task Force and the European Society of Cardiology Committee for Practice Guidelines (writing committee to develop Guidelines for Management of Patients With Ventricular Arrhythmias and the Prevention of Sudden Cardiac Death): Developed in collaboration with the European Heart Rhythm Association and the Heart Rhythm Society. *Circulation*, 2006; 114: e385–e484.
15. Birnie DH, Sauer WH, Bogun F et al. HRS expert consensus statement on the diagnosis and management of arrhythmias associated with cardiac sarcoidosis. *Heart Rhythm*, 2014; 11: 1305–1323.
16. Caceres J, Jazayeri M, McKinnie J et al. Sustained bundle branch reentry as a mechanism of clinical tachycardia. *Circulation*, 1989; 79: 256–270.
17. Pinski SL, Yao Q, Epstein AE et al. Determinants of outcome in patients with sustained ventricular tachyarrhythmias: the antiarrhythmics versus implantable defibrillators (AVID) study registry. *Am Heart J*, 2000; 139: 804–813.
18. Raitt MH, Renfroe EG, Epstein AE et al. "Stable" ventricular tachycardia is not a benign rhythm: insights from the antiarrhythmics versus implantable defibrillators (AVID) registry. *Circulation*, 2001; 103: 244–252.
19. Exner DV, Pinski SL, Wyse DG et al. Electrical storm presages non-sudden death: The antiarrhythmics versus implantable defibrillators (AVID) trial. *Circulation*, 2001; 103: 2066–2071.
20. Carbucicchio C, Santamaria M, Trevisi N et al. Catheter ablation for the treatment of electrical storm in patients with implantable cardioverter-

- defibrillators: short- and long-term outcomes in a prospective single-center study. *Circulation*, 2008; 117: 462–469.
21. Guerra F, Shkoza M, Scappini L, Flori M, Capucci A. Role of electrical storm as a mortality and morbidity risk factor and its clinical predictors: A meta-analysis. *Europace*, 2014; 16: 347–353.
  22. Poole JE, Johnson GW, Hellkamp AS et al. Prognostic importance of defibrillator shocks in patients with heart failure. *N Engl J Med*, 2008; 359: 1009–1017.
  23. Sweeney MO, Sherfese L, DeGroot PJ, Wathen MS, Wilkoff BL. Differences in effects of electrical therapy type for ventricular arrhythmias on mortality in implantable cardioverter-defibrillator patients. *Heart Rhythm*, 2010; 7: 353–360.
  24. Daubert JP, Zareba W, Cannom DS et al. Inappropriate implantable cardioverter-defibrillator shocks in MADIT II: frequency, mechanisms, predictors, and survival impact. *J Am Coll Cardiol*, 2008; 51: 1357–1365.
  25. Cevik C, Perez-Verdia A, Nugent K. Implantable cardioverter defibrillators and their role in heart failure progression. *Europace*, 2009; 11: 710–715.
  26. Tokano T, Bach D, Chang J et al. Effect of ventricular shock strength on cardiac hemodynamics. *J Cardiovasc Electrophysiol*, 1998; 9: 791–797.
  27. Joglar JA, Kessler DJ, Welch PJ et al. Effects of repeated electrical defibrillations on cardiac troponin I levels. *Am J Cardiol*, 1999; 83: A6, 270–272.
  28. Hasdemir C, Shah N, Rao AP et al. Analysis of troponin I levels after spontaneous implantable cardioverter defibrillator shocks. *J Cardiovasc Electrophysiol*, 2002; 13: 144–150.
  29. Singer I, Hutchins GM, Mirowski M et al. Pathologic findings related to the lead system and repeated defibrillations in patients with the automatic implantable cardioverter-defibrillator. *J Am Coll Cardiol*, 1987; 10: 382–388.
  30. Hurst TM, Hinrichs M, Breidenbach C, Katz N, Waldecker B. Detection of myocardial injury during transvenous implantation of automatic cardioverter-defibrillators. *J Am Coll Cardiol*, 1999; 34: 402–408.
  31. Miller JM, Hsia HH, Rothman SA, Buxton AE. Ventricular tachycardia versus supraventricular tachycardia with aberration: electrocardiographic distinctions. In: Zipes D, Jalife J eds. *Cardiac electrophysiology: From cell to bedside*. 3 Ed. Sanders WB, Philadelphia 2000: 696–705.
  32. Wellens HJ, Bär FW, Lie KI. The value of the electrocardiogram in the differential diagnosis of a tachycardia with a widened QRS complex. *Am J Med*, 1978; 64: 27–33.
  33. Brugada P, Brugada J, Mont L, Smeets J, Andries EW. A new approach to the differential diagnosis of a regular tachycardia with a wide QRS complex. *Circulation*, 1991; 83: 1649–1659.
  34. Vereckei A, Duray G, Szénási G, Altemose GT, Miller JM. New algorithm using only lead aVR for differential diagnosis of wide QRS complex tachycardia. *Heart Rhythm*, 2008; 5: 89–98.
  35. Benito B, Josephson ME. Ventricular tachycardia in coronary artery disease. *Rev Esp Cardiol Engl Ed*, 2012; 65: 939–955.
  36. Dongas J, Lehmann MH, Mahmud R, Denker S, Soni J, Akhtar M. Value of preexisting bundle branch block in the electrocardiographic differentiation of supraventricular from ventricular origin of wide QRS tachycardia. *Am J Cardiol*, 1985; 55: 717–721.
  37. Oretto G, Smeets JL, Rodriguez LM, Timmermans C, Wellens HJ. Wide complex tachycardia with atrioventricular dissociation and QRS morphology identical to that of sinus rhythm: a manifestation of bundle branch reentry. *Heart Br Card Soc*, 1996; 76: 541–547.
  38. Miller JM, Marchlinski FE, Buxton AE, Josephson ME. Relationship between the 12-lead electrocardiogram during ventricular tachycardia and endocardial site of origin in patients with coronary artery disease. *Circulation*, 1988; 77: 759–766.
  39. Hadid C, Almendral J, Ortiz M et al. Incidence, determinants, and prognostic implications of true pleomorphism of ventricular tachycardia in patients with implantable cardioverter-defibrillators: A substudy of the DATAS Trial. *Circ Arrhythm Electrophysiol*, 2011; 4: 33–42.
  40. Hadid C, Gallino S, Di Toro D et al. Multiple morphologies of ventricular tachycardia assessed by implantable cardioverter-defibrillator electrograms in a patient with Chagas disease, successfully treated with catheter ablation: modern problems, old solutions. *Europace*, 2012; 14: 1660.
  41. Pytkowski M, Maciąg A, Sterliński M et al. Novel algorithm for arrhythmogenic focus localization in patients with right ventricular outflow tract arrhythmias. *Cardiol J*, 2014; 21: 284–292.
  42. Mason JW. A comparison of electrophysiologic testing with Holter monitoring to predict antiarrhythmic-drug efficacy for ventricular tachyarrhythmias. *Electrophysiologic Study versus Electrocardiographic Monitoring Investigators*. *N Engl J Med*, 1993; 329: 445–451.
  43. Moss AJ, Hall WJ, Cannom DS et al. Improved survival with an implanted defibrillator in patients with coronary disease at high risk for ventricular arrhythmia. Multicenter Automatic Defibrillator Implantation Trial Investigators. *N Engl J Med*, 1996; 335: 1933–1940.
  44. Buxton AE, Lee KL, DiCarlo L et al. Electrophysiologic testing to identify patients with coronary artery disease who are at risk for sudden death. Multicenter Unsustained Tachycardia Trial Investigators. *N Engl J Med*, 2000; 342: 1937–1945.
  45. Ho AT, Pai SM, Timothy P, Pai RG. Effect of concomitant antiarrhythmic therapy on survival in patients with implantable cardioverter defibrillators. *PACE*, 2005; 28: 647–653.
  46. Pacifico A, Hohnloser SH, Williams JH et al. Prevention of implantable-defibrillator shocks by treatment with sotalol. d,l-Sotalol Implantable Cardioverter-Defibrillator Study Group. *N Engl J Med*, 1999; 340: 1855–1862.
  47. Connolly SJ, Dorian P, Roberts RS et al. Comparison of beta-blockers, amiodarone plus beta-blockers, or sotalol for prevention of shocks from implantable cardioverter defibrillators: the OPTIC Study: A randomized trial. *JAMA J Am Med Assoc*, 2006; 295: 165–171.
  48. Baquero GA, Banchs JE, Depalma S et al. Dofetilide reduces the frequency of ventricular arrhythmias and implantable cardioverter defibrillator therapies. *J Cardiovasc Electrophysiol*, 2012; 23: 296–301.
  49. Connolly SJ, Gent M, Roberts RS et al. Canadian implantable defibrillator study (CIDS): A randomized trial of the implantable cardioverter defibrillator against amiodarone. *Circulation*, 2000; 101: 1297–1302.
  50. Siebels J, Kuck KH. Implantable cardioverter defibrillator compared with antiarrhythmic drug treatment in cardiac arrest survivors (the Cardiac Arrest Study Hamburg). *Am Heart J*, 1994; 127 (4 Part 2): 1139–1144.
  51. Kuck KH, Cappato R, Siebels J, Ruppel R. Randomized comparison of antiarrhythmic drug therapy with implantable defibrillators in patients resuscitated from cardiac arrest: The Cardiac Arrest Study Hamburg (CASH). *Circulation*, 2000; 102: 748–754.
  52. The Antiarrhythmics versus Implantable Defibrillators (AVID) Investigators. A comparison of antiarrhythmic-drug therapy with implantable defibrillators in patients resuscitated from near-fatal ventricular arrhythmias. *N Engl J Med*, 1997; 337: 1576–1583.
  53. Bokhari F, Newman D, Greene M, Korley V, Mangat I, Dorian P. Long-term comparison of the implantable cardioverter defibrillator versus amiodarone: Eleven-year follow-up of a subset of patients in the Canadian Implantable Defibrillator Study (CIDS). *Circulation*, 2004; 110: 112–116.
  54. Connolly SJ, Hallstrom AP, Cappato R et al. Meta-analysis of the implantable cardioverter defibrillator secondary prevention trials. AVID, CASH and CIDS studies. Antiarrhythmics vs Implantable Defibrillator study. *Cardiac Arrest Study Hamburg*. Canadian Implantable Defibrillator Study. *Eur Heart J*, 2000; 21: 2071–2078.
  55. Domanski MJ, Sakseena S, Epstein AE et al. Relative effectiveness of the implantable cardioverter-defibrillator and antiarrhythmic drugs in patients with varying degrees of left ventricular dysfunction who have survived malignant ventricular arrhythmias. *Antiarrhythmics Versus Implantable Defibrillators (AVID) Investigators*. *J Am Coll Cardiol*, 1999; 34: 1090–1095.
  56. Sheldon R, Connolly S, Krahn A, Roberts R, Gent M, Gardner M. Identification of patients most likely to benefit from implantable cardioverter-defibrillator therapy: The Canadian Implantable Defibrillator Study. *Circulation*, 2000; 101: 1660–1604.
  57. Epstein AE, Dimarco JP, Ellenbogen KA et al. ACC/AHA/HRS 2008 Guidelines for device-based therapy of cardiac rhythm abnormalities. *Heart Rhythm*, 2008; 5: e1–e62.
  58. McMurray JJV, Adamopoulos S, Anker SD et al. ESC Guidelines for the diagnosis and treatment of acute and chronic heart failure 2012: The Task Force for the Diagnosis and Treatment of Acute and Chronic Heart Failure 2012 of the European Society of Cardiology. Developed in collaboration with the Heart Failure Association (HFA) of the ESC. *Eur Heart J*, 2012; 33: 1787–1847.
  59. Retyk E, Bochoeyer A, Sampo E et al. Consenso de Prevención Primaria y Secundaria de Muerte Súbita. Sociedad Argentina de Cardiología, Sociedad Uruguaya de Cardiología (con la colaboración de CONAREC). *Rev Argent Cardiol*, 2012; 80: 1–10.

60. Russo AM, Stainback RF, Bailey SR et al. ACCF/HRS/AHA/ASE/HFSA/SCAI/SCCT/SCMR 2013 appropriate use criteria for implantable cardioverter-defibrillators and cardiac resynchronization therapy: A report of the American College of Cardiology Foundation appropriate use criteria task force, Heart Rhythm Society, American Heart Association, American Society of Echocardiography, Heart Failure Society of America, Society for Cardiovascular Angiography and Interventions, Society of Cardiovascular Computed Tomography, and Society for Cardiovascular Magnetic Resonance. *Heart Rhythm*, 2013; 10: e11–e58.
61. Böcker D, Block M, Isbruch F et al. Benefits of treatment with implantable cardioverter-defibrillators in patients with stable ventricular tachycardia without cardiac arrest. *Br Heart J*, 1995; 73: 158–163.
62. Glikson M, Lipchen I, Viskin S et al. Long-term outcome of patients who received implantable cardioverter defibrillators for stable ventricular tachycardia. *J Cardiovasc Electrophysiol*, 2004; 15: 658–664.
63. Stevenson WG, Friedman PL, Sager PT et al. Exploring postinfarction reentrant ventricular tachycardia with entrainment mapping. *J Am Coll Cardiol*, 1997; 29: 1180–1189.
64. Morady F, Kadish A, Rosenheck S et al. Concealed entrainment as a guide for catheter ablation of ventricular tachycardia in patients with prior myocardial infarction. *J Am Coll Cardiol*, 1991; 17: 678–689.
65. Shenasa M, Cardinal R, Kus T, Savard P, Fromer M, Pagé P. Termination of sustained ventricular tachycardia by ultrarapid subthreshold stimulation in humans. *Circulation*, 1988; 78 (5 Part 1): 1135–1143.
66. Gepstein L, Hayam G, Ben-Haim SA. A novel method for nonfluoroscopic catheter-based electroanatomical mapping of the heart. In vitro and in vivo accuracy results. *Circulation*, 1997; 95: 1611–1622.
67. Klemm HU, Ventura R, Steven D et al. Catheter ablation of multiple ventricular tachycardias after myocardial infarction guided by combined contact and noncontact mapping. *Circulation*, 2007; 115: 2697–2704.
68. Stevenson WG, Soejima K. Catheter ablation for ventricular tachycardia. *Circulation*, 2007; 115: 2750–2760.
69. Henz BD, do Nascimento TA, Dietrich C de O et al. Simultaneous epicardial and endocardial substrate mapping and radiofrequency catheter ablation as first-line treatment for ventricular tachycardia and frequent ICD shocks in chronic Chagasic cardiomyopathy. *J Interv Card Electrophysiol Int J Arrhythm Pacing*, 2009; 26: 195–205.
70. Sosa E, Scanavacca M, d'Avila A, Oliveira F, Ramires JA. Nonsurgical transthoracic epicardial catheter ablation to treat recurrent ventricular tachycardia occurring late after myocardial infarction. *J Am Coll Cardiol*, 2000; 35: 1442–1449.
71. Soejima K, Stevenson WG, Maisel WH, Sapp JL, Epstein LM. Electrically unexcitable scar mapping based on pacing threshold for identification of the reentry circuit isthmus: Feasibility for guiding ventricular tachycardia ablation. *Circulation*, 2002; 106: 1678–1683.
72. Marchlinski FE, Callans DJ, Gottlieb CD, Zado E. Linear ablation lesions for control of unmappable ventricular tachycardia in patients with ischemic and nonischemic cardiomyopathy. *Circulation*, 2000; 101: 1288–1296.
73. Soejima K, Suzuki M, Maisel WH et al. Catheter ablation in patients with multiple and unstable ventricular tachycardias after myocardial infarction: Short ablation lines guided by reentry circuit isthmuses and sinus rhythm mapping. *Circulation*, 2001; 104: 664–669.
74. Brunckhorst CB, Stevenson WG, Soejima K et al. Relationship of slow conduction detected by pace-mapping to ventricular tachycardia re-entry circuit sites after infarction. *J Am Coll Cardiol*, 2003; 41: 802–809.
75. Brunckhorst CB, Delacretaz E, Soejima K, Maisel WH, Friedman PL, Stevenson WG. Identification of the ventricular tachycardia isthmus after infarction by pace mapping. *Circulation*, 2004; 110: 652–659.
76. Harada T, Stevenson WG, Kocovic DZ, Friedman PL. Catheter ablation of ventricular tachycardia after myocardial infarction: relation of endocardial sinus rhythm late potentials to the reentry circuit. *J Am Coll Cardiol*, 1997; 30: 1015–1023.
77. Arenal A, Glez-Torrecilla E, Ortiz M et al. Ablation of electrograms with an isolated, delayed component as treatment of unmappable monomorphic ventricular tachycardias in patients with structural heart disease. *J Am Coll Cardiol*, 2003; 41: 81–92.
78. Arenal A, del Castillo S, Gonzalez-Torrecilla E et al. Tachycardia-related channel in the scar tissue in patients with sustained monomorphic ventricular tachycardias: Influence of the voltage scar definition. *Circulation*, 2004; 110: 2568–2574.
79. Reddy VY, Reynolds MR, Neuzil P et al. Prophylactic catheter ablation for the prevention of defibrillator therapy. *N Engl J Med*, 2007; 357: 2657–2665.
80. Jaïs P, Maury P, Khairy P et al. Elimination of local abnormal ventricular activities: a new end point for substrate modification in patients with scar-related ventricular tachycardia. *Circulation*, 2012; 125: 2184–2196.
81. Di Biase L, Santangeli P, Burkhardt DJ et al. Endo-epicardial homogenization of the scar versus limited substrate ablation for the treatment of electrical storms in patients with ischemic cardiomyopathy. *J Am Coll Cardiol*, 2012; 60: 132–141.
82. Vergara P, Trevisi N, Ricco A et al. Late potentials abolition as an additional technique for reduction of arrhythmia recurrence in scar related ventricular tachycardia ablation. *J Cardiovasc Electrophysiol*, 2012; 23: 621–627.
83. Miller MA, Dukkupati SR, Mittnacht AJ et al. Activation and entrainment mapping of hemodynamically unstable ventricular tachycardia using a percutaneous left ventricular assist device. *J Am Coll Cardiol*, 2011; 58: 1363–1371.
84. Miller MA, Dukkupati SR, Chinitz JS et al. Percutaneous hemodynamic support with Impella 2.5 during scar-related ventricular tachycardia ablation (PERMIT 1). *Circ Arrhythm Electrophysiol*, 2013; 6: 151–159.
85. Reddy YM, Chinitz L, Mansour M et al. Percutaneous left ventricular assist devices in ventricular tachycardia ablation: multi-center experience. *Circ Arrhythm Electrophysiol*, 2014; 7: 244–250.
86. Nazarian S, Bluemke DA, Lardo AC et al. Magnetic resonance assessment of the substrate for inducible ventricular tachycardia in nonischemic cardiomyopathy. *Circulation*, 2005; 112: 2821–2825.
87. Perez-David E, Arenal A, Rubio-Guivernau JL et al. Noninvasive identification of ventricular tachycardia-related conducting channels using contrast-enhanced magnetic resonance imaging in patients with chronic myocardial infarction: Comparison of signal intensity scar mapping and endocardial voltage mapping. *J Am Coll Cardiol*, 2011; 57: 184–194.
88. Bello D, Kipper S, Valderrábano M, Shivkumar K. Catheter ablation of ventricular tachycardia guided by contrast-enhanced cardiac computed tomography. *Heart Rhythm*, 2004; 1: 490–492.
89. Dickfeld T, Kocher C. The role of integrated PET-CT scar maps for guiding ventricular tachycardia ablations. *Curr Cardiol Rep*, 2008; 10: 149–157.
90. Cohen TJ, Chien WW, Lurie KG et al. Radiofrequency catheter ablation for treatment of bundle branch reentrant ventricular tachycardia: results and long-term follow-up. *J Am Coll Cardiol*, 1991; 18: 1767–1773.