

# Management of refractory angina pectoris

Aarush Manchanda<sup>1</sup>, Ashim Aggarwal<sup>2</sup>, Nupur Aggarwal<sup>3</sup>, Ozlem Soran<sup>4</sup>

<sup>1</sup>Intermountain Valley View Heart Clinic, Cedar City, UT, USA

<sup>2</sup>Unity Health System, Rochester, NY, USA

<sup>3</sup>Geisinger Medical Center, Danville, PA, USA

<sup>4</sup>University of Pittsburgh Medical Center, Pittsburgh, PA, USA

## Abstract

*Despite significant advances in revascularization techniques and medical therapy, there remains a significant population of patients who continue to have intractable angina symptoms. This review aims to define the patients with refractory angina pectoris (RAP) and to present the therapeutic options currently available for this condition.*

*RAP itself is defined and the pharmacological treatment options other than traditional medical therapies are discussed. The latest therapeutic options for this patient population are extensively reviewed. Among the multitude of pharmacological and non-invasive therapeutic options for patients with RAP, ranolazine is a new drug indicated for the treatment of chronic angina, in combination with amlodipine, beta-blockers or nitrates. Enhanced external counterpulsation has not only been shown to improve symptoms, but also to improve long-term ventricular function in these patients. In randomized trials, neurostimulation has been shown to be effective in reducing angina symptoms. Transmyocardial laser revascularization has emerged as an invasive treatment for RAP over the last two decades. Extracorporeal shockwave myocardial revascularization gene therapy and percutaneous in situ coronary venous arteria- lization are still under investigation. (Cardiol J 2011; 18, 4: 343–351)*

**Key words:** refractory angina, coronary artery disease

## Introduction

Refractory angina pectoris (RAP), defined as angina refractory to maximal medical therapy and standard coronary revascularization procedures, remains a significant health problem in the United States and worldwide. Despite many recent therapeutic advances, patients with RAP are not adequately treated.

An estimated 6.4 million patients in the United States suffer from symptomatic coronary artery disease (CAD), and about 400,000 new cases develop each year [1]. Despite optimal medical therapy and invasive procedures such as angioplasty and cardiac bypass surgery, an estimated 300,000 to 900,000 patients in the United States have RAP, with

between 25,000 and 75,000 new cases diagnosed each year [1]. Routine tasks such as climbing a flight of stairs, walking a block, or dusting furniture become impossible without these difficult-to-treat patients experiencing chest pain. Many patients are left to suffer from their symptoms, restrict their activities chronically, and anticipate a reduced life expectancy. Before diagnosing a patient with RAP, repeated attempts at ‘optimizing’ medical treatment and lifestyle modification (initiation of an exercise program and discontinuation of tobacco) should be made. Additionally, all secondary causes of angina, such as anemia and uncontrolled hypertension, should be excluded [2].

Current non-pharmacologic options for patients with RAP include neurostimulation (transcutaneous

**Address for correspondence:** Ashim Aggarwal, MD, MRCP, Unity Health System, Rochester, NY 14626, USA, tel: 585 732 1483, e-mail: [ashim14@gmail.com](mailto:ashim14@gmail.com)

Received: 06.01.2011

Accepted: 08.03.2011

**Table 1.** Optimal medical therapy as defined in the COURAGE trial.

1. Aspirin 81 mg/325 mg	6. ACE inhibitor/angiotensin receptor blocker
2. Plavix 75 mg if unable to use aspirin	7. Aggressive LDL-C reduction to 65–80 mg/dL alone or combination therapy
3. Long-acting beta-blocker	8. HDL-C target to > 40 mg/dL } With exercise, niacin, fibrates or combination
4. Calcium channel blocker (dihydropyridine class)	
5. Nitrates	9. TG target level to < 150 mg/dL

ACE — angiotensin converting enzyme; HDL-C — high density lipoprotein cholesterol; LDL-C — low density lipoprotein cholesterol; TG — triglyceride

electrical nerve stimulation and spinal cord stimulation), enhanced external counterpulsation (EECP) therapy, laser revascularization, gene therapy, and newer interventional procedures such as percutaneous *in situ* coronary venous arterialization and percutaneous *in situ* coronary artery bypass [2].

### How to optimize medical therapy

Optimal medical therapy is well described by the patients enrolled in the COURAGE trial and reflects a more aggressive medical treatment than traditional anti-anginal treatment [3]. Patients on optimal medical therapy should receive anti-platelet therapy with aspirin at a dose of 81–325 mg daily, or 75 mg of clopidogrel daily if intolerant to aspirin. The treatment regimen should include a long-acting beta-blocker, a calcium channel blocker, and isosorbide mononitrate, alone or in combination. If tolerated, an angiotensin-converting enzyme inhibitor or angiotensin receptor blockers could be added. Aggressive reduction of low-density lipoprotein (LDL) cholesterol to a target level of 60–85 mg/dL, using a statin alone, or in combination with ezetimibe, should be undertaken. When the LDL cholesterol target is achieved, an attempt should be made to raise high-density lipoprotein (HDL) cholesterol to above 40 mg/dL and to lower triglyceride to below 150 mg/dL, using exercise, extended-release niacin (vitamin B3) or fibrates, alone or in combination (Table 1).

### New pharmacological agents

**Ranolazine** is a piperazine derivative anti-anginal and anti-ischemic agent believed to have its effects via alteration of the intracellular sodium level, which in turn through sodium-dependent calcium channels prevents calcium overload that causes cardiac ischemia [4].

It has been shown to decrease angina episodes and improve exercise tolerance in individuals with CAD on maximal doses of amlodipine, atenolol or dil-

tiazem. Unlike traditional anti-anginal medications such as nitrates and beta-blockers, ranolazine does not significantly alter either the heart rate or blood pressure, and is therefore of particular interest in individuals with angina refractory to maximal tolerated doses of these medications. Previously, there was a concern that ranolazine increased the QT interval (approximately 2 to 6 ms) which has a theoretical risk of causing arrhythmias (Table 2). However, the findings of MERLIN TIMI 36 have assuaged this concern [5]. In 6,560 post-acute coronary syndrome non-ST elevation myocardial infarction patients, ranolazine did not show significant benefit in terms of the study’s primary endpoints of cardiovascular death, myocardial infarction (MI), or recurrent ischemia at one year follow-up, but surprisingly had a potential benefit with respect to supraventricular (SVT) and ventricular tachycardia (VT) assessed by Holter monitoring. In particular, patients treated with ranolazine had fewer episodes of VT > 8 beats, SVT, and ventricular pauses > 3 s in arrhythmia. However, studies specifically designed to evaluate the potential role of ranolazine as an anti-arrhythmic agent are warranted.

The U.S. Food and Drug Administration (FDA) approved ranolazine in 2002. It is indicated for the treatment of chronic angina, in combination with amlodipine, beta-blockers or nitrates, in patients who do not adequately respond to other anti-anginal drugs.

**Ivabradine** (Procoralan) is a member of a new class of selective heart rate (HR)–lowering agents that act specifically on the sinoatrial node (SAN). Ivabradine selectively and specifically inhibits I(f), a primary SAN pacemaker current [6], thereby reducing HR at rest and during exercise in healthy human volunteers. The safety and efficacy of ivabradine for relieving angina and underlying ischemia has been studied by Borer et al. [7] In a double-blind, placebo-controlled trial of 360 patients with chronic stable angina, 10 mg of ivabradine twice daily caused a 12% increase in the time to onset of 1-mm ST-segment depression, and a 9.5% increase

**Table 2.** Pharmacological options for treating refractory angina.

Drug	Mechanism of action	Site of action	Side effect	Caution
Ranolazine <sup>a</sup> (Ranexa)	Partial fatty oxidation inhibitor	Alters Na levels, which through the Na dependent Ca channels prevents Ca overload	Constipation, nausea, dizziness, palpitation, peripheral edema, QT prolongation	Other QT prolonging drugs, hepatic dysfunction
Ivabradine <sup>b</sup> (Procorolan)	Decreases the oxygen demand by lowering the heart rate at rest and during exercise	Specific inhibitor of I(f) sinoatrial node current	Visual disturbance (luminous visual phenomenon), bradycardia, headache	Age > 75 years, moderately reduced liver function Cr Cl < 15%
Nicorandil <sup>b</sup> (Ikorel)	Arterial vasodilator, venodilator, cardioprotective effect	K channel activator	Headache, dizziness, flushing	Hypotension, with PDE inhibitors
Allopurinol	Xanthine oxidase inhibitor	Xanthine oxidase enzyme	Nausea, diarrhea, hypersensitivity reactions, rash	Renal impairment

<sup>a</sup>FDA approved; <sup>b</sup>not FDA approved, but approved in Europe; Ca — calcium; I(f) — ‘funny’ current; K — potassium; Na — sodium; PDE — phosphodiesterase

in exercise tolerance. Additionally, the use of ivabradine resulted in a 77% decrease in the frequency of anginal events ( $p < 0.001$ ) [7]. The commonest side effect reported in studies was visual disturbance, which occurred in 14.8% of patients (Table 2). Borer et al. [6] have also reported that reduction in HR is greatest in patients with the highest pre-treatment HR: a unique property of ivabradine that may minimize the potential for it to produce excessive bradycardia in selected patients intolerant to beta-blockers.

The results of the BEAUTIFUL study [8] were presented at the European Society of Cardiology 2008, where ivabradine was evaluated in addition to optimal medical therapy. This randomized, double-blind, placebo-controlled, parallel-group trial recruited 10,917 CAD patients with left ventricular ejection fraction < 40%. Patients received ivabradine 5 mg, with the intention of up-titrating to 7.5 mg twice daily ( $n = 5,479$ ) or placebo ( $n = 5,438$ ) on top of recommended guidelines medication. Most patients were receiving beta-blockade (87%). Although the primary composite endpoint (cardiovascular death, hospitalization for acute MI, or hospitalization for new onset or worsening heart failure) was not reached for the whole group, it was beneficial in a pre-specified subgroup of patients with HR  $\geq 70$  bpm. The results are very interesting with regards to ‘heart rate’ being considered as an independent modifiable risk factor for patients with CAD [8].

Currently, ivabradine is not FDA-approved.

**Nicorandil** is a nicotinamide ester that has both nitrate-like vasodilator properties and adenosine triphosphate-potassium channel activating properties [9] which may offer cardioprotection via a ‘preconditioning’ effect. Several small randomized trials have shown nicorandil at a 10 or 20 mg twice daily dose as prolonging the time to onset of ST-segment depression and increasing exercise duration during stress testing in patients with stable angina [10, 11].

Nicorandil has also been shown to improve myocardial perfusion at rest and during exercise (Table 2). The preconditioning and possible cardioprotective effects of nicorandil were investigated in the Impact of Nicorandil in Angina (IONA) trial [12]. This found a 17% relative risk reduction ( $p = 0.014$ ) in the composite primary endpoint of death, non-fatal MI and hospitalization. The predominant adverse reactions to treatment reported were headaches and gastrointestinal discomfort [12]. More recently, the efficacy and safety of nicorandil compared to long-acting nitrate has been evaluated in Chinese patients with stable angina pectoris in a double-blind, multicenter, active-controlled, randomized clinical trial [13]; 232 patients with stable angina pectoris were randomized to receive either nicorandil (5 mg tid; 115 patients) or isosorbide mononitrate (ISMN: 20 mg bid; 117 patients) for two weeks. Nicorandil significantly decreased the number of anginal attacks and nitroglycerine consumption. Both drugs improved the total exercise time and the time to onset of chest pain on stress test-

ing. There was no significant difference between the two groups, but a trend was noticed towards more angina relief with nicorandil with equivalent safety profile. The authors concluded that nicorandil may have an equal or better anti-anginal effect than ISMN [13].

Currently, nicorandil is not FDA-approved.

**Allopurinol** is a xanthine oxidase (XO) inhibitor that has been used for many years in the treatment of gout. It inhibits the XO-catalyzed formation of uric acid from hypoxanthine and xanthine. There have been various mechanisms proposed for the anti-ischemic properties of allopurinol. Allopurinol inhibits XO-derived reactive oxygen species generation that has been proposed to contribute to ischemic injury via ATP catabolism during hypoxia [14–16]. Other proposed mechanisms have been inhibition of lipid peroxidation [17], heat shock factor expression [18], calcium sensitizing [19] and the effect on the antioxidant status of the cells [20]. A recent randomized placebo-controlled crossover study by Noman et al. [21] demonstrated the possible role of allopurinol as an effective anti-ischemic medication. They enrolled 65 patients with angiographically proven CAD who were randomly assigned to a placebo or allopurinol (600 mg per day) for six weeks before cross-over. High-dose allopurinol significantly prolonged the time to ST depression, the total exercise time, and the time to angina in patients with chronic stable angina during a standard exercise test, suggesting that endogenous xanthine oxidase activity contributes somehow to exercise-induced myocardial ischemia. The main side effects were gastrointestinal distress, hypersensitivity reactions and skin rash.

Allopurinol has not been FDA-approved for use as an anti-anginal medication. Clinical guidelines advocate the use of various drugs to optimize medical treatment in RAP. However, due to multiple drug interactions and side effects, this is not always possible. Hence, investigators have been trying to explore other non-pharmacological treatment options.

## Non-pharmacological treatments

### Enhanced external counterpulsation therapy

The technique of counterpulsation has been studied for almost half a century now. It is considered a safe, highly beneficial, low-cost, non-invasive treatment for RAP with or without left ventricular dysfunction/heart failure [2]. The technique of EECP therapy consists of electrocardiogram-gated rapid, sequential compression of the lower extremi-

ties during diastole, followed by simultaneous decompression during systole. These actions produce hemodynamic effects similar to those of an intra-aortic balloon pump (IABP). But unlike IABP, EECP therapy also increases venous return (Fig. 1). A full course of therapy typically consists of 35 sessions of one hour per day.

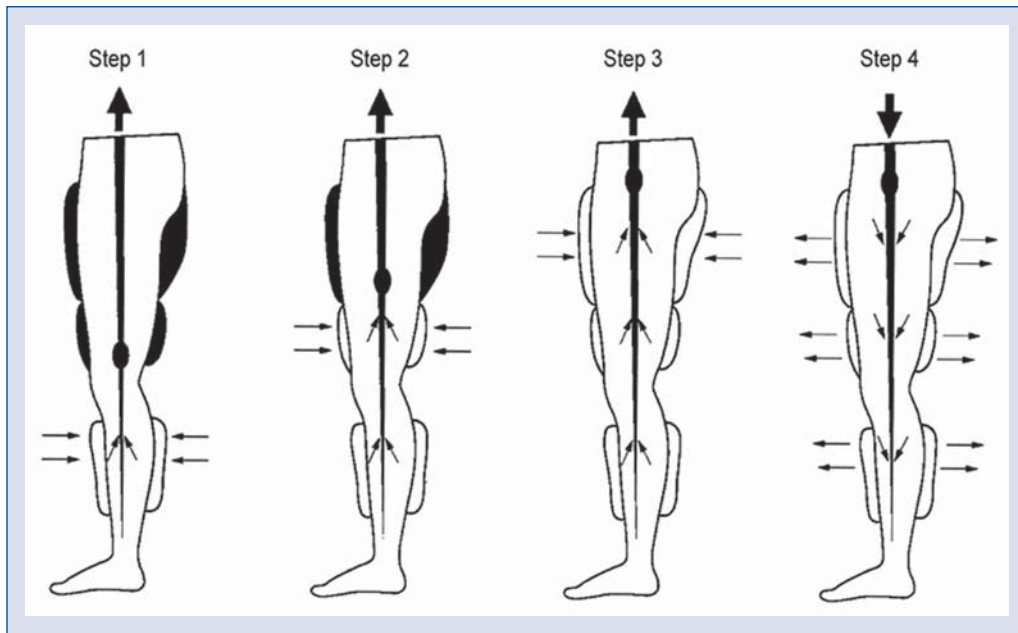
The benefits associated with EECP therapy include reduction of angina and nitrate use, increased exercise tolerance, favorable psychosocial effects and enhanced quality of life, prolongation of the time to exercise-induced ST-segment depression, and an accompanying resolution of myocardial perfusion defects.

Recent evidence suggests that EECP therapy may improve symptoms and decrease long-term morbidity via more than one mechanism including improvement in endothelial function, promotion of collateralization, enhancement of ventricular function, improvement in oxygen consumption ( $VO_2$ ), regression of atherosclerosis, and peripheral training effects similar to exercise [22]. Numerous clinical trials over the last 20 years have shown EECP therapy to be safe and effective for patients with RAP, with a clinical response rate averaging 70–80% (Table 3 [23–27]) which is sustained for up to five years [28]. It is not only safe in patients with co-existing heart failure, but has also been shown to improve quality of life and exercise capacity and to improve long-term left ventricular function [27, 29, 30]. Side effects include leg or waist pain, skin abrasion/ecchymoses, bruises in patients using coumadin with unadjusted coagulation, paresthesias and worsening heart failure in patients with severe arrhythmias.

EECP is a treatment modality approved by the FDA. EECP has a class IIb indication for treatment of RAP as per the 2002 ACC/AHA guidelines. However, since 2002, there has been significant accumulation of clinical data supporting EECP therapy for positioning in the professional treatment guidelines with a class IIa rating. This may be the case in the upcoming ACC/AHA guidelines.

### Neurostimulatory techniques

**Transcutaneous electrical nerve stimulation** (TENS) therapy can ameliorate symptoms in chronic refractory angina. Essentially, TENS involves applying a low voltage electrical current via pads placed on the skin in the area of pain. The technique primarily works via the Gate Control Theory of Pain. Stimulating large diameter afferent fibers inhibits input from small diameter fibers in the substantia gelatinosa of the spinal cord [31]. Another



**Figure 1.** Three pairs of pneumatic cuffs are applied to the calves, lower thighs, and upper thighs. The cuffs are inflated sequentially during diastole, distal to proximal. The compression of the lower-extremity vascular bed increases diastolic pressure and flow and increases venous return. The pressure is then released at the onset of systole. Inflation and deflation are timed according to the R-wave on the patient’s cardiac monitor. The pressures applied and the inflation–deflation timing can be altered by using the pressure waveforms and electrocardiogram on the enhanced external counterpulsation therapy monitor.

**Table 3.** List of trials.

Authors (reference)	Year	N	Follow-up duration	Angina relief (%)	Nitro use (frequency)	Exercise capacity (%)	SPECT thallium imaging
<b>Various trials of EECp therapy in patients with refractory angina</b>							
Lawson et al. [23]	1996	50	35 weeks*	↓ (100%)	↓	NA	↑ (80%)
Arora et al. [24]	1999	139	35 weeks*	↓	↓	↑	NA
Barnes et al. [25]	2001	978	35 weeks*	↓ (81%)	↓	NA	↑ (83%)
Fitzgerald et al. [26]	2003	4454	35 weeks*	↓	↓	NA	NA
Soran et al. [27]	2006	363	35 weeks*	↓ (72%)	↓ (52%)	NA	NA
<b>Randomized trials of spinal cord stimulation in patients with refractory angina</b>							
Mannheimer et al. [38]	1998	104	NA	↓	↓	NA	NA
Hautvast et al. [39]	1998	25	NA	↓ (41%)	↓ (48%)	↑ (19%)	NA
Greco et al. [40]	1999	517	NA	NA	NA	NA	NA
Di Pede et al. [41]	2003	104	NA	↓ (73%)	NA	NA	NA
<b>Published trials of laser revascularization in patients with refractory angina</b>							
Schofield et al. [43]	1999	79	12 weeks	↓**	↓	No change	NA
Allen et al. [44]	1999	178	120 days	↓**	↓	↑	Unchanged
Burkhoff et al. [45]	1999	79	12 weeks	↓**	↓	↑	Unchanged

\*35 week treatment session; \*\*with associated increase in QOL score; ↓ decrease; EECp — enhanced external counterpulsation; ↑ increase; NA — not applicable

commonly held theory for the mechanism of action of low-frequency TENS is activation of endogenous opioid pathways. Interestingly, the effect of low frequency (not high frequency) TENS is reversible by

naloxone (an opioid antagonist) [32]. Other mechanisms, such as increased endorphin concentration in blood and cerebrospinal fluid, have also been proposed [33]. A study by Sanderson [34] showed

a significant improvement in symptoms and use of nitroglycerine in a study of 14 patients with RAP. They demonstrated an increase in the exercise duration from a mean of 414 ms to 478 ms and a significant reduction in total ST segment depression at maximum exercise and 90% controlled HR.

Mannheimer et al. [35] investigated the effects of TENS with respect to systemic and coronary hemodynamics and myocardial metabolism in pacing induced angina in a controlled long-term study. In patients with pacing induced angina, they demonstrated an increased tolerance to pacing ( $142 \pm 23$  compared to  $124 \pm 20$  beats/min tolerated;  $p < 0.001$ ), improved lactate metabolism ( $2 \pm 36\%$  compared to  $-18 \pm 43\%$ ;  $p < 0.01$ ) and less pronounced ST segment depression ( $2.3 \pm 1.1$  compared to  $2.9 \pm 2.6$  mm;  $p < 0.05$ ) with TENS [35]. The benefits of TENS are that it is a passive, non-invasive, non-addictive modality with no potentially harmful side effects.

TENS is currently not approved by the FDA for the treatment of RAP.

**Spinal cord stimulation (SCS)** is another neurostimulatory technique. It is believed that SCS blocks pain by stimulating the dorsal columns, which inhibits transmission through the pain-conducting spinothalamic tract [36, 37]. Clinical trials have investigated the use of SCS for RAP (Table 3 [38–41]). A systematic review by Taylor et al. [42] that looked at seven randomized controlled trials evaluating 270 patients, demonstrated SCS to be an effective and safe treatment option for RAP compared to coronary artery bypass grafting and percutaneous transmyocardial laser revascularization (PTMLR). Possible benefits include the ease of use and portability of the device that allows patients to resume activities at home or at work. The main adverse reactions to SCS are the risk of epidural hematoma and infection, occurring in about 1% of patients. SCS may interfere with the function of pacemakers and implantable defibrillators by possible false inhibition of the pacemaker function, but this risk may be lowered if caution is exercised, such as programming both devices in bipolar mode, setting the stimulator frequency to 20 Hz, and performing the SCS programming under continuous cardiac monitoring.

SCS is not FDA-approved for RAP treatment, but has a class IIb indication for treatment of refractory angina as per ACC/AHA guidelines.

### Laser revascularization techniques

**Transmyocardial laser revascularization (TMR/TMLR)** has emerged as a novel invasive

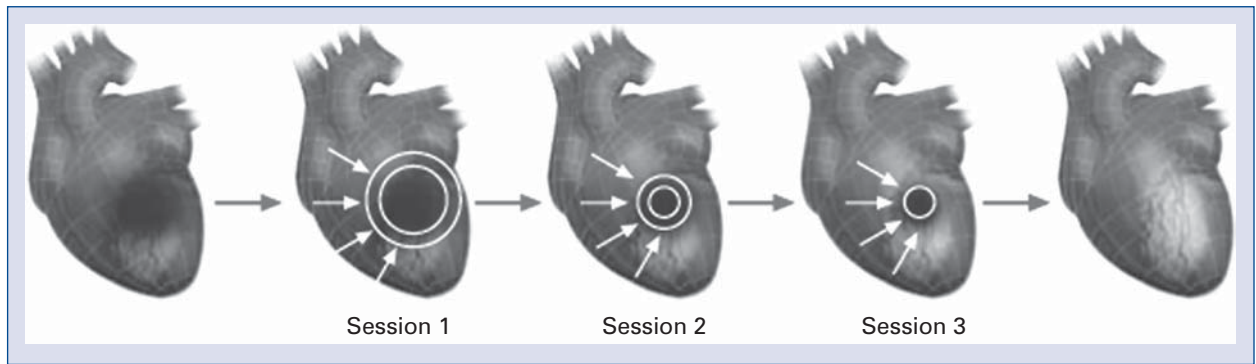
treatment for RAP over the last two decades [43]. In this procedure, 20 to 40 transmural channels are created using a high-energy carbon dioxide laser with brief manual compression of the epicardial surface to allow for closure of the epicardial opening sites. Its mechanism of action was initially thought to be direct perfusion of the myocardium with the left ventricular blood via these endocardial channels (replicating reptilian circulation). However, early closure of these channels, and histopathological studies demonstrating the absence of true communication between the epicardial channels and the endocardial cavity, suggest that this hypothesis was wrong. It is now thought that the laser may stimulate angiogenesis and may destroy nerve fibers to the heart, making patients numb to their chest pain. Multiple randomized prospective controlled surgical trials have assessed the safety and efficacy of TMLR in patients with RAP (Table 3 [43–45]).

Although found to be efficacious in 80% of patients short-term, there is limited follow-up data to assess long-term efficacy and freedom from angina. Although investigated initially as a sole therapy for RAP, it is today mostly used in conjunction with coronary bypass grafting.

TMR is not approved by the FDA, but has received class IIa indication for RAP treatment by the ACC/AHA.

### Percutaneous transmyocardial laser revascularization

TMR is now being performed percutaneously, using the less invasive catheter-based approach percutaneous transmyocardial laser revascularization (PTMLR). Oesterle et al. [46] reported the Potential Angina Class Improvement From Intramyocardial Channels (PACIFIC) trial, a multicenter, randomized study comparing PTMLR in addition to medical therapy *versus* medical therapy alone in 221 patients with CCS class III or IV RAP. At 12 months, exercise tolerance significantly increased in the PTMLR group, as did anginal class scores and quality-of-life measurements. However, there was no significant difference in overall mortality. A similar trial by Whitlow et al. [47] compared PTMLR plus medical therapy to medical therapy alone in 330 patients with CCS class II, III or IV RAP. After 12 months, there was a significant improvement in anginal class scores, exercise tolerance and quality-of-life measures. Again, there was no difference in one-year survival between the groups. The results of the DMR In Regeneration of Endomyocardial Channels Trial (DIRECT) led by



**Figure 2.** Treatment strategy: at each treatment session, shockwaves are delivered to the border of the ischemic area. Reproduced with the permission of Gil Hakim of Medispec Ltd.

Leon [48] tempered the initial enthusiasm surrounding myocardial laser therapy. This randomized, placebo-controlled, prospective trial enrolled 298 patients into three treatment arms: placebo PTMLR procedure, low-dose PTMLR (10 to 15 channels created), or high-dose PTMLR (20 to 25 channels created). The results were very similar for treatment arms representing a large ‘placebo effect’ [48]. PTMLR, although popular in the 1990s, has seen a marked decrease in enthusiasm recently due to this large placebo effect.

#### Latest techniques under investigation

**Extracorporeal shockwave myocardial revascularization (ESMR)** — this technology uses low-intensity shockwaves (SW) (one tenth the strength of those used in lithotripsy) that are delivered to myocardial ischemic tissue. Shockwaves, created by a special generator, are focused using a shockwave applicator device. The treatment is guided by standard echocardiography equipment. The shockwaves are delivered in synchronization with the patient’s R-wave to avoid arrhythmias. At first, the patient undergoes stress SPECT testing to identify the ischemic areas. Following that, the same area is localized by the ultrasound device and the shockwaves are focused to the ischemic area (Fig. 2). Several treatments are required for optimal results.

SW therapy has been demonstrated to induce localized stress on cell membranes, and to cause non-enzymatic nitric oxide synthesis from L-arginine and hydrogen peroxide [49]. In pigs, SW therapy has been shown to upregulate vascular endothelial growth factor (VEGF) and its receptor, Flt-1, in endothelial cells *in vitro* and VEGF in the ischemic myocardium *in vivo* [50] which is essential in initiating vasculogenesis and/or angiogenesis. Fuku-

moto et al. [51] demonstrated in a small study of nine patients with RAP the use of SW therapy. It improved symptoms, functional class score (CCS) and reduced nitroglycerine use. The treatment also improved myocardial perfusion as assessed by dipyridamole stress thallium scintigraphy. SW therapy has been reported to reduce the frequency and severity of anginal symptoms and to improve exercise tolerance and quality of life [51]. If necessary, SW therapy can repeatedly be used to treat patients. Uwatoku et al. [52] demonstrated the suppression of left ventricular remodeling after acute MI without adverse effects by using SW therapy in an animal model. This technique is under investigation and there is a need for more studies, especially prospective randomized studies, to investigate the effect of SW therapy in patients with RAP.

SW therapy is not yet FDA-approved for the management and treatment of patients with RAP.

#### Conclusions

As the mortality from CAD decreases, and the population ages, an increasing number of patients will be diagnosed with RAP. This is a problem that has already attracted the attention of epidemiologists and provoked interest from researchers and scientists in investigating new therapies. In the light of current evidence, ranolazine and enhanced external counterpulsation therapy have emerged as more widely accepted modalities in the management of patients with RAP.

A multi-disciplinary approach to the care of these patients will bring better angina relief and improved quality of life. There is a strong need for investigators and physicians who can combine these new treatment modalities to reach the treatment goals for patients with RAP.

## Acknowledgements

The authors do not report any conflict of interest regarding this work.

## References

1. Soran O. Treatment options for refractory angina pectoris: Enhanced external counterpulsation therapy. *Curr Treat Options Cardiovasc Med*, 2009; 11: 54–60.
2. Manchanda A, Soran O. Enhanced external counterpulsation and future directions: Step beyond medical management for patients with angina and heart failure. *J Am Coll Cardiol*, 2007; 50: 1523–1531.
3. Boden WE, O'Rourke RA, Teo KK et al.; COURAGE Trial Research Group. Optimal medical therapy with or without PCI for stable coronary disease. *N Engl J Med*, 2007; 356: 1503–1516.
4. Fraser H, Belardinelli L, Wang L, Light PE, McVeigh JJ, Clanachan AS. Ranolazine decreases diastolic calcium accumulation caused by ATX-II or ischemia in rat hearts. *J Mol Cell Cardiol*, 2006; 41: 1031–1038.
5. Morrow DA, Scirica BM, Karwowska-Prokopczuk E et al.; MERLIN-TIMI 36 Trial Investigators. Effects of ranolazine on recurrent cardiovascular events in patients with non-ST-elevation acute coronary syndromes: The MERLIN-TIMI 36 randomized trial. *JAMA*, 2007; 297: 1775–1783.
6. Borer JS, Heuzey JY. Characterization of the heart rate-lowering action of ivabradine, a selective I(f) current inhibitor. *Am J Ther*, 2008; 15: 461–473.
7. Borer JS, Fox K, Jaillon P, Lerebours G; Ivabradine Investigators Group. Antianginal and antiischemic effects of ivabradine, an I(f) inhibitor, in stable angina: A randomized, double-blind, multicentered, placebo-controlled trial. *Circulation*, 2003; 107: 817–823.
8. Ferrari R, Ford I, Fox K, Steg PG, Tendera M; Beautiful Study Group. The BEAUTIFUL study: Randomized trial of ivabradine in patients with stable coronary artery disease and left ventricular systolic dysfunction: Baseline characteristics of the study population. *Cardiology*, 2008; 110: 271–282.
9. Markham A, Plosker GL, Goa KL. Nicorandil. An updated review of its use in ischaemic heart disease with emphasis on its cardioprotective effects. *Drugs*, 2000; 60: 955–974.
10. Raftery EB, Lahiri A, Hughes LO, Rose EL. A double-blind comparison of a beta-blocker and a potassium channel opener in exercise induced angina. *Eur Heart J*, 1993; 14 (suppl. B): 35–39.
11. Di Somma S, Liguori V, Petitto M et al. A double-blind comparison of nicorandil and metoprolol in stable effort angina pectoris. *Cardiovasc Drugs Ther*, 1993; 7: 119–123.
12. IONA Study Group. Effect of nicorandil on coronary events in patients with stable angina: The Impact Of Nicorandil in Angina (IONA) randomised trial. *Lancet*, 2002; 359: 1269–1275.
13. Zhu WL, Shan YD, Guo JX et al. Double-blind, multicenter, active-controlled, randomized clinical trial to assess the safety and efficacy of orally administered nicorandil in patients with stable angina pectoris in China. *Circ J*, 2007; 71: 826–833.
14. Guan W, Osanai T, Kamada T et al. Effect of allopurinol pretreatment on free radical generation after primary coronary angioplasty for acute myocardial infarction. *J Cardiovasc Pharmacol*, 2003; 41: 699–705.
15. Johnson WD, Kayser KL, Brenowitz JB, Saedi SF. A randomized controlled trial of allopurinol in coronary bypass surgery. *Am Heart J*, 1991; 121: 20–24.
16. Kaliakin IE, Mit'kin AF. Effects of allopurinol on uric acid metabolism and lipid peroxidation in ischemic heart disease patients with stable angina. *Kardiologia*, 1993; 33: 15–17.
17. Coghlan JG, Flitter WD, Clutton SM et al. Allopurinol pretreatment improves postoperative recovery and reduces lipid peroxidation in patients undergoing coronary artery bypass grafting. *J Thorac Cardiovasc Surg*, 1994; 107: 248–256.
18. Nishizawa J, Nakai A, Matsuda K, Komeda M, Ban T, Nagata K. Reactive oxygen species play an important role in the activation of heat shock factor 1 in ischemic-reperfused heart. *Circulation*, 1999; 99: 934–941.
19. Perez NG, Gao WD, Marban E. Novel myofilament Ca<sup>2+</sup>-sensitizing property of xanthine oxidase inhibitors. *Circ Res*, 1998; 83: 423–430.
20. Qayumi AK, Godin DV, Jamieson WR, Ko KM, Poostizadeh A. Correlation of red cell antioxidant status and heart-lung function in swine pretreated with allopurinol (a model of heart-lung transplantation). *Transplantation*, 1993; 56: 37–43.
21. Noman A, Ang DS, Ogston S, Lang CC, Struthers AD. Effect of high-dose allopurinol on exercise in patients with chronic stable angina: A randomised, placebo controlled crossover trial. *Lancet*, 2010; 375: 2161–2167.
22. Bonetti PO, Barsness GW, Keelan PC et al. Enhanced external counterpulsation improves endothelial function in patients with symptomatic coronary artery disease. *J Am Coll Cardiol*, 2003; 41: 1761–1768.
23. Lawson WE, Hui JC, Zheng ZS et al. Improved exercise tolerance following enhanced external counterpulsation: Cardiac or peripheral effect? *Cardiology*, 1996; 87: 271–275.
24. Arora RR, Chou TM, Jain D et al. The multicenter study of enhanced external counterpulsation (MUST-EECP): Effect of EECP on exercise-induced myocardial ischemia and anginal episodes. *J Am Coll Cardiol*, 1999; 33: 1833–1840.
25. Barsness G, Feldman AM, Holmes DR, Jr, Holubkov R, Kelsey SF, Kennard ED, International EECP Patient Registry Investigators. The International EECP Patient Registry (IEPR): Design, methods, baseline characteristics, and acute results. *Clin Cardiol*, 2001; 24: 435–442.
26. Fitzgerald CP, Lawson WE, Hui JC, Kennard ED; IEPR Investigators. Enhanced external counterpulsation as initial revascularization treatment for angina refractory to medical therapy. *Cardiology*, 2003; 100: 129–135.
27. Soran O, Kennard ED, Kfoury AG, Kelsey SF; IEPR Investigators. Two-year clinical outcomes after enhanced external counterpulsation (EECP) therapy in patients with refractory angina pectoris and left ventricular dysfunction (report from the International EECP Patient Registry). *Am J Cardiol*, 2006; 97: 17–20.
28. Lawson WE, Hui JC, Kennard ED, Kelsey SF, Michaels AD, Soran O; International Enhanced External Counterpulsation Patient Registry Investigators. Two-year outcomes in patients with mild refractory angina treated with enhanced external counterpulsation. *Clin Cardiol*, 2006; 29: 69–73.
29. Soran O, De Lame PA, Fleishman B, Grossman W, Feldman AM. Enhanced external counterpulsation in patients with heart failure: A multi-center feasibility study. *Congest Heart Fail*, 2002; 8: 204–208.
30. Soran O, Kennard ED, Kelsey SF, Holubkov R, Strobeck J, Feldman AM. Enhanced external counterpulsation as treatment for chronic angina in patients with left ventricular dysfunction: A report from the International EECP Patient Registry (IEPR). *Congest Heart Fail*, 2002; 8: 297–302.



31. Melzack R, Wall PD. Pain mechanisms: A new theory. *Science*, 1965; 150: 971–979.
32. Sjolund BH, Eriksson MB. The influence of naloxone on analgesia produced by peripheral conditioning stimulation. *Brain Res*, 1979; 173: 295–301.
33. Hughes GS, Jr, Lichstein PR, Whitlock D, Harker C. Response of plasma beta-endorphins to transcutaneous electrical nerve stimulation in healthy subjects. *Phys Ther*, 1984; 64: 1062–1066.
34. Sanderson JE. Electrical neurostimulators for pain relief in angina. *Br Heart J*, 1990; 63: 141–143.
35. Mannheimer C, Carlsson CA, Emanuelsson H, Vedin A, Waagstein F, Wilhelmsson C. The effects of transcutaneous electrical nerve stimulation in patients with severe angina pectoris. *Circulation*, 1985; 71: 308–316.
36. Mannheimer C, Eliasson T, Andersson B et al. Effects of spinal cord stimulation in angina pectoris induced by pacing and possible mechanisms of action. *BMJ*, 1993; 307: 477–480.
37. Hautvast RW, Blanksma PK, DeJongste MJ et al. Effect of spinal cord stimulation on myocardial blood flow assessed by positron emission tomography in patients with refractory angina pectoris. *Am J Cardiol*, 1996; 77: 462–467.
38. Mannheimer C, Eliasson T, Augustinsson LE et al. Electrical stimulation versus coronary artery bypass surgery in severe angina pectoris: The ESBY study. *Circulation*, 1998; 97: 1157–1163.
39. Hautvast RW, Brouwer J, DeJongste MJ, Lie KI. Effect of spinal cord stimulation on heart rate variability and myocardial ischemia in patients with chronic intractable angina pectoris: A prospective ambulatory electrocardiographic study. *Clin Cardiol*, 1998; 21: 33–38.
40. Greco S, Auriti A, Fiume D et al. Spinal cord stimulation for the treatment of refractory angina pectoris: A two-year follow-up. *Pacing Clin Electrophysiol*, 1999; 22: 26–32.
41. Di Pede F, Lanza GA, Zuin G et al.; Investigators of the Prospective Italian Registry of SCS for Angina Pectoris. Immediate and long-term clinical outcome after spinal cord stimulation for refractory stable angina pectoris. *Am J Cardiol*, 2003; 91: 951–955.
42. Taylor RS, De Vries J, Buchser E, Dejongste MJ. Spinal cord stimulation in the treatment of refractory angina: Systematic review and meta-analysis of randomised controlled trials. *BMC Cardiovasc Disord*, 2009; 9: 13.
43. Schofield PM, Sharples LD, Caine N et al. Transmyocardial laser revascularisation in patients with refractory angina: A randomised controlled trial. *Lancet*, 1999; 353: 519–524.
44. Allen KB, Dowling RD, Fudge TL et al. Comparison of transmyocardial revascularization with medical therapy in patients with refractory angina. *N Engl J Med*, 1999; 341: 1029–1036.
45. Burkhoff D, Schmidt S, Schulman SP et al. Transmyocardial laser revascularisation compared with continued medical therapy for treatment of refractory angina pectoris: A prospective randomised trial. ATLANTIC Investigators. *Angina Treatments-Lasers and Normal Therapies in Comparison*. *Lancet*, 1999; 354: 885–890.
46. Oesterle SN, Sanborn TA, Ali N et al. Percutaneous transmyocardial laser revascularisation for severe angina: The PACIFIC randomised trial. Potential Class Improvement From Intramyocardial Channels. *Lancet*, 2000; 356: 1705–1710.
47. Whitlow PL, DeMaio SJ, Perin EC et al. One-year results of percutaneous myocardial revascularization for refractory angina pectoris. *Am J Cardiol*, 2003; 91: 1342–1346.
48. Leon M. DIRECT trial: Late breaking trials. Presented at: Transcatheter Therapeutics, October 20, 2000, Washington, DC, 2000.
49. Gotte G, Amelio E, Russo S, Marlinghaus E, Musci G, Suzuki H. Short-time non-enzymatic nitric oxide synthesis from L-arginine and hydrogen peroxide induced by shock waves treatment. *FEBS Lett*, 2002; 520: 153–155.
50. Nishida T, Shimokawa H, Oi K et al. Extracorporeal cardiac shock wave therapy markedly ameliorates ischemia-induced myocardial dysfunction in pigs in vivo. *Circulation*, 2004; 110: 3055–3061.
51. Fukumoto Y, Ito A, Uwatoku T et al. Extracorporeal cardiac shock wave therapy ameliorates myocardial ischemia in patients with severe coronary artery disease. *Coron Artery Dis*, 2006; 17: 63–70.
52. Uwatoku T, Ito K, Abe K et al. Extracorporeal cardiac shock wave therapy improves left ventricular remodeling after acute myocardial infarction in pigs. *Coron Artery Dis*, 2007; 18: 397–404.