

# Propofol infusion syndrome and Brugada syndrome electrocardiographic phenocopy

Andrés Ricardo Pérez Riera<sup>1</sup>, Augusto Hiroshi Uchida<sup>2</sup>, Edgardo Schapachnik<sup>3</sup>, Sergio Dubner<sup>4</sup>, Celso Ferreira Filho<sup>1</sup>, Celso Ferreira<sup>1</sup>

<sup>1</sup>ABC Medical Faculty, ABC Foundation. Santo André, São Paulo. Brazil

<sup>2</sup>Electrocardiology Service of the Heart Institute (Incor),  
University of São Paulo Medical School, São Paulo, Brazil

<sup>3</sup>Department of Chagas Disease of the Dr. Cosme Argerich Hospital, Buenos Aires, Argentina

<sup>4</sup>Arrhythmias and Electrophysiology Service, Clinical and Maternidad Suizo Argentina,  
Buenos Aires, Argentina

## Abstract

*This anesthetic drug may cause a rare condition named propofol infusion syndrome, characterized by unexplained lactic acidosis, lipemia, rhabdomyolysis, cardiovascular collapse and Brugada-like electrocardiographic pattern or Brugada electrocardiographic phenocopy changes following high-dose propofol infusion over prolonged periods of time.*

*Several articles have contributed to our understanding of the cause of the syndrome, and the growing number of case reports has made it possible to identify several risk factors. Uncertainty remains as to whether a genetic susceptibility exists.*

*The favorable recovery profile associated with propofol offers advantages over traditional anesthetics in clinical situations in which rapid recovery is important. Propofol is a safe anesthetic agent, but propofol infusion syndrome is a rare lethal complication. (Cardiol J 2010; 17, 2: 130–135)*

**Key words: propofol mechanisms, indications, phenocopies, adverse effects, Brugada electrocardiographic-like pattern,**

## Introduction

Propofol (2,6-diisopropylphenol, INN, brand name: Diprivan by AstraZeneca) is a short-acting, intravenously administered sedative-hypnotic, and antiepileptic agent with anesthetic properties unrelated to barbiturates. It is also a reliable, safe and prompt anesthetic agent when used during induced cardiovascular and pulmonary-impaired conditions without surgery, or to induce anesthesia prior to inhalant anesthesia with and without surgery. The

favorable recovery profile associated with propofol offers advantages over traditional anesthetics in clinical situations in which rapid recovery is important. This drug has largely replaced sodium thiopental (Pentothal) for induction of anesthesia, as recovery from propofol is more rapid and 'clear' as compared to thiopental. Additionally, the drug has antioxidant properties (propofol-nitrous oxide) secondary to its phenol-based chemical structure. In elderly patients, compared to isoflurane, propofol intravenous anesthesia is associated with rapid

**Address for correspondence:** Andrés Ricardo Pérez Riera, MD, Rua Sebastião Afonso, 885-Jd. Miriam 04417-100, São Paulo, Brazil, tel: +55 11 5621 2390, fax: +55 11 5625 7278/5506 0398, e-mail: riera@uol.com.br

Received: 30.09.2009

Accepted: 30.10.2009

recovery of the cognitive function, stable surgical stress response, and reduced adverse effects [1]. Propofol is also being increasingly used for sedation.

Treatment with propofol has been found to attenuate oxidative stress and prevent ischemia/reperfusion injury in rat hearts. Propofol protects cardiac H9c2 cells from hydrogen peroxide (H<sub>2</sub>O<sub>2</sub>)-induced injury by triggering the activation of Akt and a parallel up-regulation of Bcl-2. Pretreatment with propofol significantly protects against H<sub>2</sub>O<sub>2</sub>-induced injury. Propofol activates the PI3K-Akt signaling pathway. The protective effect of propofol on H<sub>2</sub>O<sub>2</sub>-induced injury is reversed by the PI3K inhibitor wortmannin, which effectively suppresses propofol-induced activation of Akt, up-regulation of Bcl-2, and protection from apoptosis. There is a new mechanism by which propofol inhibits H<sub>2</sub>O<sub>2</sub>-induced injury in cardiac H9c2 cells, supporting a potential application of propofol as a pre-emptive cardioprotectant in clinical settings such as that during coronary bypass surgery [2]. Mitochondrial NADH oxidase is a key enzyme involved in ischemia-reperfusion-induced oxidant generation, and it is suggested it can be a possible target in cardioprotective strategies against ischemia-reperfusion injury, a condition of great importance in human pathology [3]. Studies have pointed out the involvement of the basal forebrain gamma-aminobutyric acid-mediated system in mediating the effects of general anesthesia. In a study, Laalou et al. [4] asked whether the basal forebrain cholinergic system is also involved in mediating the effects of general anesthetics such as propofol. The anesthetic potency of propofol was increased in all rats with hippocampal lesions, whatever the injection sites, compared with controls. These results demonstrate that a cholinergic dysfunction in the basal forebrain potentiates the anesthetic effects of propofol.

Ketamine, propofol, and etomidate, with anesthetic doses, denoted efficacious effects on ischemia-reperfusion injury (IRI); hence the drugs might be preferred in certain operations with the risk of IRI [5].

Propofol is used to induce anesthesia during a cardiac ablation procedure.

The drug's uses include general anesthesia, sedation for mechanically ventilated adults, procedural sedation and in patients with refractory status epilepticus [6]. Bandschapp et al. [7] investigated the *in vitro* effects of various anesthetic agents on pharmacologically induced chloride channel myotonia. *In vitro* data implies that propofol administration for general anesthesia may be better suited

**Table 1.** Main adverse effects of propofol.

Hypotension
Local pain on injection
Transient apnea
Profound sedation with small doses
Mild myoclonic movements
Seizures
Mild euphoria
Hallucinations
Sexual disinhibition
Mitochondrial disorders
Priapism
Status dystonicus
Propofol infusion syndrome

to patients with chloride channel myotonia rather than volatile anesthetics. In isolated swine skeletal muscle bundles, propofol elicited a reversal of 9-anthracenecarboxylic acid-induced chloride channel myotonia, whereas volatile anesthetics further increased the associated myotonic reactions.

Propofol is also commonly used in veterinary medicine and can be safely and effectively used for the induction and maintenance of anesthesia in normal healthy dogs and cats [8].

Propofol is approved for use in more than 50 countries, and generic versions are available.

Table 1 shows the main adverse effects.

- 1. Low blood pressure (mainly through vasodilatation).** In hypovolemic patients and those with limited cardiac reserve, even small induction doses of propofol (0.75–1.5 mg/kg IV) can produce profound hypotension [9]. Propofol induces endothelial nitric oxide synthase phosphorylation and activation in human umbilical vein endothelial cells by inhibiting protein kinase C delta expression. Propofol induces eNOS activation through a PKC delta inhibition-dependent, protein phosphatase 2A-co-ordinated, but phosphoinositide 3-kinase/Akt-independent, pathway.
- 2. Pain on injection.** Especially in smaller veins, pain is very frequent. This pain can be mitigated by pre-treatment. Paracetamol 1 mg/kg and lidocaine 0.5 mg/kg were equally effective in attenuating pain during intravenous (IV) injection of propofol; whereas pre-treatment with paracetamol 2 mg/kg was shown to be the most effective treatment [10].
- 3. Transient apnea following induction doses.** Dexmedetomidine provided an acceptable le-

vel of anesthesia for magnetic resonance imaging (MRI) sleep studies in children with obstructive sleep apnea (OSA), producing a high yield of interpretable studies of the patient's native airway. The need for artificial airway support during the MRI sleep study was significantly less with dexmedetomidine than with propofol. Dexmedetomidine may be the preferred drug for anesthesia during MRI sleep studies in children with a history of severe OSA, and may offer benefits to children with sleep-disordered breathing requiring anesthesia or anesthesia for other diagnostic imaging studies [11].

4. **Profound sedation with small doses.** Reproducible automated responsiveness monitor (ARM) dynamics in individual subjects compares favorably with clinical and electroencephalogram sedation end points, and suggests that the ARM could be used as an independent instrumental guide of drug effect during propofol-only sedation [12].
5. **Mild myoclonic movements** are common, as with other intravenous hypnotic agents [13].
6. **Seizures during intravenous propofol anesthesia** [14].
7. **Euphoria (mild), hallucinations, and sexual disinhibition.** Hedonic and rewarding states like these are modulated by the dopaminergic system in the nucleus accumbens, prefrontal cortex and also in the ventral pallidum and by the glutamatergic system in the neocortex and limbic system. Application of propofol decreased dopamine levels in the ventral pallidum. This effect seems to be mainly mediated through GABAA receptors, since it was compensated by the GABAA receptor antagonist bicuculline. Propofol and propofol plus bicuculline exerted no effect on glutamate release in this brain region. The reduced dopamine release in ventral pallidum was most probably mediated through a GABAergic feedback loop from the ventral pallidum via the nucleus accumbens to the dopaminergic neurons of the ventral tegmental area or by long loop feedback. As an increase rather than a decrease of dopamine release in the ventral pallidum is involved in hedonic and rewarding properties, similar symptoms induced by propofol seem to be unrelated to an action of propofol in the ventral pallidum [15].
8. **Mitochondrial disorders encompass** a group of syndromes produced by genetic defects that disrupt mitochondrial energy production. The impaired mitochondrial energy supply affects nearly all organs and tissues leading to

a variable clinical presentation. The possible multisystem involvement complicates the management of anesthesia and perioperative care. Exact knowledge of the path physiology of mitochondrial diseases may help to avoid perioperative anesthesiological complications. Drugs which more frequently than in the general population cause side effects in patients with mitochondrial disorders include steroids, propofol, statins, fibrates, neuroleptics, and anti-retroviral agents [16].

9. **Priapism induction in some individuals** [17].
10. **Addiction.** Such use of the drug has been described among medical staff such as anesthesiologists who have access to it [18, 19].
11. **Dystonia or status dystonicus.** It is a rare and severe threatening disorder that develops in patients with both primary and secondary dystonia, characterized by acute worsening of symptoms with generalized and severe muscle contractions [20]. Chronic posthypoxic myoclonus, also known as Lance-Adams syndrome, is a rare and devastating complication of near-fatal cardiopulmonary arrest (successful cardiopulmonary resuscitation), often accompanied by action myoclonus and cerebellar ataxia. It is characterized by intention myoclonus but preserved intellect. Despite treatment with available anti-myoclonic agents, some patients may recover cognitively but remain completely disabled by severe myoclonus. It is seen in patients who have undergone a cardiorespiratory arrest, regained consciousness afterwards, and then developed myoclonus days or weeks after the event. Accurate distinction between myoclonic status epilepticus and Lance-Adams syndrome is vital, as they have very different prognoses. The different pathophysiologies and distinguishing clinical features of these two conditions are highlighted [21, 22].
12. **Propofol infusion syndrome.** This is a rare condition characterized by the occurrence of unexplained lactic acidosis, lipemia, rhabdomyolysis, cardiovascular collapse, and acquired Brugada-like electrocardiographic (ECG) changes following high-dose propofol infusion over prolonged periods of time [23]. An acquired Brugada-like ECG pattern, or Brugada syndrome phenocopy in severely head-injured patients, is a sign of cardiac electrical instability that predicts imminent cardiac death [24, 25]. Additionally, Brugada-like ECG pattern could be caused by secondary severe hyperkalemia. In a 48 year-old man after short-term infusion

of an average dose of propofol, Mali et al. [26] suspected that the hyperkalemia was a sign of propofol infusion syndrome. The patient was undergoing a video-assisted esophagectomy, for which one-lung ventilation, with air/oxygen, isoflurane, and continuous epidural analgesia was supplemented with propofol infusion. In the intraoperative period, the patient developed severe hyperkalemia with mild acidosis but no cardiovascular failure. There were no other evident causes of hyperkalemia as documented by laboratory data. The procedure was abandoned and the patient was taken to post-operative recovery, where his potassium levels returned to normal after ten hours. Dramatic cardiac conduction disturbances, prolonged QT interval, idioventricular rhythm, tachyarrhythmias, and ventricular fibrillation are observed in the setting of only mild metabolic acidosis and a good ventricular function is possible [27].

At the basis of the syndrome lies an imbalance between energy utilization and demand, resulting in cell dysfunction and ultimately necrosis of cardiac and peripheral muscle cells. In symptomatic patients with Brugada syndrome (syncope or sudden death recovered) with positive pilsicainide challenge test, routine monitors, right precordial lead of the ECG, and an external defibrillator were installed by Inamura et al. [28] prior to anesthesia. The authors administered propofol/midazolam for induction, and propofol/sevoflurane combined with fentanyl for maintenance of anesthesia. Atropine and ephedrine were administered to decrease vagal tone. No ECG change or arrhythmia was observed perioperatively in six patients studied. Several new case reports and reviews, as well as a number of experiments, have contributed significantly to our increased understanding of the cause of the syndrome. Uncertainty remains as to whether a genetic susceptibility exists. Nonetheless, the growing number of case reports has made it possible to identify several risk factors. Propofol infusion syndrome is a rare but frequently lethal complication of propofol use.

### Possible etiologies of propofol infusion syndrome

Table 2 summarizes the possible etiologies of propofol infusion syndrome.

Long-term propofol abuse for recreational purposes has been mentioned in literature. In a case report, a strong positive reaction for tumor necrosis factor alpha in cardiac myocytes and a diffuse apoptotic process in the heart specimens and mul-

**Table 2.** Possible etiologies of propofol infusion syndrome.

Traumatic brain injury: these patients are particularly at risk of developing this complication because large doses of propofol are commonly used to control intracranial pressure (infusion rate of $\leq 4$ mg/kg per hour), whereas vasopressors are administered to augment cerebral perfusion pressure
Induction and maintenance of general anesthesia
Sedation of mechanically ventilated adults and procedural sedation
Treatment of refractory status epilepticus with high infusion rates for prolonged periods [6]

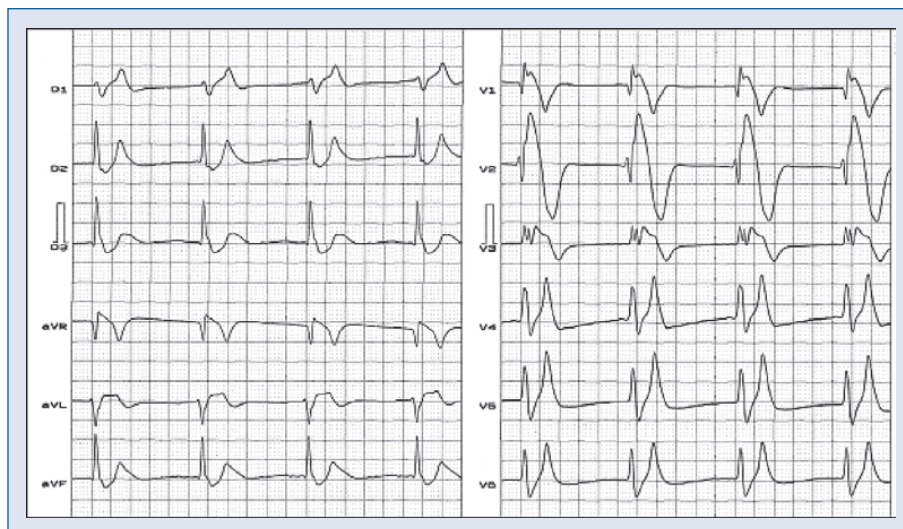
multiple needle marks on the hands and forearms, as well as a propofol concentration in the hair examined ( $0.73 \mu\text{g/g}$ ), were observed [29].

Combined with fentanyl (an opioid), propofol is used to alleviate pain [30]. It is used as sedation for mechanically ventilated adults and procedural sedation. It is associated with significant mortality and morbidity as a consequence of propofol infusion syndrome, especially at high infusion rates for prolonged periods [6].

### Discussion and conclusions

The use of propofol for extended periods, and in a high dose, may lead to the feared and rare propofol infusion syndrome. A significant mechanism is the capacity of the drug in such conditions to cause a non-traumatic form of rhabdomyolysis with a release of the breakdown products of damaged muscle cells into the bloodstream; some of these, such as myoglobin, are harmful to the kidneys and may lead to acute kidney failure. This acute renal failure may result in retention of urea and creatinin and non-nitrogenous waste products normally excreted by the kidney. Depending on the severity and duration of the renal dysfunction, this accumulation is accompanied by metabolic acidosis and hyperkalemia (elevated potassium levels), changes in body fluid balance, and effects on many other organ systems. It can be characterized by oliguria or anuria, although nonoliguric acute renal failure may occur. It is a serious disease and is treated as a medical emergency. The increase of serum potassium could be responsible for the electrocardiographic Brugada type 1 pattern.

As a consequence of infusion in high doses of propofol from the point of view of ECG, the features are ECG with upwardly convex elevation from V1 to V3 (Brugada-like ECG pattern). The development



**Figure 1.** Typical electrocardiogram of hyperpotasemia associated with Brugada-like pattern secondary to propofol infusion syndrome. **Clinical diagnosis:** terminal renal insufficiency. Hyperkalemia: 8.7 mEq/L. This sign is known as dialyzable injury current. **Electrocardiographic diagnosis:** very likely, sinus rhythm with non-visible P waves, heart rhythm: 54 bpm, QRSd: 160 ms, ST segment elevation from V1 to V3 and DI, aVL and aVR. V1 to V3 display upwardly convex ST segment pattern, similar to Brugada syndrome, which some authors call 'acquired Brugada pattern'; typical T waves in 'tent', pointed, and with a narrow base.

of this acquired form of Brugada-like syndrome is a sign of electric instability and a predictor of imminent sudden death [31]. Severe hypercalcemia may precipitate ECG Brugada-like pattern [32, 33].

Chronic renal insufficiency has been described transiently with hypercalcemia and reversed with dialysis [34]. The ECG shown in Figure 1 is a case of severe hypercalcemia with ECG Brugada-like pattern.

Lactic acidosis observed in propofol infusion syndrome is a condition characterized by lactate levels > 5 mmol/L and serum pH < 7.35. The Cohen-Woods classification categorizes causes of lactic acidosis into two types: A and B [35]:

- Type A: decreased perfusion or oxygenation;
- Type B:
  - B1: Underlying diseases (sometimes causing type A),
  - B2: Medication or intoxication,
  - B3: Inborn error of metabolism.

Probably, lactic acidosis observed in propofol infusion syndrome is a mixture of A (tissue hypoxia and hypoperfusion secondary to hypotension) and B2.

### Acknowledgements

The authors do not report any conflict of interest regarding this work.

### References

1. Tan R. Effect of propofol and isoflurane on surgical stress response and postoperative cognitive function in elderly patients. *Nan Fang Yi Ke Da Xue Xue Bao*, 2009; 29: 1247–1248.
2. Wang B, Shrivah J, Luo H et al. Propofol protects against hydrogen peroxide-induced injury in cardiac H9c2 cells via Akt activation and Bcl-2 up-regulation. *Biochem Biophys Res Commun*, 2009; 389: 105–111.
3. Borch E, Parri M, Papucci L et al. Role of NADPH oxidase in H9c2 cardiac muscle cells exposed to simulated ischemia-reperfusion. *J Cell Mol Med*, 2008; 13: 2724–2735.
4. Laalou FZ, de Vasconcelos AP, Oberling P et al. Involvement of the basal cholinergic forebrain in the mediation of general (propofol) anesthesia. *Anesthesiology*, 2008; 108: 888–896.
5. Yuzer H, Yuzbasioglu MF, Ciralik H et al. Effects of intravenous anesthetics on renal ischemia/reperfusion injury. *Ren Fail*, 2009; 31: 290–296.
6. Iyer VN, Hoel R, Rabinstein AA. Propofol infusion syndrome in patients with refractory status epilepticus: An 11-year clinical experience. *Crit Care Med*, 2009; 37: 3024–3030.
7. Bandschapp O, Ginz HF, Soule CL et al. In vitro effects of propofol and volatile agents on pharmacologically induced chloride channel myotonia. *Anesthesiology*, 2009; 111: 584–590.
8. Matsukawa K, Nakamoto T, Kadowaki A et al. The enhancing effect of propofol anesthesia on skeletal muscle mechanoreflex in conscious cats *Auton Neurosci*, 2009; 151: 111–116.
9. Short CE, Bufalari A. Propofol anesthesia. *Vet Clin North Am Small Anim Pract*, 1999; 29: 747–778.
10. El-Radaideh KM. Effect of pretreatment with lidocaine, intravenous paracetamol and lidocaine-fentanyl on propofol injection pain. *Comparative study. Rev Bras Anesthesiol*, 2007; 57: 32–38.

11. Mahmoud M, Gunter J, Donnelly LF et al. A comparison of dexmedetomidine with propofol for magnetic resonance imaging sleep studies in children. *Anesth Analg*, 2009; 109: 745–753.
12. Doufas AG, Morioka N, Mahgoub AN et al. Automated responsiveness monitor to titrate propofol sedation. *Anesth Analg*, 2009; 109: 778–786.
13. Nimmaanrat S. Myoclonic movements following induction of anesthesia with propofol: A case report. *J Med Assoc Thai*, 2005; 88: 1955–1997.
14. Mounir K, Bensghir M, Drissi Kamili N. Seizures during intravenous propofol anesthesia. Five cases of seizures during intravenous propofol anesthesia for neurosurgery. *Can J Anaesth*, 2009; 56: 986–987.
15. Grasshoff C, Herrera-Marschitz M, Goiny M et al. Modulation of ventral pallidal dopamine and glutamate release by the intravenous anesthetic propofol studied by *in vivo* microdialysis. *Amino Acids*, 2005; 28: 145–148.
16. Finsterer J. Treatment of mitochondrial disorders. *Eur J Paediatr Neurol*, 2010; 14: 29–44.
17. Vesta KS, Martina SD, Kozlowski EA. Propofol-induced priapism, a case confirmed with rechallenge *Ann Pharmacother*, 2006; 40: 980–982.
18. Bonnet U, Harkener J, Scherbaum N.J. A case report of propofol dependence in a physician. *Psychoactive Drugs*, 2008; 40: 215–217.
19. Roussin A, Montastruc JL, Lapeyre-Mestre M. Pharmacological and clinical evidences on the potential for abuse and dependence of propofol: A review of the literature. *Fundam Clin Pharmacol*, 2007; 21: 459–466.
20. Steele RG, Ajayoglu B. Novel management of propofol induced dystonia in the post anaesthesia care unit. *Anaesth Intensive Care*, 2007; 35: 138.
21. English WA, Giffin NJ, Nolan JP. Myoclonus after cardiac arrest: Pitfalls in diagnosis and prognosis. *Anaesthesia*, 2009; 64: 908–911.
22. Arpesella R, Dalocchio C, Arbasino C et al. A patient with intractable posthypoxic myoclonus (Lance-Adams syndrome) treated with sodium oxybate. *Anaesth Intensive Care*, 2009; 37: 314–318.
23. Otterspoor LC, Kalkman CJ, Cremer OL. Update on the propofol infusion syndrome in ICU management of patients with head injury. *Curr Opin Anaesthesiol*, 2008; 21: 544–551.
24. Vernooy K, Delhaas T, Cremer OL et al. Electrocardiographic changes predicting sudden death in propofol-related infusion syndrome. *Heart Rhythm*, 2006; 3: 131–137.
25. Junttila MJ, Gonzalez M, Lizotte E et al. Induced Brugada-type electrocardiogram, a sign for imminent malignant arrhythmias. *Circulation*, 2008; 117: 1890–1893.
26. Mali AR, Patil VP, Pramesh CS, Mistry RC. Hyperkalemia during surgery: is it an early warning of propofol infusion syndrome? *J Anesth*, 2009; 23: 421–423.
27. Robinson JD, Melman Y, Walsh EP. Cardiac conduction disturbances and ventricular tachycardia after prolonged propofol infusion in an infant. *Pacing Clin Electrophysiol*, 2008; 31: 1070–1073.
28. Inamura M, Okamoto H, Kuroiwa M et al. General anesthesia for patients with Brugada syndrome. A report of six cases. *Can J Anaesth*, 2005; 52: 409–412.
29. Riezzo I, Centini F, Neri M et al. Brugada-like EKG pattern and myocardial effects in a chronic propofol abuser. *Clin Toxicol (Philadelphia)*, 2009; 47: 358–363.
30. Miner JR, Burton JH. Clinical practice advisory: Emergency department procedural sedation with propofol. *Ann Emer Med*, 2007; 50: 182–187.
31. Vernooy K, Vernooy K, Delhaas T et al. Electrocardiographic changes predicting sudden death in propofol-related infusion syndrome. *Heart Rhythm*, 2006; 3: 131–137.
32. Grant AO. Electrophysiological basis and genetics of Brugada syndrome. *J Cardiovasc Electrophysiol*, 2005; 1: S3–S7.
33. Lopez-Barbeito B, Ljuis M, Delgado V et al. Diphenhydramine overdose and Brugada sign. *Pacing Clin Electrophysiol*. 2005; 28: 730–732.
34. Ortega-Carnicer J, Benezet J, Ruiz-Lorenzo F et al. Transient Brugada-type electrocardiographic abnormalities in renal failure reversed by dialysis. *Resuscitation*, 2002; 55: 215–219.
35. Cohen RD, Woods HF. Lactic acidosis revisited. *Diabetes*, 1983; 32: 181–191.