

The 18-fluorine-fluorodeoxyglucose positron-emission-tomography/computed tomography-guided treatment of prosthetic valve endocarditis

Grzegorz Sławiński¹, Ewa Lewicka¹, Maciej Kempa¹, Szymon Budrejko¹, Alicja Dąbrowska-Kugacka¹, Grzegorz Romanowicz², Grzegorz Raczak¹

¹Department of Cardiology and Electrotherapy, Medical University of Gdansk, Poland

²Department of Nuclear Medicine, Medical University of Gdansk, Poland

A 69-year-old male was admitted to the documented department due to a transient third-degree atrio-ventricular block (AVB) and suspicion of infective endocarditis. In the district hospital temporary ventricular pacing was applied, and vancomycin because of Staphylococcal bacteraemia. Two years prior, the patient had undergone bioprosthetic valve implantation (St. Jude Medical, 25 mm) due to complex aortic valve disease, and simultaneously had coronary artery bypass surgery.

At hospital admission, the patient was in a good general condition with no abnormalities in physical examination beyond obesity (BMI 37 kg/m²). Electrocardiogram (ECG) showed sinus rhythm and a complete AVB. Transthoracic (TTE) and transesophageal (TEE) echocardiography revealed mild left ventricular (LV) systolic dysfunction (LV ejection fraction [LVEF] 45%), mildly enlarged left ventricle (LV end-diastolic volume 160 mL) and moderate degree bioprosthetic aortic regurgitation with normal transvalvular gradients (maximum 20 mmHg), without leaflet perforation or vegetations. Repeated blood cultures were negative, blood tests showed increased C-reactive protein (CRP) concentration (**Suppl. Table 1**), and rifampicin and gentamicin were added to vancomycin.

On the 18th day, the patient received permanent epicardial pacing system due to elevated CRP concentration (**Suppl. Table 1**), inconclusive for endocarditis TTE and TEE results, and increased

risk of cardiac device-related infective endocarditis (CDRIE). Because of pericardial adhesions after previous cardiac surgery and marked obesity, only the epicardial right ventricular lead (MyoDex™ 1084 T, St. Jude Medical) and VVI pacemaker (Vitatron SRG20A1, Medtronic) were implanted. In subsequent days, CRP levels decreased (**Suppl. Table 1**), but remained above the reference range.

To confirm or exclude infective endocarditis, the patient was referred for 18-fluorine-fluorodeoxyglucose positron-emission-tomography/computed tomography (18F-FDG PET/CT), with acquisition according to standard protocol (Biograph 40 mCT, Siemens Healthineers). This showed a non-homogenous increased uptake around the aortic bioprosthesis (Fig. 1A) with maximal standardized uptake values (SUV_{max}) up to 5.0. The ratio of SUV_{max} to the mean SUV of liver [SUV_{r(liver)}] was 1.36, and the ratio of SUV_{max} to the mean mediastinal blood pool stream SUV [SUV_{r(MBPS)}] was 1.43. On this basis, a decision was made to prolong therapy with rifampicin and linezolid.

On the 34th day, a hemodynamically unstable ventricular tachycardia occurred. Another 18F-FDG PET/CT study was performed, which showed decreased metabolic activity around the bioprosthetic valve, but without complete resolution, with SUV_{max} 3.0, SUV_{r(liver)} 0.98 and SUV_{r(MBPS)} 1.37 (Fig. 1B). The inflammatory biomarker levels in blood tests were within normal range. A decision

Address for correspondence: Prof. Ewa Lewicka, MD, PhD, Department of Cardiology and Electrotherapy, Medical University of Gdansk, ul. Dębinki 7, 80–211 Gdańsk, Poland, e-mail: ewa.lewicka@gumed.edu.pl

Received: 8.12.2018

Accepted: 4.02.2019

was made to implant a subcutaneous implantable cardioverter-defibrillator (S-ICD), which was performed on the 77th day (Emblem S-ICD A209, lead 3401, Boston Scientific) (**Suppl. Fig. 1**). The intraoperative defibrillation testing confirmed appropriate detection and termination of induced ventricular fibrillation.

The second day after implantation, an inappropriate shock occurred without any defined reason (**Suppl. Fig. 2**). After consultation with the ICD manufacturer, it was speculated that the shock was presumably caused by the air being released from the connector area. The patient was discharged from the hospital on the 84th day and asked to continue oral linezolid for the next 10 days.

A month later the patient was admitted to the documented department because of symptoms of LV heart failure. Mildly elevated CRP levels were present, but with negative blood cultures. Rifampicin and linezolid were administered. TTE and TEE showed progression of aortic regurgitation with the paravalvular leak, and further LV enlargement (LV end-diastolic volume 256 mL) and LVEF 37% (**Suppl. Fig. 3**). The patient was referred for another 18F-FDG PET/CT examination which showed moderately increased metabolic activity around the aortic valve with SUV_{max} 4.1, $SUV_{r(liver)}$ 1.18, and $SUV_{r(MBPS)}$ 1.56 (Fig. 1C). The patient was then qualified for surgical treatment. The aortic valve bioprosthesis was replaced (Medtronic 29 mm), additionally an epicardial atrial lead was implanted (CapSure Epi lead4968, Medtronic) and the pacing system was upgraded to dual-chamber (Vitatron DRG70A1, Medtronic). Rifampicin and linezolid were thereafter continued for 6 weeks. Control laboratory tests revealed a gradual decrease in the levels of inflammatory markers and TTE showed normal aortic valve function and LVEF 45%. Two months after the surgery, the patient was discharged from the hospital in good general condition without antibacterial treatment. During the 2-year observation, the patient remained in good condition without significant changes in frequent TTE imaging.

Infective endocarditis still remains a challenge and is associated with poor prognosis, especially in patients with implanted cardiac devices [1]. In the present patient, a transient complete AVB was the first clinical manifestation of infective endocarditis, however repeated echocardiography remained inconclusive. It was reported that the use

of transvenous temporary pacing increases the risk of CDRIE [2]. Also, patients with elevated CRP concentration at the time of cardiac device implantation may have an increased risk of early complications requiring transvenous lead removal [3]. These were additional factors apart from active endocarditis, later confirmed by the 18F-FDG PET/CT imaging, a finding which supported the epicardial pacing system implantation in this patient.

Data from the literature indicate that 18F-FDG PET/CT is a useful diagnostic tool in challenging cases of infective endocarditis, also in patients with prosthetic valve endocarditis [4]. The examination performed before ICD implantation showed a decrease in metabolic activity around the aortic bioprosthesis. This was the reason for implanting the S-ICD. Nevertheless, because of incomplete resolution in the 18F-FDG PET/CT imaging at this time, despite negative blood cultures, the patient should have been referred for cardiac surgery instead of implanting the S-ICD. It would have eliminated progression of aortic regurgitation and cardiac decompensation due to a persistent inflammatory process. Also, an inappropriate ICD shock could have been avoided. However, the 18F-FDG PET/CT showed its usefulness in this case of suspected endocarditis. Other advanced echocardiographic techniques, like three-dimensional TTE or three-dimensional TEE can be useful in the recognition of infective endocarditis. Additionally, magnetic resonance imaging can be used in the search for extracardiac infectious foci, for instance cerebral lesions. In cases of inaccessibility 18F-FDG PET/CT imaging these techniques should be used to confirm or exclude infective endocarditis.

Subcutaneous ICD is a safe and effective method in preventing sudden cardiac death with a low rate of complications [5, 6]. The inappropriate S-ICD shock which occurred in the present patient was presumably caused by air being released from the connector area. The S-ICD shock due to residual air near the S-ICD system (around the xiphoid process or the distal part of the electrode) has been previously reported [7, 8].

In conclusion, the use of 18F-FDG PET/CT imaging is very helpful not only in diagnosis, but also in monitoring treatment of infective endocarditis. It enables decision making regarding optimal time and type of implantable cardiac devices, as well as the decision about surgery.

Conflict of interest: None declared

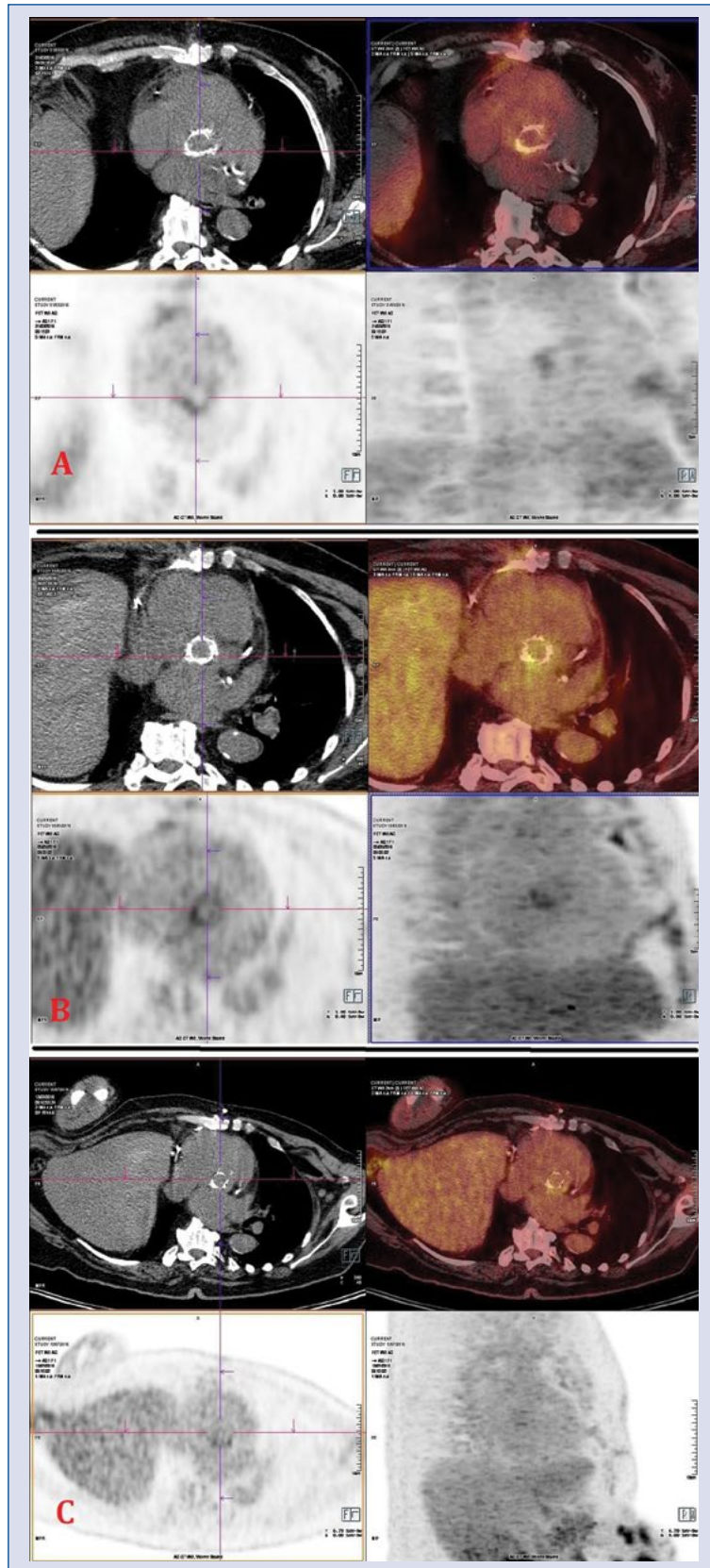


Figure 1. The 18-fluorine-fluorodeoxyglucose positron-emission-tomography/computed tomography (18F-FDG PET/CT) images obtained from the patient showing changes in metabolic activity around the aortic bioprosthesis; **A.** After initial antimicrobial therapy; **B.** Before subcutaneous implantable cardioverter-defibrillator implantation; **C.** During the second hospitalization.

References

1. Murdoch DR, Corey GR, Hoen B, et al. Clinical presentation, etiology, and outcome of infective endocarditis in the 21st century: the International Collaboration on Endocarditis-Prospective Cohort Study. *Arch Intern Med.* 2009; 169(5): 463–473, doi: [10.1001/archinternmed.2008.603](https://doi.org/10.1001/archinternmed.2008.603), indexed in Pubmed: [19273776](https://pubmed.ncbi.nlm.nih.gov/19273776/).
2. Polyzos KA, Konstantelias AA, Falagas ME. Risk factors for cardiac implantable electronic device infection: a systematic review and meta-analysis. *Europace.* 2015; 17(5): 767–777, doi: [10.1093/europace/euv053](https://doi.org/10.1093/europace/euv053), indexed in Pubmed: [25926473](https://pubmed.ncbi.nlm.nih.gov/25926473/).
3. Sławiński G, Kempa M, Lewicka E, et al. Elevated C-reactive protein levels during cardiac implantations may increase the risk of early complications requiring transvenous lead removal: a preliminary report. *Pol Arch Intern Med.* 2018; 128(2): 138–140, doi: [10.20452/pamw.4217](https://doi.org/10.20452/pamw.4217), indexed in Pubmed: [29511152](https://pubmed.ncbi.nlm.nih.gov/29511152/).
4. Mahmood M, Kendi AT, Ajmal S, et al. Meta-analysis of 18F-FDG PET/CT in the diagnosis of infective endocarditis. *J Nucl Cardiol.* 2017 [Epub ahead of print], doi: [10.1007/s12350-017-1092-8](https://doi.org/10.1007/s12350-017-1092-8), indexed in Pubmed: [29086386](https://pubmed.ncbi.nlm.nih.gov/29086386/).
5. Burke MC, Gold MR, Knight BP, et al. Safety and efficacy of the totally subcutaneous implantable defibrillator: 2-year results from a pooled analysis of the IDE study and Effortless registry. *J Am Coll Cardiol.* 2015; 65(16): 1605–1615, doi: [10.1016/j.jacc.2015.02.047](https://doi.org/10.1016/j.jacc.2015.02.047), indexed in Pubmed: [25908064](https://pubmed.ncbi.nlm.nih.gov/25908064/).
6. Kempa M, Budrejko S, Sławiński G, et al. Polish single-centre follow-up of subcutaneous implantable cardioverter-defibrillator (S-ICD) systems implanted for the prevention of sudden cardiac death. *Kardiol Pol.* 2018; 76(2): 452–458, doi: [10.5603/KP.a2017.0244](https://doi.org/10.5603/KP.a2017.0244), indexed in Pubmed: [29350391](https://pubmed.ncbi.nlm.nih.gov/29350391/).
7. Lee S, Souvaliotis N, Mehta D, et al. Inappropriate shock in a subcutaneous cardiac defibrillator due to residual air. *Clin Case Rep.* 2017; 5(8): 1203–1206, doi: [10.1002/ccr3.1009](https://doi.org/10.1002/ccr3.1009), indexed in Pubmed: [28781823](https://pubmed.ncbi.nlm.nih.gov/28781823/).
8. Zipse MM, Sauer WH, Varosy PD, et al. Inappropriate shocks due to subcutaneous air in a patient with a subcutaneous cardiac defibrillator. *Circ Arrhythm Electrophysiol.* 2014; 7(4): 768–770, doi: [10.1161/CIRCEP.114.001614](https://doi.org/10.1161/CIRCEP.114.001614), indexed in Pubmed: [25140025](https://pubmed.ncbi.nlm.nih.gov/25140025/).