

# Percutaneous closure of the inadvertent subclavian artery cannulation during pacemaker implantation

Xueying Chen, Jin Bai, Fei Han, Daxin Zhou, Yangang Su

Department of Cardiology, Zhongshan Hospital, Fudan University, Shanghai, China

## Introduction

Puncture of the left subclavian vein is a common technique during the procedure of pacemaker (PM) implantation and radiofrequency ablation. However, it might lead to a fatal complication when accidentally placing the sheath into the subclavian artery, an anatomically non-compressive site, exposing the patient to severe risk of life-threatening hemorrhage [1]. This complication can be treated by either surgical [2] or endovascular methods including percutaneous stenting [3, 4] and closure device [4–7]. Herein reported is a case of accidental subclavian artery cannulation during a PM implantation and it is successfully treated with percutaneous closure device.

## Case report

A 57-year-old man with a history of complete atrioventricular block was admitted to the Department of Cardiology, Zhongshan Hospital, Fudan University, Shanghai, China to implant a VVI single-chamber PM. The guide wire was misplaced into the left subclavian artery, and was not recognized by the fact that the first attempt drew dark red blood into the syringe and the blood flowed slowly and continuously through the needle. Furthermore, an inadequately experienced operator did not double-check the wire inside the vein by deeply inserting the wire into the inferior vena cava under fluoroscopy. Consequently, placement of a 7 F Peel-Away Introducer was carried out and resulted in inadvertent cannulation into the left subclavian artery (Fig. 1A). The cannulation of the left subclavian artery was confirmed by the high pressure of the blood and the arterial pressure

curve. A 0.035 J-wire was then introduced through the catheter into the subclavian artery, allowing removal of the sheath and insertion of the percutaneous closure device with an arteriotomy locator.

Then the implantation of a PM was successfully performed by puncture and placing a 7 F Peel-Away Introducer in the left subclavian vein, through which the right ventricular electrode was located at the right ventricular apex (Fig. 1B). The 8 F Angio-Seal device (St. Jude Medical, St. Paul, MN, USA) was subsequently inserted and deployed to close the subclavian artery cannulation. The patient showed no sign of local hemorrhage or arterial occlusion. A repeat radiograph of the chest excluded hemorrhagic complications including hemothorax (Fig. 1C). He was discharged 2 days following the deployment of the Angio-Seal positioning. A computed tomography angiography taken 6 months after the procedure showed no obstruction of the subclavian artery (Fig. 1D).

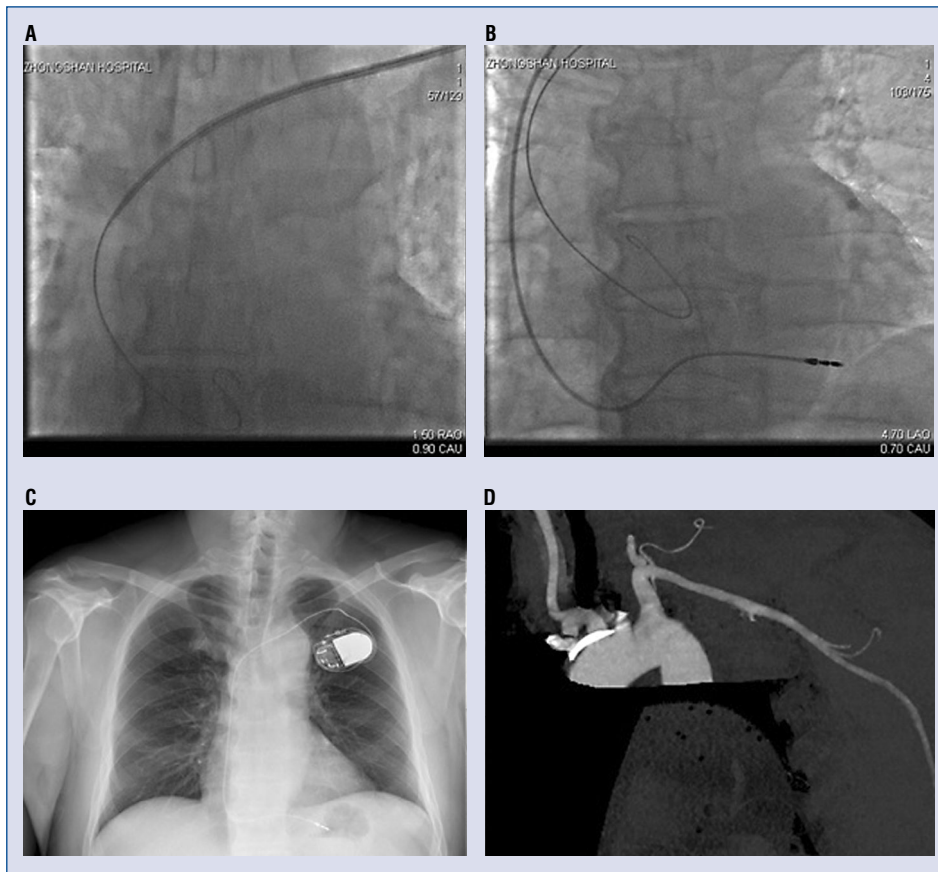
## Discussion

Inadvertent arterial puncture occurs in proximally 1% and 3% of the jugular and subclavian approaches of central venous catheterization, respectively. The complication is usually recognized immediately before the sheath is put into the artery. However, in hypotensive and hemodynamically unstable patients, it is more difficult to confirm this. The incidence of accidental subclavian arterial puncture is even lower during the procedure of PM implantation and radiofrequency ablation under X-ray. In the present case, due to the lack of characteristic bright red pulsatile flow and reconfirming the wire inside the vein, the operator didn't recognize the misplacing of the wire

**Address for correspondence:** Dr. Jin Bai, Department of Cardiology, Zhongshan Hospital, Fudan University, 180 Feng Lin Road, Shanghai, 200032, China, e-mail: [jinbai1970@yeah.net](mailto:jinbai1970@yeah.net)

Received: 24.04.2017

Accepted: 16.05.2017



**Figure 1.** A. X-ray fluoroscopy showing both the guide wire and the 7 F sheath inside the left subclavian artery: Possibility of a subclavian artery cannulation was suspected based on a re-examination of the radiograph which showed the guide wire crossing the midline and the tip located on the left side; B. X-ray fluoroscopy showing the right ventricular electrode located at the right ventricular apex and a 0.035 J-wire inside the left subclavian artery; C. A repeat radiograph of the chest the second day after pacemaker implantation and subclavian artery cannulation closure excluded hemorrhagic complications including hemothorax; D. A computed tomography angiography taken 6 months after pacemaker implantation and subclavian artery cannulation closure which shows no obstruction of the subclavian artery.

until the sheath was put into the artery. Thus, it is highly recommended to deeply insert the wire into the inferior vena cava to make sure the wire is inside the vein.

When a sheath removal is attempted at a non-compressive site, such as subclavian artery, increased risk for serious complications will occur, including fatal hemorrhage, pseudoaneurysm formation, arterial dissection or occlusion, and distal embolism. Surgical or endovascular technique, or a combination of these approaches can be used to treat the patient with inadvertent subclavian artery cannulation. In addition to surgical repair, use of a stent-graft is a good alternative in selected patients [3], although this requires specific anatomic conditions and taking anti-platelet drugs. Recently, percutaneous closure

devices have been reported to be generally safe and effective [5–8]. The Angio-Seal device used in the presented case has already been widely and safely used to close femoral artery in patients undergoing interventional treatment, and the complications of which are as rare as manual compression [9].

Nevertheless, caution should be taken into account since occlusion of the subclavian artery requires a balloon and a thrombectomy to restore arterial blood flow which was reported as a severe complication of this technique [10].

### Conclusions

In the present case, the Angio-Seal closure device proved to be a rapid, effective, and safe op-

tion for inadvertent subclavian artery cannulation during the procedure of PM implantation. Reconfirmation of the guide wire inside the vein under fluoroscopy is highly recommended to avoid the misplacement of the sheath into the artery. Moreover, follow-up of the angiography to determine if the subclavian artery is unobstructed should also be encouraged after percutaneous closure.

**Conflict of interest:** None declared

## References

1. Kilbourne MJ, Bochicchio GV, Scalea T, et al. Avoiding common technical errors in subclavian central venous catheter placement. *J Am Coll Surg.* 2009; 208(1): 104–109, doi: [10.1016/j.jamcollsurg.2008.09.025](https://doi.org/10.1016/j.jamcollsurg.2008.09.025), indexed in Pubmed: [19228511](https://pubmed.ncbi.nlm.nih.gov/19228511/).
2. Shah PM, Babu SC, Goyal A, et al. Arterial misplacement of large-caliber cannulas during jugular vein catheterization: case for surgical management. *J Am Coll Surg.* 2004; 198(6): 939–944, doi: [10.1016/j.jamcollsurg.2004.02.015](https://doi.org/10.1016/j.jamcollsurg.2004.02.015), indexed in Pubmed: [15194076](https://pubmed.ncbi.nlm.nih.gov/15194076/).
3. Cipanio S, Oggionio R, Mangano V, et al. An accidental subclavian artery cannulation: successful catheter removal by percutaneous vascular stenting. *Minerva Anestesiol.* 2007; 73(4): 249–253, indexed in Pubmed: [17242656](https://pubmed.ncbi.nlm.nih.gov/17242656/).
4. Nicholson T, Ettles D, Robinson G. Managing inadvertent arterial catheterization during central venous access procedures. *Cardiovasc Intervent Radiol.* 2004; 27(1): 21–25, indexed in Pubmed: [15109223](https://pubmed.ncbi.nlm.nih.gov/15109223/).
5. Cohen JE, Moshe Gomori J, Anner H, et al. Inadvertent subclavian artery cannulation treated by percutaneous closure. *J Clin Neurosci.* 2014; 21(11): 1973–1975, doi: [10.1016/j.jocn.2014.04.009](https://doi.org/10.1016/j.jocn.2014.04.009), indexed in Pubmed: [24913929](https://pubmed.ncbi.nlm.nih.gov/24913929/).
6. Ananthakrishnan G, White RD, Bhat R, et al. Inadvertent subclavian artery cannulation: endovascular repair using a collagen closure device—report of two cases and review of the literature. *Case Rep Vasc Med.* 2012; 2012: 150343, doi: [10.1155/2012/150343](https://doi.org/10.1155/2012/150343), indexed in Pubmed: [22934229](https://pubmed.ncbi.nlm.nih.gov/22934229/).
7. Bangard C, Chang DH, Libicher M, et al. [Misplacement of central venous catheters in the subclavian artery: safe retrieval with a percutaneous closure device (AngioSeal)]. *RoFo : Fortschritte auf dem Gebiete der Rontgenstrahlen und der Nuklearmedizin.* 2013; 185(6): 546–549, doi: [10.1055/s-0032-1330738](https://doi.org/10.1055/s-0032-1330738), indexed in Pubmed: [23450371](https://pubmed.ncbi.nlm.nih.gov/23450371/).
8. Devriendt A, Tran-Ngoc E, Gottignies P, et al. Ease of using a dedicated percutaneous closure device after inadvertent cannulation of the subclavian artery: case report. *Case Rep Med.* 2009; 2009: 728629, doi: [10.1155/2009/728629](https://doi.org/10.1155/2009/728629), indexed in Pubmed: [19718242](https://pubmed.ncbi.nlm.nih.gov/19718242/).
9. Kadner A, Schmidli J, Schwegler I, et al. Complications associated with the arterial puncture closure device: Angio-Seal. *Vasc Endovascular Surg.* 2008; 42(3): 225–227, doi: [10.1177/1538574407312657](https://doi.org/10.1177/1538574407312657), indexed in Pubmed: [18230871](https://pubmed.ncbi.nlm.nih.gov/18230871/).
10. Sharma M, Sakhuja R, Teitel D, et al. Percutaneous arterial closure for inadvertent cannulation of the subclavian artery: a call for caution. *J Invasive Cardiol.* 2008; 20(7): E229–E232, indexed in Pubmed: [18599910](https://pubmed.ncbi.nlm.nih.gov/18599910/).