

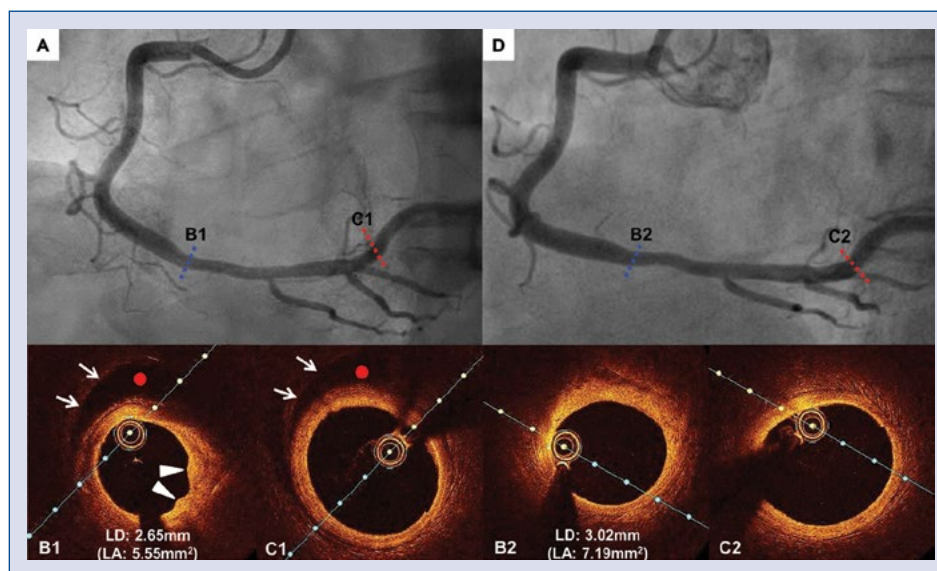
# Assessment for ambiguous angiographic finding in patient with acute myocardial infarction by optical coherence tomography

Yongcheol Kim, Myung Ho Jeong, Min Chul Kim, Doo Sun Sim,  
Young Joon Hong, Ju Han Kim, Youngkeun Ahn

Division of Cardiology, Chonnam National University Hospital, Gwangju, Korea

A 72-year-old man with history of treated hypertension, presented with sudden onset of chest pain at rest and evidence of minimal ST-segment elevation in the inferior electrocardiogram leads. Urgent coronary angiography (CAG) demonstrated the diffuse mild stenosis from distal right coronary artery (RCA) to posterolateral branch (Fig. 1A).

The non flow-limiting nature of the lesion and the suspicious RCA, potentially a culprit lesion, led to assessment with optical coherence tomography (OCT). OCT demonstrated false lumen with intramural hematoma between distal RCA and posterolateral branch and folding of the luminal intimal contour at distal RCA (Fig. 1 — B1, C1).



**Figure 1.** A. Angiographic assessment of the right coronary artery (RCA) demonstrating diffuse mild stenosis from distal RCA to posterolateral branch; **B1, C1.** Optical coherence tomography (OCT) image demonstrating false lumen, having evidence of separated external elastic lamina (arrows), with intramural hematoma (red point) and showing folding of the luminal intimal contour (arrowheads in B1); **D.** Six-month follow-up coronary angiography with medication of aspirin and clopidogrel; **B2, C2.** Six-month follow-up OCT demonstrating complete resolution of intramural hematoma in posterolateral branch (**C2**) and healed intramural hematoma with enlarged caliber in distal RCA (**B2**); LA — lumen area; LD — lumen diameter.

**Address for correspondence:** Myung Ho Jeong, MD, Cardiovascular Convergence Research Center of Chonnam National University Hospital, Gwangju 501-757, Republic of Korea, tel: 82-62-220-6243, fax: 82-62-228-7174, e-mail: myungho@chollian.net

Received: 24.02.2018

Accepted: 19.03.2018

The patient was diagnosed as spontaneous coronary artery dissection (SCAD) type 3, hemodynamically stable and asymptomatic. Therefore, further intervention was avoided at this time and patient was discharged on dual antiplatelet therapy with acetylsalicylic acid and clopidogrel for 6 months. Six-month follow-up CAG showed improved luminal calibre in the affected segments and preserved good distal flow (Fig. 1D). Follow-up OCT demonstrated healed intramural hematoma with enlarged calibre in distal RCA

(Fig. 1 — B2) and complete resolution of intramural hematoma in posterolateral branch (Fig. 1 — C2).

Spontaneous coronary artery dissection type 3, mimic atherosclerosis, is the most challenging to be confirmed by coronary angiography in angiographic classification of SCAD, developed by Saw et al. [J Am Coll Cardiol. 2016; 68: 297–312]. This case highlights the benefit that the superior resolution (10  $\mu\text{m}$ ) of OCT is able to identify false lumen with intramural haematoma for diagnostic conformation of SCAD type 3.

**Conflict of interest:** None declared