

Intra-ventricular thrombus resolution after anticoagulation therapy with rivaroxaban in patient with poor anticoagulation quality

María Asunción Esteve-Pastor¹, Esteban Orenes-Piñero¹, Vanessa Roldán²,
Javier Lacunza-Ruiz¹, Mariano Valdés¹, Francisco Marín¹

¹Department of Cardiology, Hospital Universitario Virgen de la Arrixaca, IMIB-Arrixaca, CIBER-CV, University of Murcia, Murcia, Spain

²Department of Hematology and Clinical Oncology, Hospital Universitario Morales Meseguer, IMIB-Arrixaca, University of Murcia, Spain

Intra-ventricular thrombus formation remains a serious complication after acute myocardial infarction (MI) despite early reperfusion therapy with primary percutaneous coronary intervention [1]. Vitamin K antagonists (VKAs) have been established as the main anticoagulant treatment. Nevertheless, patients treated with VKAs need good anticoagulation control for optimum effect, avoiding bleeding and ischaemic events. Therefore, non-vitamin K oral anticoagulants (NOACs) emerged as effective drugs as VKAs, and safer but the effectiveness for a resolution of pre-existing intra-ventricular thrombus has, to date, not been analyzed. Herein described, for the first time, is a case of acute MI complicated by intra-ventricular thrombus with poor anticoagulation control with VKAs. It was successfully resolved under rivaroxaban 20 mg treatment.

A 43-year-old smoker male with type 2 diabetes undergoing treatment with metformin and good metabolic control was referred to the documented Emergency Department due to prolonged chest pain. The patient had no personal or family history of thromboembolic events. Electrocardiogram revealed sinus rhythm with ST-segment elevation in leads V2–V5 and chest radiography showed pulmonary congestion. The patient was diagnosed with ST-segment elevation MI complicated and was administered a loading dose of aspirin 250 mg and 600 mg of clopidogrel and underwent emergency cardiac catheterization. The coronary angiography showed a subtotal occlusion of medium left anterior

descending coronary artery. Subsequent percutaneous coronary intervention was performed by placement of 2 drug eluting stents (Absorb 3.5 × 20 mm and 3 × 12 mm). Transthoracic echocardiography showed anteroseptal and apical akinesia with impaired ejection fraction (EF, 35%) and a thrombus in the apex of the left ventricle (Fig. 1). Magnetic cardiac resonance imaging (Fig. 1) confirmed the presence of two small thrombi in the apex. During the admission period, no clotting abnormalities were observed and platelet count was normal in daily blood tests. The patient was discharged receiving dual antiplatelet treatment, with aspirin 100 mg and clopidogrel 75 mg and oral anticoagulation treatment with acenocoumarol. After 2 months of anticoagulation, the patient showed only one international normalized ratio (INR) value within the therapeutic range (INR 2.0–3.0), with time in therapeutic range assessed by Rosendaal method of 0% and 12.5% by direct method (Fig. 1). Frequent visits to the anticoagulation clinic were increased and therapeutic adherence was assessed to improve the quality of anticoagulation. Unfortunately, the transthoracic echocardiography confirmed the presence of thrombi in apex, even with an improvement of systolic function (EF 45%) (Fig. 1). Because the patient had high SAME-TT₂R₂ score that predicts poor anticoagulation control under VKA therapy, rivaroxaban 20 mg once a day was initiated as anticoagulant therapy, maintaining dual antiplatelet therapy with aspirin and clopidogrel. After 3 months of anticoagulation with rivaroxaban,

Address for correspondence: Francisco Marín, MD, PhD, Department of Cardiology, Hospital Universitario Virgen de la Arrixaca, Ctra Madrid-Cartagena, Murcia, 30120, Spain, e-mail: fcomarino@hotmail.com

Received: 30.08.2017

Accepted: 01.11.2017

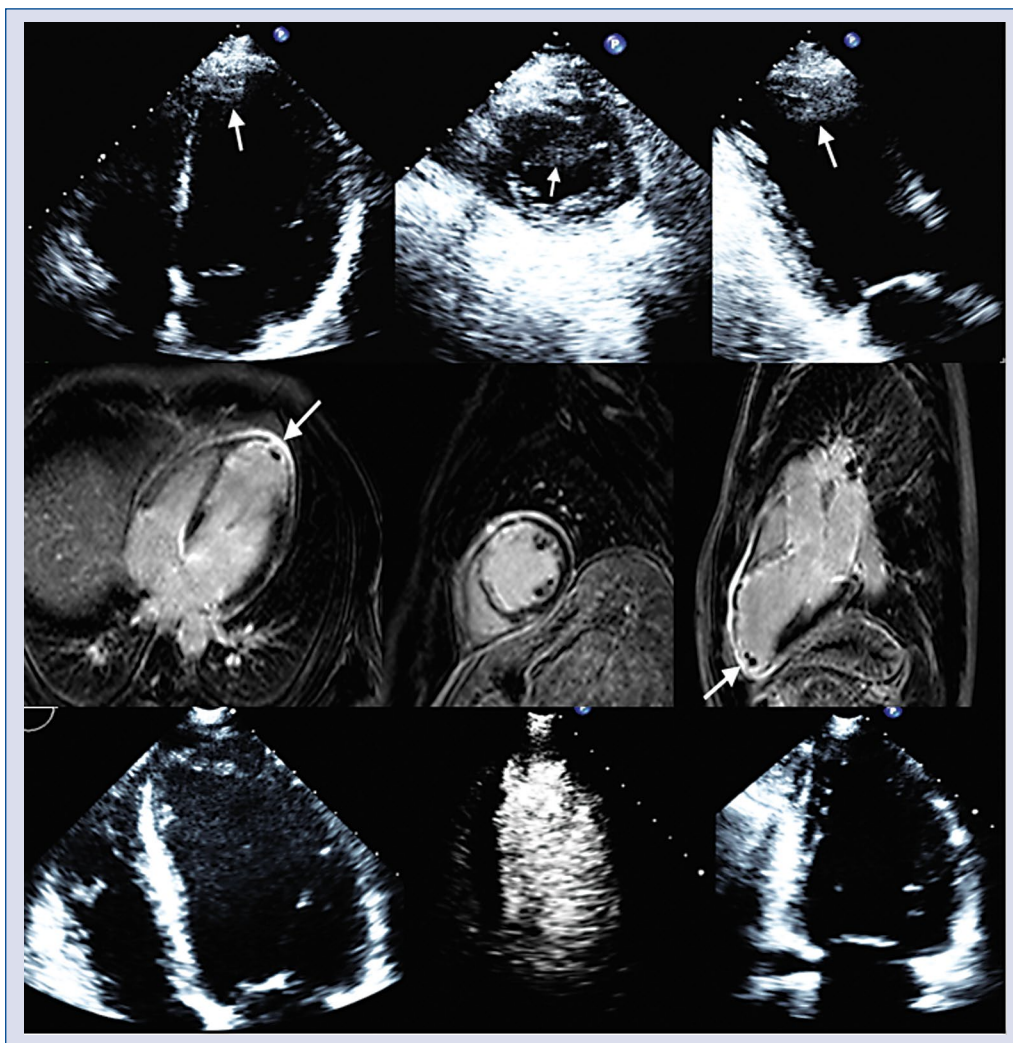


Figure 1. Evolution of left ventricular thrombus with vitamin K antagonists and with rivaroxaban treatment. **Upper images:** Transthoracic echocardiography revealed a fixed mural thrombus in the apex of the left ventricle after 2 months with anticoagulation treatment with vitamin K antagonists. **Middle images:** Cardiac magnetic resonance with late gadolinium enhancement imaging. The image on the left shows 4-chamber view with a mural thrombus adherent to left ventricular apex. Thrombus was easily identified as a low signal-intensity mass surrounded by high signal intensity structures in apex due to hyper-enhanced myocardial scar. The middle image shows short axis view with hyper-enhanced myocardial scar at septum and two images of ventricular thrombi. The image on the right shows the same with a 2-chamber view. **Bottom images:** Transthoracic echocardiography revealed complete thrombus resolution after 3 months of anticoagulant therapy with rivaroxaban.

a new echocardiography confirmed the resolution of left ventricular thrombus. The patient presented no major bleeding or thromboembolic events during treatment with rivaroxaban after 18 months of follow-up.

Presented herein, for the first time, records the use of rivaroxaban 20 mg as a treatment of ventricular thrombus after MI in a patient with poor anticoagulation quality with VKA. Recent studies have reported an incidence of left ventricular thrombus from 2.5% to 15%, up to 23.5%

in anterior MI and embolization of left ventricular thrombi has been reported in up to 20% of patients [1]. Clinical guidelines recommend anticoagulation with VKA in addition to dual platelet when MI complicated by a ventricular thrombus to avoid thromboembolic events [2]. Unfortunately, triple therapy (dual antiplatelet treatment plus anticoagulation treatment) increases bleeding risk by more than double than with only dual antiplatelet therapy [3]. VKAs have shown to be highly effective for stroke prevention but the effectiveness is dependent on

the quality of anticoagulation control. VKA therapy has many shortcomings that include routine monitoring to achieve its narrow therapeutic index (INR 2.0–3.0), bleeding complications, drug interactions and a slow onset of action [3, 4]. Therapeutic effect with VKAs has a high inter and intra-patient variability and quality of anticoagulation control is the result of a dynamic process with the potential for rapid and long term variation within the individual patient in relation to compliance or intercurrent disease. Time in therapeutic range (TTR) is a recognized measure of quality of anticoagulation treatment, calculated by Rosendaal or by proportion of INR values in range (PINRR). Clinical guidelines recommend TTR > 70% to achieve high quality of anticoagulation treatment. Patients with poor anticoagulation control are at risk of both bleeding and ischaemic events. Moreover, during the first 30 days of VKA treatment, there was a 71% increased risk of ischemic stroke when compared with no use of any antithrombotic therapy, being highest in the first weeks due to INR fluctuations and suboptimal TTR in the inception phase. Besides the above, there is increasing evidence that VKAs have poor capability to resolve large intracardiac thrombi [4]. To ensure high quality of anticoagulation control, many visits to the anticoagulation clinics and several dose adjustments are necessary and practical barriers such as long distance or sociodemographic characteristics of the patients could affect the adherence to VKA therapy [5]. Another reason may be access to a health care system and the routine follow-up of patients by specialists/cardiologist involved in the anticoagulation control. Other factors that could affect the adherence to anticoagulation therapy depend on clinical and demographic characteristics of patients: elderly, fragility, polypharmacy and comorbidities such as diabetes, kidney or liver disease and intercurrent hospitalizations during the oral anticoagulants (OAC) therapy [6]. Alternatively, the NOACs have shown at least as effective as VKAs for thromboembolism prevention with fewer intracranial haemorrhages and less drug and food interactions [7], with predictable effects.

In this context, the SAME-TT₂R₂ score (sex female, age < 60, medical history [more than two comorbidities], treatment [drugs for rhythm control], tobacco use [doubled], race [doubled]) arises as a simple clinical score to help clinicians decide if a patient is likely to do well (score 0–2) or not (≥ 2) with VKA [8, 9]. This score may predict patients with poor INR control who require additional interventions to achieve acceptable anticoagulation control with VKAs or perhaps the best initial

anticoagulation treatment is direct OAC to avoid the thromboembolic risk of INR fluctuations of the inception phase of ‘trial of VKA’ [10]. The present patient had SAME-TT₂R₂ = 4 [age < 60: 1 point, diabetes and MI with congestive heart failure: both 1 point and a smoking habit: 2 points] so it was expected the patient would have poor control with VKA. Therefore, in this patient, NOACs seem to be more effective, stable and safe alternative to VKAs for anticoagulation treatment, although the effect on ventricular thrombus of NOACs has scarcely been explored.

Rivaroxaban, an oral direct inhibitor of factor Xa, has performed at least as effective as VKAs in stroke prevention in atrial fibrillation patients with a better safety profile due the lower rates of intracranial hemorrhage (ROCKET-AF) [11]. Indeed, rivaroxaban is effective and safe for the prevention of venous thromboembolism after major orthopedic surgery [12], in the treatment of acute deep-vein thrombosis and pulmonary embolism and acute coronary syndromes [13]. However, no randomized controlled trials have been performed to analyze the role of rivaroxaban to resolve large and organized intracardiac thrombi. X-TRA (Xarelto–ThRombus Accelerated resolution) was the first prospective study to investigate rivaroxaban treatment over 6 weeks for left atrial thrombus resolution in 60 patients with atrial fibrillation [14]. In addition, a retrospective registry (CLOT-AF) analyzed the thrombus resolution rate and rivaroxaban had a rate of 62.5% [15]. Makrides et al. [16] explored the effect of rivaroxaban on ventricular thrombus but at low dose (15 mg). However, no large studies have shown the role of rivaroxaban in organized left ventricular thrombi resolution with a complete dose (20 mg). Despite this, rivaroxaban 20 mg was selected because the NOAC has more studies in the resolution of cardiac thrombi (clinical cases, X-TRA and CLOT-AF) and one daily dose could guarantee better adherence in young patients.

When physicians decide to initiate oral anticoagulation with VKAs, the quality of anticoagulation should be closely controlled while trying to achieve high TTR. However, if patients have poor anticoagulation quality (such as in this case report) despite clinical interventions to improve TTR, should be changed to NOACs. In this case report, presented for the first time, was a new method of management of rivaroxaban 20 mg as a safe and effective alternative to VKAs for ventricular thrombus resolution in a patient with poor anticoagulation control with VKAs. Thus, triple therapy with NOACs may be

a new safe and effective treatment for resolution of ventricular thrombus in patients with acute coronary syndrome, especially in those patients who predict poor control with VKA.

Compliance with Ethical Standards

All procedures performed in this case report involving human participants were conducted according to the ethical standards of the institutional ethical committee of the hospital and with the 1964 Helsinki Declaration and its later amendments for Good Clinical Practice Guidelines.

Acknowledgements

We are especially grateful to Dr. Gonzalo de la Morena Valenzuela and Dr. Josefa González-Carrillo who provided us transthoracic echocardiography and cardiac magnetic resonance images.

Conflict of interest: V. Roldán has received funding for consultancy from Boehringer Ingelheim and for consultancy and lecturing from Bayer, Bristol-Myers and Pfizer, outside of this work. M. Valdés has received funding for consultancy from Medtronic and Boston Scientific, outside of this work. F. Marín has received funding for research, consultancy and lecturing from Boston Scientifics, Bayer, Astra-Zeneca, Daiichi-Sankyo and Boehringer Ingelheim, outside of this work. The remaining authors report no conflicts of interest.

References

1. Gianstefani S, Douiri A, Delithanasis I, et al. Incidence and predictors of early left ventricular thrombus after ST-elevation myocardial infarction in the contemporary era of primary percutaneous coronary intervention. *Am J Cardiol.* 2014; 113(7): 1111–1116, doi: [10.1016/j.amjcard.2013.12.015](https://doi.org/10.1016/j.amjcard.2013.12.015), indexed in Pubmed: [24485697](https://pubmed.ncbi.nlm.nih.gov/24485697/).
2. Task Force on the management of ST-segment elevation acute myocardial infarction of the European Society of Cardiology (ESC), Steg PG, James SK, Atar D, Badano LP, Blömstrom-Lundqvist C, et al. ESC Guidelines for the management of acute myocardial infarction in patients presenting with ST-segment elevation. *Eur Heart J.* 2012; 33(20): 2569–2619.
3. Sørensen R, Hansen ML, Abildstrom SZ, et al. Risk of bleeding in patients with acute myocardial infarction treated with different combinations of aspirin, clopidogrel, and vitamin K antagonists in Denmark: a retrospective analysis of nationwide registry data. *Lancet.* 2009; 374(9706): 1967–1974, doi: [10.1016/S0140-6736\(09\)61751-7](https://doi.org/10.1016/S0140-6736(09)61751-7), indexed in Pubmed: [20006130](https://pubmed.ncbi.nlm.nih.gov/20006130/).
4. Kirchhof P, Benussi S, Kotecha D, et al. 2016 ESC Guidelines for the management of atrial fibrillation developed in collaboration with EACTS. *Eur Heart J.* 2016; 37(38): 2893–2962, doi: [10.1093/eurheartj/ehw210](https://doi.org/10.1093/eurheartj/ehw210), indexed in Pubmed: [27567408](https://pubmed.ncbi.nlm.nih.gov/27567408/).
5. Roldán V, Marín F. The importance of excellence in the quality of anticoagulation control whilst taking vitamin K antagonists. *Thromb Haemost.* 2015; 113(4): 671–673, doi: [10.1160/TH14-12-1087](https://doi.org/10.1160/TH14-12-1087), indexed in Pubmed: [25673326](https://pubmed.ncbi.nlm.nih.gov/25673326/).
6. Lip G, Freedman B, De Caterina R, et al. Stroke prevention in atrial fibrillation: Past, present and future. Comparing the guidelines and practical decision-making. *Thromb Haemost.* 2017; 117(7): 1230–1239, doi: [10.1160/TH16-11-0876](https://doi.org/10.1160/TH16-11-0876), indexed in Pubmed: [28597905](https://pubmed.ncbi.nlm.nih.gov/28597905/).
7. Levy JH, Spyropoulos AC, Samama CM, et al. Direct oral anticoagulants: new drugs and new concepts. *JACC Cardiovasc Interv.* 2014; 7(12): 1333–1351, doi: [10.1016/j.jcin.2014.06.014](https://doi.org/10.1016/j.jcin.2014.06.014), indexed in Pubmed: [25523529](https://pubmed.ncbi.nlm.nih.gov/25523529/).
8. Esteve-Pastor MA, Roldán V, Valdés M, et al. The SAME-TT2R2 score and decision-making between a vitamin K antagonist or a non-vitamin K antagonist oral anticoagulant in patients with atrial fibrillation. *Expert Rev Cardiovasc Ther.* 2016; 14(2): 177–187, doi: [10.1586/14779072.2016.1116941](https://doi.org/10.1586/14779072.2016.1116941), indexed in Pubmed: [26559964](https://pubmed.ncbi.nlm.nih.gov/26559964/).
9. Ruiz-Ortiz M, Bertomeu V, Cequier Á, et al. Validation of the SAME-TT2R2 score in a nationwide population of nonvalvular atrial fibrillation patients on vitamin K antagonists. *Thromb Haemost.* 2015; 114(4): 695–701, doi: [10.1160/TH15-02-0169](https://doi.org/10.1160/TH15-02-0169), indexed in Pubmed: [26054407](https://pubmed.ncbi.nlm.nih.gov/26054407/).
10. Apostolakis S, Sullivan RM, Olshansky B, et al. Factors affecting quality of anticoagulation control among patients with atrial fibrillation on warfarin: the SAME-TT₂R₂ score. *Chest.* 2013; 144(5): 1555–1563, doi: [10.1378/chest.13-0054](https://doi.org/10.1378/chest.13-0054), indexed in Pubmed: [23669885](https://pubmed.ncbi.nlm.nih.gov/23669885/).
11. Patel MR, Mahaffey KW, Garg J, et al. ROCKET AF Investigators. Rivaroxaban versus warfarin in nonvalvular atrial fibrillation. *N Engl J Med.* 2011; 365(10): 883–891, doi: [10.1056/NEJMoa1009638](https://doi.org/10.1056/NEJMoa1009638), indexed in Pubmed: [21830957](https://pubmed.ncbi.nlm.nih.gov/21830957/).
12. Turpie AGG, Lassen MR, Eriksson BI, et al. Rivaroxaban for the prevention of venous thromboembolism after hip or knee arthroplasty. Pooled analysis of four studies. *Thromb Haemost.* 2011; 105(3): 444–453, doi: [10.1160/TH10-09-0601](https://doi.org/10.1160/TH10-09-0601), indexed in Pubmed: [21136019](https://pubmed.ncbi.nlm.nih.gov/21136019/).
13. Mega JL, Braunwald E, Wiviott SD, et al. ATLAS ACS 2–TIMI 51 Investigators. Rivaroxaban in patients with a recent acute coronary syndrome. *N Engl J Med.* 2012; 366(1): 9–19, doi: [10.1056/NEJMoa1112277](https://doi.org/10.1056/NEJMoa1112277), indexed in Pubmed: [22077192](https://pubmed.ncbi.nlm.nih.gov/22077192/).
14. Orenes-Piñero E, Esteve-Pastor MA, Valdés M, et al. Efficacy of non-vitamin-K antagonist oral anticoagulants for intracardiac thrombi resolution in nonvalvular atrial fibrillation. *Drug Discov Today.* 2017; 22(10): 1565–1571, doi: [10.1016/j.drudis.2017.05.010](https://doi.org/10.1016/j.drudis.2017.05.010), indexed in Pubmed: [28692826](https://pubmed.ncbi.nlm.nih.gov/28692826/).
15. Lip GYH, Hammerstingl C, Marín F, et al. X-TRA study and CLOT-AF registry investigators. Left atrial thrombus resolution in atrial fibrillation or flutter: Results of a prospective study with rivaroxaban (X-TRA) and a retrospective observational registry providing baseline data (CLOT-AF). *Am Heart J.* 2016; 178: 126–134, doi: [10.1016/j.ahj.2016.05.007](https://doi.org/10.1016/j.ahj.2016.05.007), indexed in Pubmed: [27502860](https://pubmed.ncbi.nlm.nih.gov/27502860/).
16. Makrides CA. Resolution of left ventricular postinfarction thrombi in patients undergoing percutaneous coronary intervention using rivaroxaban in addition to dual antiplatelet therapy. *BMJ Case Rep.* 2016; 2016, doi: [10.1136/bcr-2016-217843](https://doi.org/10.1136/bcr-2016-217843), indexed in Pubmed: [27797850](https://pubmed.ncbi.nlm.nih.gov/27797850/).