

Syncope and right-sided heart failure due to right ventricular outflow tract obstruction by giant sinus of Valsalva aneurysm

Umut Kocabas¹, Guzin Zekican², Gulgun Vaiz², Naciye Ozbek², Cenk Conkbayır²

¹Department of Cardiology, Edremit State Hospital, Edremit, Balıkesir, Turkey

²Department of Cardiology, Dr. Burhan Nalbantoglu State Hospital, Nicosia, Cyprus

A 73-year-old man presented to the Emergency Department with symptoms of shortness of breath, peripheral edema and syncope. His previous medical history revealed hypertension and physical examination was significant for an elevated jugular venous pressure and peripheral edema. Cardiac auscultation revealed a systolic murmur at the second left intercostal space. Transthoracic and transoesophageal echocardiography showed a large right sinus of Valsalva aneurysm protruding into the right ventricular outflow tract with systolic gradients of 78 mm Hg

(Fig. 1A–C), dilated right ventricle and atrium with right ventricular systolic dysfunction (Fig. 1D), flattening of the interventricular septum (D-shaped left ventricle) due to significant right ventricular overload (Fig. 1E), moderate aortic regurgitation and moderate tricuspid regurgitation. An aortography demonstrated the presence of giant, unruptured right sinus of Valsalva aneurysm originating from the right coronary cusp (Fig. 1F). The patient underwent repair of the sinus of Valsalva. After Valsalva sinus repair, intraoperative transesophageal

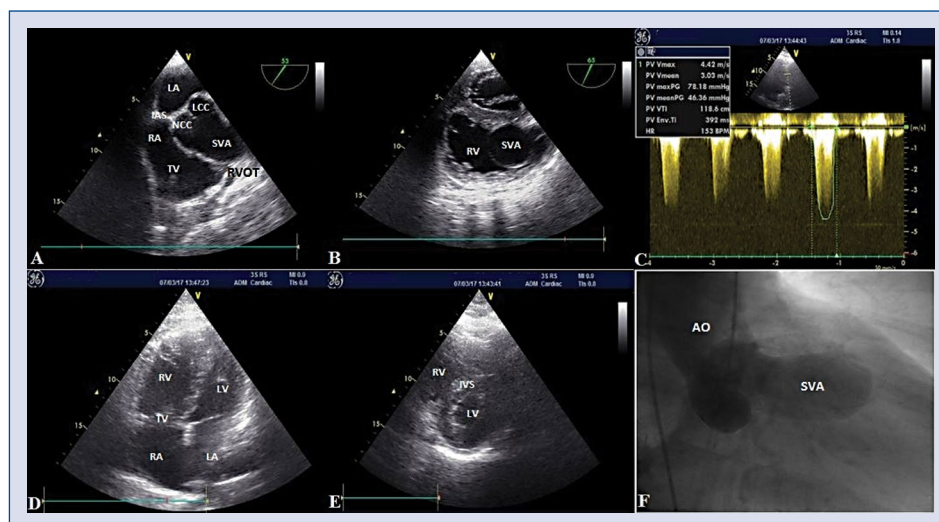


Figure 1. Transoesophageal echocardiography demonstrating a large right sinus of Valsalva aneurysm (SVA) protruding into the right ventricular outflow tract (RVOT) in the short axis view (A, B), transthoracic echocardiography showing RVOT obstruction in the parasternal short axis view on continuous wave Doppler (C), transthoracic echocardiography showing dilated right ventricle (RV) and right atrium (RA) in the apical-4-chamber view (D) and D-shaped left ventricle (LV) in the parasternal short axis view (E), aortography demonstrating a giant right SVA (F); AO — aorta; IAS — interatrial septum; IVS — interventricular septum; LA — left atrium; NCC — non-coroner cusp; LCC — left-coroner cusp; TV — tricuspid valve.

Address for correspondence: Umut Kocabas, MD, Department of Cardiology, Edremit State Hospital, Balıkesir, 10300, Turkey, tel: +90 507 997 4999, fax: +90 266 373 13 13, e-mail: umutkocabas@hotmail.com

Received: 15.07.2017

Accepted: 01.11.2017

geal echocardiography revealed moderate-to-severe aortic regurgitation, so the patient underwent aortic valve replacement and was discharged from hospital without any complications.

In this report, a case of right sinus of Valsalva aneurysm was described and its rare complications such as syncope and right-sided heart failure due to right ventricular outflow tract obstruction was documented.

Conflict of interest: None declared