

First report on biventricular stress cardiomyopathy with concomitant atrio-ventricular high-grade conduction disorder

Beata Morawiec^{1,2}, Sophie Degrauwe¹, Juan Fernando Iglesias¹, Olivier Muller¹

¹Department of Heart and Vessels, Service of Cardiology,
Lausanne University Hospital, Lausanne, Switzerland

²2nd Department of Cardiology, School of Medicine with the Division of Dentistry, Zabrze,
Medical University of Silesia, Katowice, Poland

Stress cardiomyopathy (takotsubo cardiomyopathy [TTC]) is an acute cardiac syndrome mimicking acute coronary syndrome (ACS) characterized by typical systolic dysfunction of left ventricle. Right ventricular involvement has been previously reported and represents an important predictor of adverse clinical outcomes. Biventricular involvement occurs in approximately one third of patients [1]. Atrio-ventricular (AV) block complicating TTC occurs in only 5% of patients [2]. Association of biventricular TTC, complete AV block and cardiogenic shock presenting as ACS is extremely rare and has never been reported to date.

This study reports a case of an 82-year-old female known to have diabetes mellitus type II as well as CHILD B hepatic cirrhosis on beta-blocker treatment for oesophageal varices and was admitted to the Emergency Department for typical chest pain at rest and vasovagal syncope. Third degree AV block with high ventricular escape was noted on 12-lead electrocardiogram (Fig. 1A). Laboratory results showed an elevation of high-sensitivity cardiac troponin from 130 ng/L to 450 ng/L as well as N-terminal pro B-type natriuretic peptide (NT-proBNP) elevation (3905 ng/L). During admission patient developed severe arterial hypotension, bradycardia, and cardiogenic shock. Urgent coronary angiography for very high-risk non-ST-segment elevation ACS was performed and demonstrated unobstructed coronary arteries. Severe biventricular systolic dysfunction with biventricular apical ballooning was noted on ventriculography (Fig. 1B; [Supplementary Movie 1 and 2 — see](#)

[journal website](#)). Transthoracic echocardiogram demonstrated severe left ventricular systolic dysfunction (ejection fraction [EF] 25%) with apical ballooning as well as severe right ventricular systolic dysfunction with apical ballooning (Fig. 1C; [Supplementary Movie 3 and 4 — see journal website](#)). Cardiac magnetic resonance examination performed at day 8 demonstrated non-dilated left ventricle with preserved systolic function (EF 55%) and discrete residual apical hypokinesia. The right ventricle also showed a recovery of systolic function and complete regression of dilation (Fig. 1D; [Supplementary Movie 5 — see journal website](#)). However, the patient presented persistent high-degree AV block requiring temporary endovenous pacing and finally implantation of a dual-chamber pacemaker at day 10. The patient was discharged on day 12 on enalapril, sitagliptin/metformin and simvastatin. At one one-year follow-up patient had remained free from cardiovascular symptoms and adverse cardiac events, though there was persistent high-degree AV block. Control echocardiogram demonstrated preserved left ventricular function (EF 60%) without wall motion abnormalities.

Despite numerous known triggers [3–5], the underlying pathophysiological mechanism of timely stunned myocardium and AV conduction damage remains unclear. Whether AV blocks are the cause or consequence of TTC is still a matter of debate. The persistence of AV conduction disorders in the setting of transient left ventricle dysfunction inclines reconsideration

Address for correspondence: Olivier Muller, MD, PhD, Department of Cardiology, Lausanne University Hospital (CHUV), Rue du Bugnon 46, 1011 Lausanne, Switzerland, tel: +41 21 314 00 10, fax: +41 21 314 00 13, e-mail: olivier.muller@chuv.ch

Received: 20.10.2016

Accepted: 31.10.2016

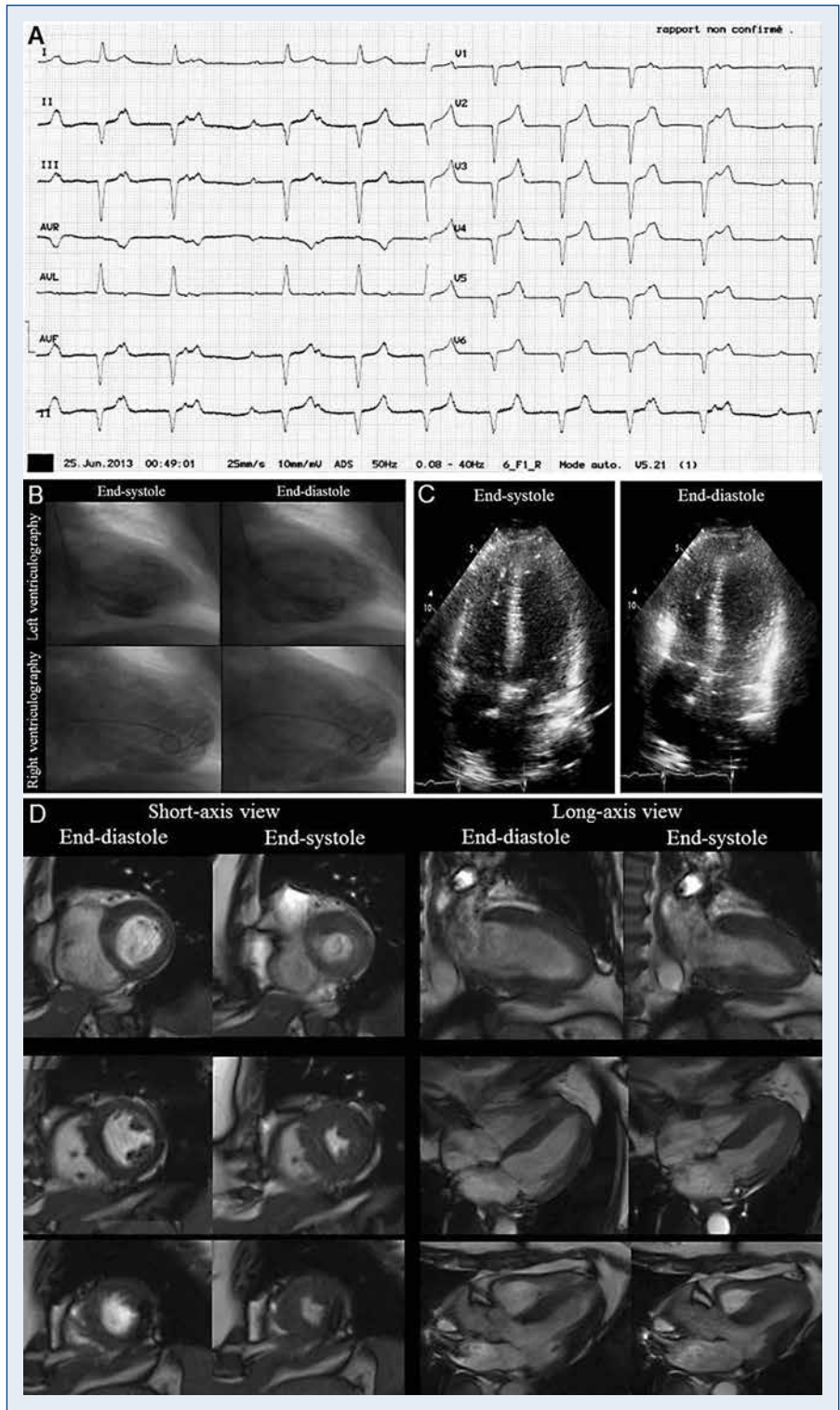


Figure 1. Admission and follow-up images; **A.** Electrocardiogram at admission: II° atrioventricular (AV) block type Mobitz I progressing to III° AV block, Q waves in all precordial and inferior leads, without modification of ST-T segment; **B.** Ventriculography: Left (upper images) and right (lower images) ventricle in systole (left) and diastole (right); Severe biventricular systolic dysfunction with biventricular apical ballooning; **C.** Transthoracic echocardiogram at admission (apical 4-chamber view): severe left ventricular systolic dysfunction (ejection fraction [EF] 25%) with apical ballooning; Severe right ventricular systolic dysfunction with apical ballooning; **D.** Cardiac magnetic resonance at day 8 (short- and long-axis views): Cine views with non-dilated left ventricle with preserved systolic function (EF 55%) and discrete residual apical hypokinesia; Non-dilated right ventricle with preserved systolic function.

of the pathophysiology in TTC [6]. Apart from the favorable prognosis in most cases of TTC, all complications of acute myocardial infarction may be anticipated. Based on our first report in the literature on TTC with biventricular involvement and complete AV block, and despite gaining complete recovery of the biventricular systolic function which is characteristic for TTC, a high-degree AV block may persist and may require definitive pacemaker implantation. However, optimal management of high-degree AV block associated with TTC warrants further research and still remains to be determined.

Conflict of interest: None declared

References

1. Elesber AA, Prasad A, Bybee KA et al. Transient cardiac apical ballooning syndrome: prevalence and clinical implications of right ventricular involvement. *J Am Coll Cardiol*, 2006; 47: 1082–1083.
2. Inoue M, Kanaya H, Matsubara T, Uno Y, Yasuda T, Miwa K. Complete atrioventricular block associated with takotsubo cardiomyopathy. *Circ J*, 73: 589–592.
3. Schlossbauer SA, Ghadri JR, Cammann VL, Maier W, Lüscher TF, Templin C. A broken heart in a broken car. *Cardiol J*, 2016; 23: 352–354. doi: 10.5603/CJ.2016.0034.
4. Ghadri JR, Sarcon A, Diekmann J et al.; InterTAK Co-investigators. Happy heart syndrome: role of positive emotional stress in takotsubo syndrome. *Eur Heart J*, 2016 Mar 2. pii: ehv757. [Epub ahead of print].
5. Said SM, Saygili E, Rana OR et al. Takotsubo Cardiomyopathy: What we have learned in the last 25 years? A comparative literature review. *Curr Cardiol Rev*, 2016 Feb 11. [Epub ahead of print].
6. Madhavan M, Prasad A. Proposed Mayo Clinic criteria for the diagnosis of Tako-Tsubo cardiomyopathy and long-term prognosis. *Herz*, 2010; 35: 240–244.