

The influence of anti-TNF therapy on CD31 and VEGF expression in colonic mucosa of Crohn's disease patients in relation to mucosal healing

Piotr Eder¹, Liliana Lykowska-Szuber¹, Katarzyna Iwanik², Iwona Krela-Kazmierczak¹, Kamila Stawczyk-Eder¹, Przemyslaw Majewski², Krzysztof Linke¹, Elaine W. Kay³, Aldona Wozniak²

¹Department of Gastroenterology, Human Nutrition and Internal Diseases, Poznan University of Medical Sciences, Heliodor Swiecicki Hospital, Poznan, Poland

²Department of Clinical Pathomorphology, Poznan University of Medical Sciences, Heliodor Swiecicki Hospital, Poznan, Poland

³Department of Histopathology, Beaumont Hospital and Royal College of Surgeons in Ireland, Dublin, Ireland

Abstract

Introduction. Immune-mediated angiogenesis may play an important role in the pathogenesis of inflammatory lesions in Crohn's disease (CD). The study aimed to assess the influence of anti-tumour necrosis factor (anti-TNF) therapy on the angiogenesis in relation to microscopic and endoscopic healing in CD patients.

Material and methods. Colonic tissue samples from 17 CD patients were taken during colonoscopy before and after anti-TNF therapy. Endoscopic and microscopic severities were estimated using validated scores. Immunohistochemical expression of CD31 and vascular endothelial growth factor (VEGF) were assessed in parallel.

Results. The expression of CD31 and VEGF decreased significantly after the anti-TNF therapy in parallel to endoscopic improvement; however, the microscopic activity did not change significantly. There was a correlation between the change in CD31 and VEGF expression ($p = 0.01$; $r = 0.6$), as well as endoscopic healing ($p = 0.04$; $r = 0.4$). CD31 immunoexpression correlated with the number of poly- and mononuclear cells in the infiltrates in the mucosal lamina propria before the therapy ($p = 0.02$; $r = 0.5$).

Conclusions. We suggest that modulation of vascular proliferation can be a novel option to increase the efficacy of biological therapy in CD. (*Folia Histochemica et Cytobiologica* 2016, Vol. 54, No. 2, 75–80)

Key words: Crohn's disease; anti-TNF therapy; CD31; VEGF; angiogenesis; IHC

Introduction

Anti-tumour necrosis factor alpha (anti-TNF) therapy in Crohn's disease (CD) modulates the pathological inflammatory processes in the gut wall, providing

tissue repair and mucosal healing. However, direct mechanisms of these phenomena are not known [1]. Surprisingly, according to current data, it seems that the most important pathways induced by these novel, powerful and clinically effective drugs are not directly related to TNF neutralization [2, 3].

Immune-mediated angiogenesis in the intestinal tissues is believed to be one of the driving forces of inflammatory infiltrations and histological lesions in the gut in CD. On the other side, multiple pro-inflammatory mediators induced during inflammation promote pathological angiogenesis. Thus inflammation and angiogenesis seem to be directly interrelated processes in CD pathogenesis [4–7].

Correspondence address: P. Eder, M.D., Ph.D.
Department of Gastroenterology, Human Nutrition and Internal Diseases
Poznan University of Medical Sciences
Heliodor Swiecicki Hospital
Przybyszewskiego 49, 60–355 Poznan, Poland
e-mail: piotr.eder@op.pl
tel.: +48 698 050 797, fax: +48 61 869 16 86

The exact influence of anti-TNF antibodies on intestinal angiogenesis is still being investigated. It is not well known whether modulation of enhanced angiogenesis during therapy is associated with microscopic healing. It also remains to be elucidated which parameters of microscopic activity in CD can be hypothetically more closely related to the change in immune-mediated angiogenesis in patients treated with anti-TNF agents.

In the present study we measured the intensity of mucosal vessel proliferation by detecting the immunocytochemical expression of CD31 (platelet endothelial cell adhesion molecule — PECAM-1) in colonic biopsy specimens before and after anti-TNF therapy in CD patients. In parallel to that we also assessed the expression of vascular endothelial growth factor (VEGF) — the strongest angiogenesis-promoting protein, as well as the microscopic activity by using a validated histological score.

The main aim of our study was to evaluate the influence of anti-TNF induction therapy in CD on the immune-mediated angiogenesis in relation to microscopic and endoscopic healing.

Material and methods

Patients. CD patients (12 females and 5 males, aged 32 ± 10 years, mean ± standard deviation) treated with induction doses of anti-TNF antibodies, infliximab (IFX) or adalimumab (ADA) were enrolled into the study. The study was approved by a local Ethics Committee and the informed consent was obtained from each patient.

Inclusion criteria were as follows: clinical exacerbation of CD not responding to maximal doses of standard therapy (steroids, mesalamine, thiopurines), full colonoscopy performed before and after induction anti-TNF therapy, clinically successful application of induction anti-TNF therapy defined as a decrease in CDAI by 100 points, ileocolonic or colonic CD localization. Exclusion criterion was the change in the concomitant therapeutic regimen during the induction doses of anti-TNF agents and primary non-response to the therapy. Disease activity was assessed twice — before enrolment and at the end of the induction period of anti-TNF treatment, *i.e.* 10–12 weeks after starting the biological therapy. Clinical activity was estimated by using the Crohn's Disease Activity Index (CDAI), endoscopic severity was graded according to the Simple Endoscopic Score for Crohn's Disease (SES-CD) by an experienced endoscopist [8, 9]. During colonoscopy, multiple biopsies were taken for further analyses from each affected segment of the colon (caecum and ascending colon, transverse colon, descending colon, sigmoid colon and rectum, if appropriate).

Tissue processing and the assessment of microscopic CD activity. All specimens were stained with haematoxylin and eosin (HE) and the microscopic activity was assessed by the validated score created by D'Haens et al. [10]. This score takes into account the most important features of histological lesions detected in CD: epithelial damage (0–2 points), architectural changes (0–2 points), infiltration of mononuclear cells in the lamina propria (0–2 points), infiltration of polymorphonuclear cells in the lamina propria (0–3 points), presence of polymorphonuclear cells in epithelium (0–3 points), presence of erosions and/or ulcers (0–1 points), presence of granulomas (0–1 points) and the number of biopsy specimens affected (0–3 points). The final score is the sum of all variables in specimens taken from all affected colonic segments divided by the number of segments.

Immunohistochemistry and image analyses. Immunohistochemistry has been carried out on representative sections using a Dako automated immunostainer (Dako Autostainer Link 48, AS 48430, Dako, Glostrup, Denmark) according to the manufacturer's recommendations and standard protocols. Briefly, the paraffin embedded 4 µm-thick sections of formalin-fixed tissue samples were deparaffinised (PT-Link, Dako PT10530). Antigen retrieval (PT-Link, Dako PT10530) was performed using the Dako Target Retrieval Solution, High pH. Tissue sections were incubated with a mouse monoclonal antibody against VEGF (1:50; clone 26503, R & D, Minneapolis, MN, USA) and with a mouse monoclonal antibody against CD31 (1:30; clone QBEnd 10, Dako). The EnVision Flex HRP (Dako) and EnVision Flex Substrate Buffer (Dako) were used for detection, employing 3,3'-diaminobenzidine (DAB) as the chromogen. The sections were counterstained with haematoxylin and mounted. Positive control tissue with high vessels density (kidney) was used as recommended by the suppliers whereas exclusion of the primary antibody served as negative control.

After immunostaining, all stained colonic sections were analysed. Two independent pathologists in a blinded manner counted all microvessels and cells positive for CD31 in the inflamed lamina propria in ten areas of most intense vascularization (the 'hot spots') at ×400 total magnification. The mean values of the vessel count evaluated by CD31 expression were calculated in every case as the arithmetic mean of ten counted areas.

VEGF-positive cells were evaluated by the same pathologists in a blinded manner and the results were expressed using a semiquantitative score. The extent of VEGF staining was assessed as a percentage of positively stained areas (1: 0–20%; 2: 21–40%; 3: 41–75%; 4: 76–100%) within the tissue. VEGF staining intensity was graded as weak (1: +), moderate (2: ++), or strong (3: +++), using an arbitrary scale. By adding the percentage expression to the intensity of staining the staining index was calculated with values between 2 and 7.

Table 1. Immunohistochemical expression of CD31 and Vascular Endothelial Growth Factor (VEGF) in colonic biopsies and selected biochemical, clinical and morphological parameters before and after anti-TNF therapy of Crohn's disease patients

	Before anti-TNF therapy	After anti-TNF therapy	P
CD31 (the mean number of CD31-positive microvessels in colonic lamina propria)	24 (IQR: 21–29)	14 (IQR: 11–18)	< 0.0001
VEGF (the final result is the sum of the percentage of positively stained areas and VEGF staining intensity in colonic lamina propria)	5 (IQR: 4–6)	2 (IQR: 2–2)	< 0.0001
CD ^a activity index	266 (IQR: 190–352)	63 (IQR: 37–129)	< 0.0001
Simple Endoscopic Score for CD ^a	14 (IQR: 9–20)	4 (IQR: 3–5)	0.0005
C-reactive protein [mg/L]	31.27 ± 26.34	16.88 ± 23.57	0.001
ESR ^b [mm/h]	39 ± 19	20 ± 19	0.009
RBC ^c (10 ⁶ /mm ³)	4.31 ± 0.69	4.13 ± 0.57	0.63
Haemoglobin [g/dL]	11.32 ± 2.31	11.62 ± 2.46	0.23
Haematocrit (%)	35 ± 6	35 ± 7	0.46
Platelets (10 ³ /mm ³)	394 ± 116	323 ± 132	0.01
WBC ^d (10 ³ /mm ³)	6.94 ± 2.68	5.94 ± 1.91	0.17
Fibrinogen [mg/dL]	514 ± 124	327 ± 150	0.003
Microscopic activity — D'Haens score (total)	6.33 ± 3.59	5.53 ± 4.19	0.34
Epithelial damage	0.41 ± 0.5	0.05 ± 0.1	0.1
Architectural changes	1.22 ± 0.9	0.9 ± 0.9	0.4
Mononuclear cells in LP ^e	1.63 ± 1.21	0.65 ± 0.81	0.03
Polymorphonuclear cells in LP ^e	2.44 ± 0.67	1.47 ± 1.32	0.01
Mono- and polymorphonuclear cells in LP ^e propria	4.04 ± 1.7	2.01 ± 2	0.006
Polymorphonuclear cells in epithelium	1.1 ± 0.82	0.8 ± 0.71	0.1
Erosions/ulcers	0.33 ± 0.41	None	0.01
Granulomas	0.09 ± 0.2	None	0.5
Number of biopsy specimens affected	2.61 ± 1.41	2.62 ± 1.65	0.5

Data are presented as medians with interquartile ranges (IQR) or mean ± standard deviation (SD). ^aCD — Crohn's disease; ^bESR — erythrocyte sedimentation rate; ^cRBC — red blood cell count; ^dWBC — white blood cell count; ^eLP — lamina propria.

Statistical analysis. All data were analysed by the GraphPad Prism Version 6.0 program (GraphPad Software Inc., La Jolla, CA, USA) using non-parametric statistics for paired (Wilcoxon test) or unpaired (Mann-Whitney U test) data, as appropriate. Categorized data were assessed with the Fisher's exact test. Correlations were assessed with the use of Spearman's rank correlation coefficient. A p value < 0.05 was considered significant.

Results

Clinical, endoscopic, and biochemical activity of Crohn's disease

17 CD patients were included in the study (12 females and 5 males; age 32 ± 10 years, mean ± SD). The mean disease duration was 7 ± 5 years. The character-

istics of the study group in terms of clinical, endoscopic, and biochemical activity before and after induction of anti-TNF therapy is shown in Table 1. Biological therapy resulted in a significant decrease of CD clinical and endoscopic activity assessed by CDAI and SES-CD indexes, respectively. The sensitive inflammatory laboratory markers, like C-reactive protein (CRP), and erythrocyte sedimentation rate (ESR), fibrinogen, and platelets, also decreased significantly (Table 1). Although the total microscopic activity did not change, a detailed analysis of the score's components showed a significant decrease in the number of mononuclear- and polymorphonuclear cells in the mucosal lamina propria, as well as a decrease in the number of erosions/ulcers in biopsy specimens after the anti-TNF therapy (Table 1).

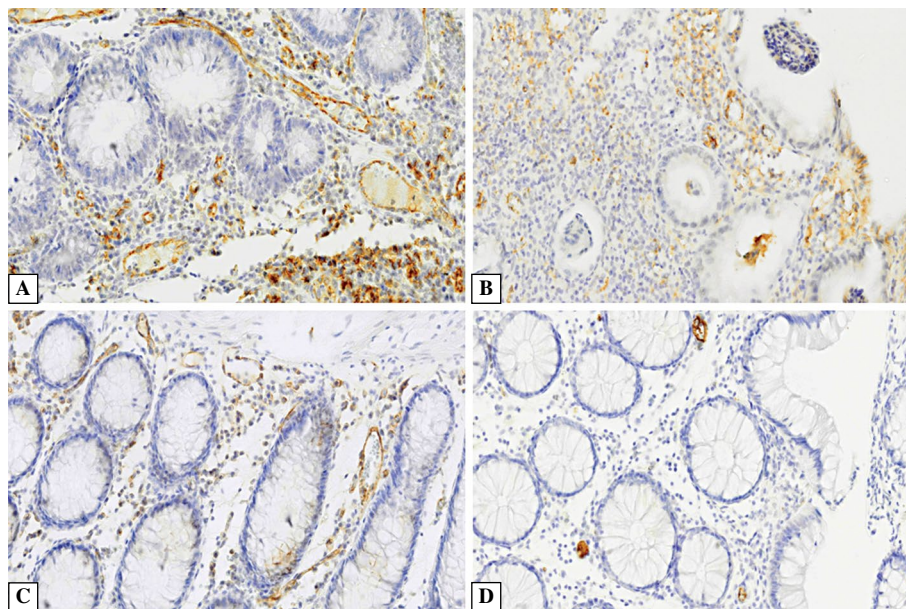


Figure 1. Immunohistochemical expression of CD31 and vascular endothelial growth factor (VEGF) before and after anti-tumour necrosis factor therapy in colonic biopsies from Crohn's disease patients (CD31: A and C, VEGF: B and D, respectively). Sections were counterstained with haematoxylin. Original magnification $\times 400$.

Immunohistochemical expression of CD31 and VEGF in mucosal biopsies

On immunohistochemistry CD31 expression was observed in all sections from inflamed colonic mucosa, both before and after anti-TNF treatment. The anti-CD31 antibody selectively labelled endothelial cells and microvessels in the colon lamina propria (Figure 1A, C). On the contrary, VEGF was weakly expressed by vascular endothelium but intense VEGF immunoreactivity was present in the infiltrating inflammatory cells. VEGF was widely expressed in the lamina propria cells before anti-TNF therapy and only focally after the treatment (Figure 1B, D). Median immunoreactivity of both CD31 and VEGF in colonic specimens decreased significantly after finishing the induction phase of biological therapy.

Significant correlation between the change in CD31 and VEGF immunoreactivity before and after anti-TNF treatment (Δ CD31/ Δ VEGF: $p = 0.01$; $r = 0.6$) was found. The decrease in CD31 expression was also significantly associated with the improvement in endoscopic activity (Δ CD 31/ Δ SES-CD: $p = 0.04$; $r = 0.4$). We did not find, however, any direct correlations between CD31 and VEGF expression, and CD31 immunoreactivity and SES-CD score.

Microscopic activity assessed globally did not correlate with neither CD31 nor VEGF immunoreactivity, however, in case of CD31 expression and histological assessment before anti-TNF therapy the

correlation was of a borderline significance ($p = 0.06$; $r = 0.4$). Analysis of the components of microscopic activity revealed that CD31 immunoreactivity was significantly associated with the number of poly- and mononuclear cells assessed together in the inflammatory infiltrates in the mucosa before commencement of the anti-TNF therapy ($p = 0.02$; $r = 0.5$).

Discussion

CD31 is a protein found mainly on endothelial cells (EC), platelets, monocytes and granulocytes [11]. It is believed that the intensity of CD31 expression reflects the degree of angiogenesis, especially in neoplastic tissues [11, 12]. In our study we confirmed that CD31 is also highly expressed on EC in intestinal biopsies taken from inflamed mucosa of CD patients. This phenomenon correlated with a number of poly- and mononuclear cells in the inflammatory infiltrates in the mucosa. This suggests that angiogenesis is one of the driving forces of inflammation in CD, as the presence of numerous proliferating small vessels enables the migration of mononuclear cells from the intravascular space to the intestinal tissue what promotes tissue inflammation and damage. This is in accordance with novel therapeutic strategies in inflammatory bowel diseases (IBD), in which the blockade of the aforementioned phenomena is believed to be one of the most powerful therapeutic options [13, 14]. In 2014 vedolizumab, a monoclonal antibody blocking

the $\alpha 4\beta 7$ -integrin, was approved by the Food and Drug Administration. Vedolizumab interferes with the interaction between gut-selective $\alpha 4\beta 7$ -integrin on leukocytes and mucosal addressin cellular adhesion molecule-1 (MadCAM-1) on endothelial cells [15] what down-regulates the migration of leukocytes to the intestinal lamina propria and provides histological improvement [16].

Interestingly, VEGF expression did not correlate in our study group with that of CD31, although VEGF is believed to be one of the most potent pro-angiogenic factors [16–18]. In an active inflammatory milieu, however, there is an elevation of concentration of multiple pro-inflammatory cytokines, like TNF- α , interleukin-1 (IL-1), transforming growth factor beta (TGF- α), several other growth factors, and other mediators (like hypoxia inducible factor-1, HIF-1) which indirectly (*via* VEGF) or directly promote angiogenesis [16]. Thus, vessel proliferation in CD is stimulated by a complicated network of several molecules, rather than by single proteins, although VEGF still plays a key role in angiogenesis. Moreover, our recent finding, showing that serum VEGF not only correlates with CD clinical activity, but also can be helpful in predicting the efficacy of anti-TNF therapy, supports morphological observations presented in this study [19].

Anti-TNF treatment rapidly dampens the activated and uncontrolled inflammatory processes in intestinal mucosa in IBD [20]. One can hypothesize that down-regulation of immune-stimulated angiogenesis is essential for the therapeutic efficacy of biological therapy. To the best of our knowledge, we showed for one of the first times that in CD patients responding to the treatment there is a significant reduction of CD31-positive endothelial cells in biopsy specimens taken from inflamed colon mucosa. Thus, administration of the anti-TNF agent decreases mucosal vessel proliferation. Moreover, the change in CD31 expression correlated with mucosal healing (MH) assessed endoscopically. This is important from the practical point of view, as it was shown that MH has the strongest positive predictive value for long-term efficacy of anti-TNF therapy [21]. Thus, it seems that down-regulation of immune-mediated angiogenesis is at least partially responsible for endoscopic improvement and clinical effectiveness of biological therapy in CD. We also observed a significant decrease in VEGF expression after induction anti-TNF therapy, which correlated with a reduction in CD31 expression. Thus, although, as it was discussed above, CD31 and VEGF did not correlate before and after the treatment, they were significantly associated when assessed dynamically in the course of biological therapy. It can be speculated that this observation is related to the

involvement of both proteins in the same angiogenesis-regulating phenomena, which were influenced by anti-TNF antibodies.

Interestingly, although there was a significant decrease in CD31 and VEGF expression, the index of microscopic activity only slightly improved after anti-TNF therapy. It can be hypothesized, however, that down-regulation of angiogenesis in the colon mucosa is one of the first steps in histological healing in CD. As the inflammatory tissue lesions seen in CD are often chronic and very complex, it may take some time to obtain profound improvement also on the cellular and histological level [22].

As it was mentioned above, the reduction of vascular proliferation in CD is probably indirectly related to the decrease of several pro-inflammatory and pro-angiogenic mediators after administration of anti-TNF antibodies. Taking into account the importance of angiogenesis in the etiology of CD, it could be hypothesized that a more direct inhibition of vascular proliferation together with anti-inflammatory effects of anti-TNF agents, could improve therapeutic outcomes. In accordance with this hypothesis, Kanakaraj et al. showed that application of a bispecific antibody, containing an angiopoietin-2 targeting peptide genetically fused to adalimumab, the anti-TNF antibody, in transgenic mouse model of arthritis, reduced both clinical and histological scores significantly better when compared with adalimumab alone [23]. It is not possible to translate these observations directly into patients with CD; nevertheless, this approach may present a next step in therapeutic strategies of chronic inflammatory disorders in the future, after critical assessment of its safety and costs.

In summary, the current study showed that standard anti-TNF therapy has a strong potential to down-regulate angiogenesis in the intestinal mucosa of CD patients, when assessed on the histological level, which is accompanied with clinical and endoscopic improvement. As the vascular proliferation seems to be one of the important pathomechanisms for inflammatory activity of CD, it is essential to search for new drugs affecting these processes in order to improve the efficacy of therapeutic interventions in this incurable gastrointestinal disease.

References

1. Tracey D, Klareskog L, Sasso EH et al. Tumor necrosis factor antagonist mechanism of action: a comprehensive review. *Pharmacol Ther.* 2008;117:244–279. doi: [10.1016/j.pharmthera.2007.10.001](https://doi.org/10.1016/j.pharmthera.2007.10.001).
2. Oikonomopoulos A, van Deen WK, Hommes DW. Anti-TNF antibodies in inflammatory bowel disease: do we finally know how it works? *Curr Drug Targets.* 2013;12:1421–1432. doi: [10.2174/13894501113149990164](https://doi.org/10.2174/13894501113149990164).

3. Neurath M. New targets for mucosal healing and therapy in inflammatory bowel disease. *Mucosal Immunol.* 2014;7:6–19. doi: [10.1038/mi.2013.73](https://doi.org/10.1038/mi.2013.73).
4. Koutroubakis IE, Tsiolakidou G, Karmiris K et al. Role of angiogenesis in inflammatory bowel disease. *Inflamm Bowel Dis.* 2006;12:515–523. doi: [10.1097/00054725-200606000-00012](https://doi.org/10.1097/00054725-200606000-00012).
5. Algaba A, Linares PM, Fernandez-Contreras ME et al. Relationship between levels of angiogenic and lymphangiogenic factors and endoscopic, histological and clinical activity, and acute-phase reactants in patients with inflammatory bowel disease. *J Crohns Colitis.* 2013;11:569–579. doi: [10.1016/j.crohns.2013.04.005](https://doi.org/10.1016/j.crohns.2013.04.005).
6. Kruschewski M, Buhr HJ. The vasculitis in IBD is associated with the degree of inflammation. *Dig Dis Sci.* 2010;3:733–738. doi: [10.1007/s10620-009-0763-y](https://doi.org/10.1007/s10620-009-0763-y).
7. Tsiolakidou G, Koutroubakis IE, Tzardi M, Kouroumalis EA. Increased expression of VEGF and CD146 in patients with inflammatory bowel disease. *Dig Liver Dis.* 2008;4:762–770. doi: [10.1016/j.dld.2008.02.010](https://doi.org/10.1016/j.dld.2008.02.010).
8. Best WR, Becktel JM, Singelton JW et al. Development of a Crohn's disease activity index. National Cooperative Crohn's Disease Study. *Gastroenterology.* 1976;70:439–444. doi: [10.1016/S0016-5085\(76\)80163-1](https://doi.org/10.1016/S0016-5085(76)80163-1).
9. Daperno M, D'Haens G, van Assche G et al. Development and validation of a new, simplified endoscopic activity score for Crohn's disease: the SES-CD. *Gastrointest Endosc.* 2004;60:505–512. doi: [10.1016/S0016-5107\(04\)01878-4](https://doi.org/10.1016/S0016-5107(04)01878-4).
10. D'Haens GR, Geboes K, Peeters M et al. Early lesions of recurrent Crohn's disease caused by infusion of intestinal contents in excluded ileum. *Gastroenterology.* 1998;114:262–267. doi: [10.1097/00042737-199804000-00022](https://doi.org/10.1097/00042737-199804000-00022).
11. Park S, Sorensen CM, Sheibani N. PECAM-1 isoforms, eNOS and endoglin axis in regulation of angiogenesis. *Clin Sci (London).* 2015;3:217–234. doi: [10.1042/CS20140714](https://doi.org/10.1042/CS20140714).
12. Jain RK. Normalization of tumor vasculature: an emerging concept in antiangiogenic therapy. *Science.* 2005;307:58–62. doi: [10.1126/science.1104819](https://doi.org/10.1126/science.1104819).
13. Antunes O, Filippi J, Hébuterne X et al. Treatment algorithms in Crohn's — up, down or something else? *Best Pract Res Clin Gastroenterol.* 2014;28:473–483. doi: [10.1016/j.bpg.2014.05.001](https://doi.org/10.1016/j.bpg.2014.05.001).
14. Rutella S, Fiorino G, Vetrano S et al. Infliximab therapy inhibits inflammation-induced angiogenesis in the mucosa of patients with Crohn's disease. *Am J Gastroenterol.* 2011;4:762–770. doi: [10.1038/ajg.2011.48](https://doi.org/10.1038/ajg.2011.48).
15. Gilroy L, Allen PB. Is there a role for vedolizumab in the treatment of ulcerative colitis and Crohn's disease? *Clin Expert Gastroenterol.* 2014;7:163–172. doi: [10.2147/CEG.S45261](https://doi.org/10.2147/CEG.S45261).
16. Eder P, Korybalska K, Linke K, Witowski J. Angiogenesis-related proteins — their role in the pathogenesis and treatment of inflammatory bowel disease. *Curr Protein Pept Sci.* 2015;16:249–258. doi: [10.2174/1389203716666150224150756](https://doi.org/10.2174/1389203716666150224150756).
17. Di Sabatino A, Ciccocioppo R, Armellini E et al. Serum bFGF and VEGF correlate respectively with bowel wall thickness and intramural blood flow in Crohn's disease. *Inflamm Bowel Dis.* 2004;10:573–577. doi: [10.1097/00054725-200409000-00011](https://doi.org/10.1097/00054725-200409000-00011).
18. Cibor D, Domagala-Rodacka R, Rodacki T et al. Endothelial dysfunction in inflammatory bowel diseases: pathogenesis, assessment and implications. *World J Gastroenterol.* 2016;22:1067–1077. doi: [10.3748/wjg.v22.i3.1067](https://doi.org/10.3748/wjg.v22.i3.1067).
19. Eder P, Korybalska K, Lykowska-Szuber L et al. Association of serum VEGF with clinical response to anti-TNF α therapy for Crohn's disease. *Cytokine.* 2015;76:288–293. doi: [10.1016/j.cyto.2015.09.018](https://doi.org/10.1016/j.cyto.2015.09.018).
20. Eder P, Lykowska-Szuber L, Krela-Kazmierczak I et al. Anti-TNF antibodies do not induce the apoptosis of lamina propria mononuclear cells in uninflamed intestinal tissue in patients with Crohn's disease. *Folia Histochem Cytobiol.* 2013;51:239–243. doi: [10.5603/FHC.2013.0034](https://doi.org/10.5603/FHC.2013.0034).
21. Walsh A, Palmer R, Travis S. Mucosal healing as a target of therapy for colonic inflammatory bowel disease and methods to score disease activity. *Gastrointest Endosc Clin N Am.* 2014;24:367–378. doi: [10.1016/j.giec.2014.03.005](https://doi.org/10.1016/j.giec.2014.03.005).
22. Magro F, Langner C, Driessen A et al. European consensus on the histopathology of inflammatory bowel disease. *J Crohns Colitis.* 2013;7:827–851. doi: [10.1016/j.crohns.2013.06.001](https://doi.org/10.1016/j.crohns.2013.06.001).
23. Kanakaraj P, Puffer BA, Yao XT et al. Simultaneous targeting of TNF and Ang2 with a novel bispecific antibody enhances efficacy in an *in vivo* model of arthritis. *MAbs.* 2012;4:600–613. doi: [10.4161/mabs.21227](https://doi.org/10.4161/mabs.21227).

Submitted: 23 September, 2015

Accepted after reviews: 16 May, 2016

Available as AoP: 6 June, 2016