

FOLIA HISTOCHEMICA  
ET CYTOBIOLOGICA  
Vol. 42, No. 3, 2004  
pp. 165-168

## Assessment of proliferative activity of thyroid Hürthle cell tumors using PCNA, Ki-67 and AgNOR methods

Albert Augustynowicz<sup>1</sup>, Janusz Dziecioł<sup>2</sup>, Małgorzata Barwijk-Machala<sup>3</sup>,  
Jacek Dadan<sup>4</sup>, Zbigniew Puchalski<sup>4</sup> and Stanisław Sulkowski<sup>3</sup>

<sup>1</sup>Department of Medical Pathomorphology, <sup>2</sup>Department of Anatomy, <sup>3</sup>Department of General Pathomorphology, and <sup>4</sup>1st Clinic of Surgery, Medical University, Białystok; Poland

**Abstract:** We have undertaken an attempt to compare the application efficacy of the proliferative activity markers in differential diagnosis of thyroid Hürthle cell tumors (HCT) using the PCNA and Ki-67 labeling and AgNOR visualisation techniques. The present work is a retrospective analysis of 78 Hürthle cell tumors: 20 Hürthle cell carcinomas (HCC), 32 Hürthle cell adenomas (HCA) and 26 hyperplastic nodules with Hürthle cell metaplasia (HCM). Five  $\mu\text{m}$  sections were stained according to AgNOR technique and labeled with antibodies against PCNA and Ki-67. AgNOR dot count in the nucleus and proliferative index (PI - percentage of cells expressing PCNA and Ki-67) in randomly chosen nuclei (100 in case of AgNOR and over 1000 in case of PI) were evaluated in each slide. The mean values of AgNOR dot count, PI-PCNA and PI-Ki-67 in HCC, HCA and HCM were respectively: 5.1, 61.3 and 54.9; 3.4, 42.4 and 38.6 and 2.5, 39.3 and 34.3. Statistically significant difference was found in all the proliferative activity markers between malignant and benign tumors: HCC:HCA ( $p < 0.01$ ) and HCC:HCM ( $p < 0.001$ ). There was no statistically significant difference between HCA and HCM.

**Key words:** Thyroid - Hürthle cell tumor - PCNA - Ki-67 - AgNOR

### Introduction

Lack of cytological features of malignancy makes differential diagnosis of follicular tumors of the thyroid difficult. The only diagnostic criterion is the presence of vascular or capsular invasion [6]. Reports on the surprisingly unfavourable clinical course of changes identified as adenomas provide strong evidence of difficulties encountered in the subjective evaluation of histological features of malignancy [4]. Hürthle cell tumors, a variant of follicular tumors, also referred to as oxyphilic tumors, which are composed of follicular cells with massive eosinophilic cytoplasm and whose origin has not been fully elucidated, are considered by many pathologists to have unpredictable clinical course and to be more aggressive compared to the other well differentiated follicular tumors of the thyroid. The oxyphilic tumors can be subdivided into oxyphilic carcinoma (Hürthle cell carcinoma - HCC), oxyphilic adenoma (Hürthle cell adenoma - HCA) and hyperplastic nodules with oxyphilic metaplasia (Hürthle cell metaplasia - HCM). Diffi-

culties in the evaluation of their behavior, malignancy and prognosis have prompted the search for methods which could be useful in diagnostics. Assessment of the proliferative activity markers based on immunohistochemical technique using antibodies against PCNA and Ki-67 is, according to many authors, valuable in the evaluation of malignancy of many neoplastic lesions [2]. Similar opinions refer to the possible use of the histochemical technique of Ploton *et al.* [9], based on the quantitative assessment of argyrophilic nuclear organizer regions (AgNORs) [10]. Although the reliability of both techniques seems to be commonly accepted, there are some controversial opinions concerning their value. Therefore we decided to compare the efficacy of these proliferative activity markers by using them in the same study group. Hürthle cell tumors, being a real diagnostic challenge in the pathologist's practice, were chosen as the object of the study. We hope that the data obtained will appear helpful in differential diagnosis of nodular oxyphilic lesions.

### Materials and methods

The study was carried out on 78 follicular tumors of the thyroid, diagnosed at the Department of Clinical Pathology, Medical University of Białystok in the years 1990-2003. Among 78 nodular lesions, there were 20 HCC, 32 HCA and 26 hyperplastic HCM nodules.

**Correspondence:** A. Augustynowicz, Dept. Medical Pathomorphology, Medical University, Waszyngtona 13, 15-269 Białystok, Poland; e-mail: [albertaugustynowicz@poczta.onet.pl](mailto:albertaugustynowicz@poczta.onet.pl)

**Table 1.** Proliferative activity markers in Hürthle cell tumors

	PCNA PI	Ki-67 PI	AgNOR count
Hürthle cell carcinoma	61.3 (72.1-49.8) <sup>1,2</sup>	54.9 (58.5-44.2) <sup>1,2</sup>	5.1 (6.7-3.5) <sup>1,2</sup>
Hürthle cell adenoma	42.4 (56.3-34.2)	38.6 (48.1-30.0)	3.4 (4.1-2.2)
Hürthle cell metaplasia	39.3 (52.8-31.3)	34.3 (45.7-29.4)	2.5 (3.3-2.0)

<sup>1</sup> - with HCA (p<0.01); <sup>2</sup> - with HCM (p<0.001); PI-proliferative index

Three sections 5 µm thick were made from each paraffin block routinely obtained following fixation in 10% buffered formalin. Staining was performed both by the one-step colloid silver impregnation method described by Ploton *et al.* [9] and using antibodies against PCNA (DAKO; monoclonal mouse, clone PC10 at a dilution 1:100) and Ki-67 (DAKO; monoclonal mouse, clone MIB-1 at the dilution 1:50) with EnVision TM (DAKO) detection kit.

The evaluation of the mean number of AgNOR dots per nucleus and the proliferative index (PI - the percentage of PCNA- and Ki-67-positive cells) was performed using two different methods. In order to assess the mean number of AgNOR dots per nucleus, 100 randomly selected cell nuclei were evaluated in each slide by two independent observers using Eclipse E 200 microscope at a magnification of × 1000, on the focusing plane with the highest number of distinctly contrasted argyrophilic granules. PI was determined using Lucia morphometric program, Minitron video camera and Eclipse E 200 microscope at a magnification of × 400 in ten randomly selected fields in each slide. The number of all cells per estimated field was automatically determined and the number of positively stained cell nuclei was counted semiautomatically after interactive pointing out. U-Mann-Whitney test was used for statistical analysis. The difference was considered significant for p<0.05.

## Results

The tumors analysed in our study were composed of cells with eosinophilic cytoplasm, the so called Hürthle cells (Fig. 1). The diagnosis of tumor malignancy, confirmed by two pathologists, was based on the presence of capsular or vascular invasion, while the presence of the capsule and normal or compressed tissue around the tumor was required to diagnose adenoma and to exclude hyperplastic cell tumors with oxyphilic metaplasia [6]. The specific granular, nuclear staining was present in cells with overexpression of PCNA or Ki-67. The thyroid tissue demonstrated diffuse, nonspecific, weak cytoplasmic reaction (Fig. 2a,b). The one-step silver colloid staining visualized the AgNORs as dark dots within cell nuclei (Fig. 2c).

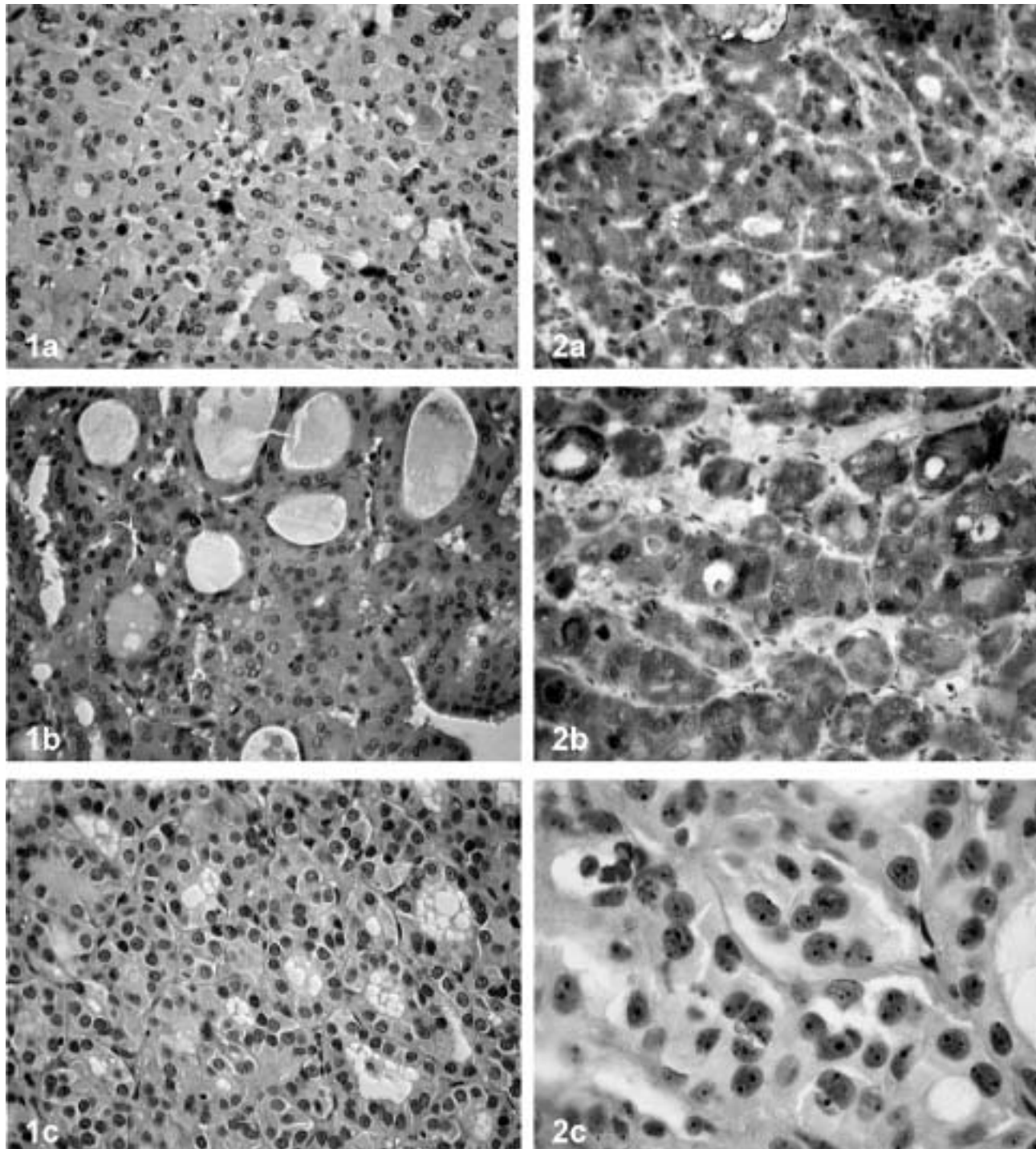
The values of PCNA PI and Ki-67 PI as well as the mean AgNOR counts in nuclei of Hürthle cell carcinomas, Hürthle cell adenomas and hyperplastic nodules with Hürthle cell metaplasia are presented in Table 1. They were the highest in malignant tumors and the lowest in non-neoplastic oxyphilic metaplasia. The values of PI were somewhat higher in the case of PCNA compared to Ki-67. Similar statistically significant differences were noticed for all methods used in our study between malignant and benign tumors: HCC:HCA (p<0.01) and HCC:HCM

(p<0.001). Irrespective of the proliferative activity marker examined, no statistically significant difference was found between oxyphilic adenoma and oxyphilic metaplasia. Non-diagnostic overlapping values between the groups were observed for all the methods.

## Discussion

It has been known for a long time that the more frequent division figures are found in the microscopic image of a tumor, the more aggressive is tumor behavior. No wonder that attempts have been made to assess the proliferative activity of tumors in the routine differential diagnosis of changes which are difficult to discriminate. Widely applied methods using routinely obtained paraffin blocks are based either on cheap and easily accessible immunohistochemical techniques evaluating the expression of PCNA and Ki-67 proliferation markers or on the histochemical AgNOR silver impregnation technique. These methods are commonly referred to as the markers of proliferative activity, and show a good correlation with precise research techniques used to assess the mitotic activity [2, 10, 12]. Are they exchangeable or universal? Can one of them be regarded as the best or the most convenient? We tried to find in our study the most precise marker of the proliferative activity of thyroid oxyphilic tumors.

Our results are consistent with the data concerning follicular tumors, particularly oxyphilic tumors of the thyroid. Most authors report that the expression of PCNA and Ki-67, and AgNOR count assessed in malignant and benign tumors of that type differ significantly [1, 2, 7, 10, 11, 12]. However, there are differences in the absolute values of PI obtained by immunohistochemical analysis in our own study compared to the literature data. Generally, the PI-PCNA and PI-Ki-67 values reported in the literature are lower: the mean index for PCNA was 6.6 in HCA, 19.1 in indeterminate HCT and 24.54 in HCC [11], and the respective values for Ki-67 were 10.0 in HCC, 3.2 in HCA and 5.0 in UMB (uncertain malignant behavior) [3]. The mean AgNOR counts in the nuclei according to the literature data are close to those obtained in our study, ranging from 5.8 to 4.5 for HCC and from 3.9 to 3.0 for HCA, although some authors did not find significant differences between



**Fig. 1.** Histological structure of Hürthle cell tumors: HCC (a), HCA (b) and HCM (c). H-E.  $\times 400$ . **Fig. 2.** Proliferative activity markers examined in Hürthle cell tumors: PCNA (a), Ki-67 (b) and AgNORs (c). a, b -  $\times 400$ ; c -  $\times 1000$ .

these groups [1]. No literature data are available on the proliferative activity of HCM.

A more detailed analysis and comparison of the obtained results with the literature data encounter serious difficulties, because of different methods of quantitative analysis and various ways of tumor

grouping. Determination of the proliferative index also differs among the investigators. The PI can be calculated as the percentage of positive cells per 100 evaluated cells or per different number of cells. It can also be assessed by the number of positively stained cells per the number of fields examined (High Power Field - HPF). It is

impossible to compare Ki-67 expression presented as 12/10HPF in oxyphilic adenoma and 76/10HPF in carcinoma [8] with the values obtained in our study. The observed discrepancies are also due to differences in division of tumors into groups. The most common is a division into benign and malignant tumors, *i.e.* carcinomas and adenomas, although a division into benign, suspected of malignancy and malignant tumors or benign, indeterminate, suspected of malignancy and malignant ones is also frequently used. Malignant carcinomas can still be subdivided into encapsulated, slightly infiltrative and extensively infiltrative, sometimes with vascular invasion. It happens that authors combine histologically different groups, which practically precludes comparison, *e.g.* in the study of Horii *et al.* [5], the values of Ki-67 were 39.9 and 9.4 for TCA (thyroid carcinoma) and TA (thyroid adenoma), respectively. Quite confusing is also the "score" system used in the study of Czyż *et al.* [2] to estimate the percentage of cases in which the number of PCNA-positive cells exceeds 5% (shown in 47% of carcinomas and 64% of adenomas). It seems that there are no standard methods to quantitatively estimate the proliferative activity of HCTs.

Irrespective of the correlation between our results and the literature data, it can be concluded that in the case of oxyphilic tumors of the thyroid divided into HCCA, HCA and HCM, the PCNA PI, Ki-67 PI and AgNOR count used as markers in the present study similarly reflect differences between the proliferative activity of the groups. According to most authors, however, the occurrence of non-diagnostic overlapping value intervals between the groups makes determination of these parameters only an adjunct to the differential diagnostics of malignant and benign oxyphilic tumors of the thyroid.

## References

- [ 1] Cor A (1999) Proliferative activity of Hürthle cell thyroid tumours. *Oncology* 57: 17-22
- [ 2] Czyż W, Joensuu H, Pylkkänen L, Klemi PJ (1994): p53 protein, PCNA staining, and DNA content in follicular neoplasms of the thyroid gland. *J Pathol* 174: 267-274
- [ 3] Erickson LA, Jin L, Goellner JR, Lohse C, Pankratz VS, Zukerberg LR, Thompson GB, van Heerden JA, Grant CS, Lloyd RV (2000) Pathologic features, proliferative activity, and cyclin D1 expression in Hürthle cell neoplasms of the thyroid. *Mod Pathol* 13: 186-192
- [ 4] Gundry S, Burney R, Thompson NW, Lloyd R (1983) Total thyroidectomy for Hürthle cell neoplasm of the thyroid. *Arch Surg* 118: 529-532
- [ 5] Horii A, Yoshida J, Sakai M, Okamoto S, Honjo Y, Mitani K, Hattori K, Kubo T (1999) Ki-67 positive fractions in benign and malignant thyroid tumours: application of flow cytometry. *Acta Otolaryngol* 119: 617-620
- [ 6] LiVolsi VA (1990) *Surgical pathology of the thyroid*. WB Saunders Co, Philadelphia
- [ 7] Mourad WA, Erkman-Balis B, Livingston S, Shoukri M, Cox CE, Nicosia SV, Rowlands DT (1992) Argyrophilic nucleolar organizer regions in breast carcinoma. Correlation with DNA flow cytometry, histopathology and lymph node status. *Cancer* 69: 1739-1744
- [ 8] Muller-Hocker J (1999) Immunoreactivity of p53, Ki-67, and Bcl-2 in oncocyctic adenomas and carcinomas of the thyroid gland. *Hum Pathol* 30: 926-933
- [ 9] Ploton D, Menager M, Jeannesson P, Himber G, Pigeon F, Adnet JJ (1986) Improvement in the staining and in the visualization of the argyrophilic proteins of the nucleolar organizer regions at the optical level. *Histochem J* 18: 5-14
- [10] Ruschoff J, Prasser C, Cortez T, Hohne HM, Hohenberger W, Hofstadter F (1993) Diagnostic value of AgNOR staining in follicular cell neoplasms of the thyroid: comparison of evaluation methods and nuclear features. *Am J Surg Pathol* 17: 1281-1288
- [11] Tateyama H, Yang YP, Eimoto T, Tada T, Inagaki H, Nakamura T, Iwase H, Koboyashi S (1994) Proliferative cell nuclear antigen expression in follicular tumours of the thyroid with special reference to oxyphilic cell lesions. *Virch Arch* 424: 533-537
- [12] Trere D, Farabegoli F, Cancellieri A, Cecallieri C, Eusebi V, Derenzini M (1991) AgNOR area in interphase nuclei of human tumors correlates with the proliferative activity evaluated by bromodeoxyuridine labelling and Ki-67 immunostaining. *J Pathol* 165: 53-59

*Accepted February 16, 2004*