

FOLIA HISTOCHEMICA
ET CYTOBIOLOGICA
Vol. 44, No. 3, 2006
pp. 185-188

Androgen receptor in early apoptotic follicles in the porcine ovary at pregnancy

Maria Słomczynska¹, Zbigniew Tabarowski², Małgorzata Duda¹, Małgorzata Burek¹, and Katarzyna Knapczyk¹

¹Laboratory of Endocrinology and Tissue Culture and ²Laboratory of Experimental Hematology, Institute of Zoology, Jagiellonian University, Kraków, Poland

Abstract: Localization of androgen receptor (AR) was investigated in ovarian follicles developing and undergoing atresia during pregnancy in the pig. Immunohistochemical staining was conducted on ovarian antral follicles isolated on different days of gestation: 10, 18, 32, 50, 70, and 90. Paraffin sections were also subjected to *in situ* DNA labeling. TUNEL staining revealed the presence of positive follicles on all days of pregnancy but the amount of atretic follicles increased with time. However, even on day 90 of gestation many follicles were normal, with no signs of atresia. In atretic follicles, apoptotic cells were localized predominantly in the granulosa while theca was much less affected. Atretic follicles with many apoptotic cells were negative for AR. Nuclear immunostaining for AR was positive in follicles with limited amount of apoptotic cells. The same relationship was observed in ovarian follicles isolated at various days of pregnancy.

Key words: Androgen receptor - Apoptosis - Atresia - Ovary - Pregnancy - Pig

Introduction

In mammalian ovaries more than 99% of follicles undergo a degenerative process known as atresia [10, 13, 24]. Less than 1% of all follicles present at birth mature and ovulate, while the others are eliminated. The total number of ovulations is an important parameter of the reproductive efficiency of farm animals (horses, cows, pigs). Factors directly or indirectly regulating ovulation rate have been studied by many investigators [12, 14, 23].

Recent studies have suggested that follicle atresia in chicken, porcine and rodent ovaries is demonstrated by the internucleosomal fragmentation of cellular DNA [1]. Therefore, the molecular mechanism of follicular atresia in porcine ovaries has been described [13] and reported to be dependent on granulosa cell apoptosis.

Many factors have been examined to reveal the role they play in granulosa cell apoptosis in porcine ovarian follicles [3, 11]. Earlier studies have shown that gonadotropins [9] and gonadal steroids [8] modulate the incidence of atresia in the ovary. The effects of estrogens and androgens on follicle apoptosis were described in

rat ovaries [1]. Follicular growth and atresia are known to affect the expression of androgen receptor and steroidogenic enzymes during the estrous cycle in pigs [5]. Distribution of androgen receptor in rat ovarian follicles undergoing atresia at the beginning of pregnancy was recently described [20]. Our previous investigation demonstrated the localization of AR in porcine ovaries obtained on different days of pregnancy [4]. The present study was performed to examine the distribution of AR in follicles undergoing atresia during pregnancy.

Materials and methods

Animals. Ovaries were obtained from pregnant pigs on days 10, 18, 32, 71 and 90 *post coitum*. For each investigated day of pregnancy, the material was collected from two animals and 10-20 follicles per ovary were used. All procedures involving animals were approved by the Animal Care and Use Committee.

The excised follicles were fixed in 4% paraformaldehyde, dehydrated in an increasing gradient of ethanol and processed through paraplant.

Immunohistochemistry. A polyclonal antibody against androgen receptors (NCL-Arp) was obtained from Novocastra Lab, Newcastle-upon-Tyne, UK. Secondary antibody, biotinylated goat anti-rabbit IgG, was from Vector Lab, Burlingame, CA, USA. Streptavidin-HRP complex was from Dako/AS, Denmark. Paraplant was purchased from Monoclonal Scientific Division of Scherwood Medical, St. Louis, MO, USA. DPX medium was from Fluka. All other chemicals were from Sigma-Aldrich. Immunohistochemistry

Correspondence: M. Słomczynska, Institute of Zoology, Jagiellonian University, Ingardena 6, 30-060 Kraków, Poland; e-mail: slom@zok.zuk.iz.uj.edu.pl

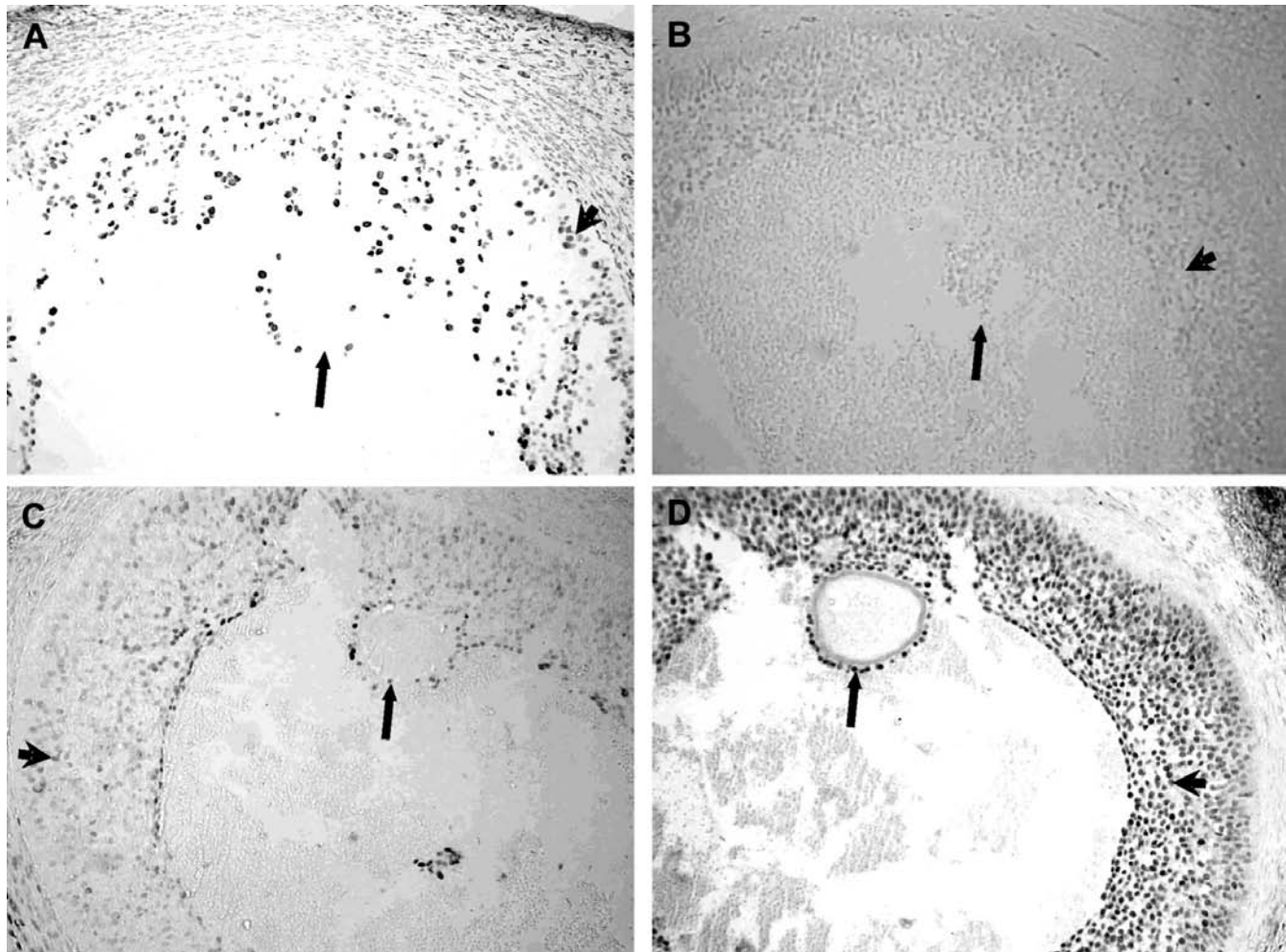


Fig. 1. Follicles obtained from the same porcine ovary from day 18 of pregnancy. TUNEL staining is shown in **A** and **C**, while expression of AR in **B** and **D**. Adjacent sections of the investigated follicle (**A**, **B**) show intense apoptosis (**A**) in cumulus (arrow) and granulosa cells (arrowhead) and no immunostaining for AR (**B**), neither in cumulus (arrow) nor in granulosa cells (arrowhead). In another follicle from the same ovary (**C**), almost no apoptotic cells are present (arrow, arrowhead) but very strong AR immunostaining (**D**) is observed (cumulus - arrow, granulosa cells - arrowhead). $\times 200$.

was performed as described in our earlier paper [18]. Briefly, sections were incubated overnight with anti-AR (1:10) antibody followed by biotinylated goat anti-rabbit IgG (1:400) and streptavidin-horseradish peroxidase complex (ABC/HRP; 1:100). The color reaction was developed in TBS buffer, pH 7.4, containing 0.01% H_2O_2 , 0.05% diaminobenzidine and 0.07% imidazole. The primary antibody was omitted or replaced by normal rabbit serum in control sections. The sections were carefully rinsed with Tris-buffered saline (TBS) pH 7.6 after each step of the described procedure. Slides were dehydrated and mounted in DPX.

In situ DNA labeling by TUNEL assay. The *in situ* DNA fragmentation was visualised by a modification of the TUNEL method [21]. Briefly, dewaxed tissue sections were predigested with 20 mg/ml proteinase K for 20 min and incubated in phosphate buffered saline solution (PBS) containing 3% H_2O_2 for 10 min to block the endogenous peroxidase activity. After incubating in 0.1% Triton X-100 in 0.1% sodium citrate for 2 min on ice, the sections were incubated with the TUNEL reaction mixture, fluorescein-dUTP (In Situ Cell Death Detection, POD kit, Roche, Germany), for 60 min at 37°C. The slides were then rinsed three times with PBS and incubated with secondary anti-fluorescein-POD-conjugate for 30 min. After washing three times in PBS, diaminobenzidine- H_2O_2 chromogenic reaction

was performed on sections followed by counterstaining with hematoxylin. As a control for method specificity, the step using the TUNEL reaction mixture was omitted in negative control sections, and nucleotide mixture in reaction buffer was used instead.

Results

The ovaries of pigs on various days of pregnancy contained follicles at different stages of development and atresia. The presence of apoptotic cells in the granulosa and theca interna layers of some follicles was demonstrated histochemically by the TUNEL-method on all investigated days of pregnancy. Follicles in which many granulosa cells were apoptotic (Fig. 1A), were usually AR-negative (Fig. 1B). In other follicles, in which only few cells exhibited apoptosis (Fig. 1C), the immunostaining for AR was very strong. (Fig. 1D). The serial sections of the investigated follicle collected on day 18 of pregnancy showed pyknotic cumulus cells forming a



Fig. 2. A fragment of the ovarian follicle from day 90 of pregnancy with positive TUNEL staining both in granulosa (arrowhead) and in theca cells (arrow). $\times 400$.

thin ring around the oocyte (Fig. 1A). Adjacent section of the same follicle clearly showed that almost all cells forming that follicle were negative for AR. Similar pattern was observed in atretic follicles isolated from ovaries collected on other studied days of pregnancy. In follicles showing advanced stages of atresia many apoptotic granulosa cells were detached and released into the follicular antrum (Fig. 2). Moreover, many apoptotic cells were scattered in the theca interna layer. On the other hand, in the ovary obtained on day 90 of pregnancy, many follicles looked normal by morphological criteria, and their cells were negative in TUNEL staining. These follicles expressed very high level of AR in granulosa cells and in some theca cells.

Discussion

In the present study we investigated the localization of androgen receptor in ovarian follicles which undergo atresia during pregnancy. The obtained results revealed that follicles with many apoptotic cells were negative for AR while nuclear immunostaining for AR was positive in follicles in which very few (or none) cells were apoptotic.

Androgens appear to be atretogenic in rodents [8] but may stimulate ovarian growth in primates [25]. AR gene expression was most abundant in the granulosa cells of small growing preantral and antral follicles where granulosa cells proliferated. The lack of AR expression in atretic follicles where granulosa cells apoptosis was observed, suggests that androgens can be involved in the stimulation of early primate follicle development [8].

We demonstrated cyclic changes in AR immunostaining in the ovary of the cycling pig [18]. However, there is little information concerning the localization of

AR in the atretic follicles. It has been shown in swine that atresia increases among small and medium-sized follicles during early luteal phase of the estrous cycle following ovulation [5, 26]. AR immunoreactivity was unchanged in nonatretic small follicles, which suggested that its expression was not regulated by FSH. The decline in AR expression that occurs with growth and increase in follicle size was described both in rats [19, 22] and pigs [18].

In all mammalian species, atresia is a prominent feature of ovarian follicular development [1]. Although follicle atresia has been found during the whole reproductive life, its hormonal mechanism is largely unknown.

In the rat, antral follicles which develop and undergo apoptosis during pregnancy, grow in the hyperprolactinemic microenvironment, and synthesize much lower than physiological amount of estradiol [21]. However, such estradiol level is sufficient to support normal but slower development of antral follicles. Atresia is characterized by apoptosis of the granulosa cells, especially cumulus oophorus complex (COC), and by the lack of hypertrophy of the theca layer. The degeneration of follicles is accompanied by loss of AR in the cumulus granulosa cells, while a strong positive AR immunoreactivity persists in the oocyte nucleoli [20].

A large number of atretic follicles is present in the ovary during pregnancy but little information on AR distribution during follicular degeneration is available. Weak or absent AR immunoreactivity in the granulosa cells of some atretic follicles was described in porcine ovaries during the estrous cycle [2, 5]. Species-specific differences in the process of apoptosis in granulosa and theca layers were described during follicular atresia in porcine and bovine ovaries [17]. The data indicate that in the ovaries of both species, theca interna but not theca externa is the site where apoptosis occurs. Our data is in accordance with such observations, since in the pregnant pig ovary apoptotic cells were localized in granulosa and theca interna layers of follicles. As reported by others [7, 9] granulosa cell proliferation and apoptosis may occur simultaneously in the same follicle.

Follicular atresia is primarily induced by granulosa cell apoptosis, but the description of the apoptotic pathway in granulosa cells has not yet been completed [13]. To date, at least five cell death ligand-receptor systems have been reported in granulosa cells of porcine ovary. Moreover, the porcine granulosa cell is a type II apoptotic cell, which has the mitochondrion-dependent apoptosis-signaling pathway [14]. Recently, two intracellular inhibitor proteins (cellular FLICE-like inhibitory protein short and long form: cFLIP_S and cFLIP_L) were found. They are strongly expressed in granulosa cells and may act as antiapoptotic/survival factors [6, 16]. Thus, porcine granulosa cells have some cell death ligand and receptor systems, and their actual role on the

regulation of follicle atresia have yet to be determined. The degeneration of ovarian follicles can be explained by apoptotic cell death of granulosa cells and endocrine cells of the theca interna layer [14, 15]. Many researchers proved hormonal control of follicular atresia through peptide hormones and cytokines as well as steroid hormones [1, 7, 9].

Apoptosis which occurs in granulosa cells is an initial symptom of follicular atresia in the ovaries and the apoptosis inducing/survival factors may be species-specific [17].

In conclusion, the obtained results showed changes in AR distribution during early follicular atresia and indicated that these changes did not depend on the day of pregnancy. AR can be one of the factors influencing follicular apoptosis. Reduced androgen receptor expression in atretic follicles suggests a decreased ability of these follicles to respond to androgens.

Acknowledgements: This study was supported by the State Committee for Scientific Research as a Solicited Project PBZ-KBN-084/PO6/2002/039.

References

- [1] Billig H, Furuta I, Hsueh AJW (1993) Estrogens inhibit and androgens enhance ovarian granulosa cell apoptosis. *Endocrinology* 133: 2204-2212
- [2] Cardenas H, Pope F (2002) Androgen receptor and follicle-stimulating hormone receptor in the pig ovary during the follicular phase of the estrous cycle. *Mol Reprod* 62: 92-98
- [3] Cheng Y, Inoue N, Matsuda-Minehata F, Goto Y, Maeda A, Manabe N (2005) Changes in expression and localization of connexin 43 mRNA and protein in porcine ovary granulosa cells during follicular atresia. *J Reprod* 51: 627-637
- [4] Duda M, Burek M, Galas J, Koziol K, Koziorowski M, Słomczynska M (2004) Immunohistochemical localization of androgen receptor and aromatase in the ovary of the pregnant pig. *Reprod Biol* 4: 289-298
- [5] Garret WM, Guthrie HD (1996) Expression of androgen receptors and steroidogenic enzymes in relation to follicular growth and atresia following ovulation in pigs. *Biol Reprod* 55: 949-955
- [6] Goto Y, Matsuda-Minehata F, Inoue N, Matsui T, Maeda A, Manabe N (2004) Porcine (*Sus scrofa*) cellular fllice-like inhibitory protein (cFLIP): molecular cloning and comparison with the human and murine cFLIP. *J Reprod* 50: 549-556
- [7] Guthrie HD, Cooper BS, Welch GR, Zakaria AD, Johnson LA (1995) Atresia in follicles grown after ovulation in the pig: measurement of increased apoptosis in granulosa cells and reduced follicular fluid estradiol-17 beta. *Biol Reprod* 52: 920-927
- [8] Hillier SG, Tetsuka M (1997) Role of androgens in follicle maturation and atresia. *Baillieres Clin Obstet Gynaecol* 11: 249-260
- [9] Hsueh AJW, Billig H, Tsafiriri A (1994) Ovarian follicle atresia: a hormonally controlled apoptotic pathway. *Endocr Rev* 15: 1-18
- [10] Hughes FM Jr, Gorospe WC (1991) Biochemical identification of apoptosis (programmed cell death) in granulosa cell: evidence for a potential mechanism underlying follicular atresia. *Endocrinology* 129: 2415-2422
- [11] Inoue N, Manabe N, Matsui T, Maeda A, Nakagawa S, Wada S, Miyamoto H (2003) Roles of tumor necrosis factor-related apoptosis-inducing ligand signaling pathway in granulosa cell apoptosis during atresia in pig ovaries. *J Reprod* 49: 313-321
- [12] Kaipia A, Hsueh AJW (1997) Regulation of ovarian follicle atresia. *Annu Rev Physiol* 59: 349-363
- [13] Manabe N, Kimura Y, Myoumoto A, Matsushita H, Tajima C, Sugimoto M, Miyamoto H (1998) Role of granulosa cell apoptosis in ovarian follicle atresia. In: *Apoptosis: Its Roles and Mechanism*. Yamada T, Hashimoto Y [Eds], Jpn Acad Soc Book Cent, Tokyo, pp 97-111
- [14] Manabe N, Inoue N, Miyano T, Sakamaki K, Sugimoto M, Myamoto H (2003) Ovarian follicle selection in mammalian ovaries: regulatory mechanism of granulosa cell apoptosis during follicular atresia. In: *The Ovary*. Leung PK, Adashi E [Eds], Academic Press/Elsevier Science Publishers, Amsterdam, pp 369-385
- [15] Manabe N, Goto Y, Matsuda-Minehata F, Inoue N, Maeda A, Sakamaki K, Miyano T (2004) Regulation mechanism of selective atresia in porcine follicles: regulation of granulosa cell apoptosis during atresia. *J Reprod* 50: 493-514
- [16] Matsuda-Minehata F, Goto Y, Inoue N, Manabe N (2005) Changes in expression of anti-apoptotic protein, cflip, in granulosa cells during follicular atresia in porcine ovaries. *Mol Reprod* 72: 145-151
- [17] Nakayama M, Manabe N, Nishihara S, Miyamoto H (2000) Species-specific differences in apoptotic cell localization in granulosa and theca interna cells during follicular atresia in porcine and bovine ovaries. *J Reprod* 46: 147-156
- [18] Słomczynska M, Tabarowski Z (2001) Localization of androgen receptor and cytochrome P450 aromatase in the follicle and corpus luteum of the porcine ovary. *Anim Reprod Sci* 65: 127-134
- [19] Szoltys M, Słomczynska M (2000) Changes in distribution of androgen receptor during maturation of rat ovarian follicle. *Exp Clin Endocrinol Diabetes* 108: 228-234
- [20] Szoltys M, Słomczynska M, Duda M, Sakiewicz A, Otak A (2005) Distribution of androgen receptor in rat ovarian follicles undergoing atresia at the beginning of pregnancy. *Acta histochem* 107: 357-364
- [21] Tabarowski Z, Szoltys M, Bik M, Słomczynska M (2005) Atresia of large ovarian follicles of the rat. *Folia Histochem Cytobiol* 43: 43-55
- [22] Tetsuka M, Whitelaw PF, Bremner WJ, Millar MR, Smyth CD, Hillier SG (1995) Developmental regulation of androgen receptor in rat ovary. *J Endocrinol* 145: 535-543
- [23] Tilly JL (1996) Apoptosis and ovarian function. *Rev Reprod* 1: 162-172
- [24] Utz PJ, Anderson P (2000) Life and death decisions: regulation of apoptosis by proteolysis of signaling molecules. *Cell Death Differ* 7: 589-602
- [25] Weil SJ, Vendola K, Zhou J, Adesanya OO, Wang J, Okafor J, Bondy CA (1998) Androgen receptor gene expression in the primate ovary: Cellular localization, regulation, and functional correlations. *J Clin Endocrinol Metab* 83: 2479-2485
- [26] Wesley M, Guthrie H.D (1996) Expression of androgen receptors and steroidogenic enzymes in relation to follicular growth and atresia following ovulation in pigs. *Biol Reprod* 55: 949-955

Received: December 16, 2005

Accepted after revision: February 2, 2006