

Rare genotype del2,3/2184insA in a cystic fibrosis patient

Alina Minarowska¹, Oksana Kowalczyk², Maciej Kaczmarek¹, Danuta Kowalczyk³
Łukasz Minarowski² and Lech Chyczewski²

¹3rd Department of Children's Diseases, ²Department of Clinical Molecular Biology,

³Department of Children's Radiology, Medical University of Białystok, Białystok, Poland

Abstract: In this paper we present an interesting case of cystic fibrosis patient with rare genotype del2,3/2184insA and atypical clinical image including: mild symptoms in an early phase of disease, quick progress of lung disease, complicated with pneumothorax after *Bordetella pertussis* infection and very good response to systemic and inhaled steroid therapy.

Key words: Cystic fibrosis - del2,3 - 2184insA - genotype

Introduction

The primary defect in cystic fibrosis (CF) is a mutation in *CFTR* gene found on the chromosome 7, on the long arm at position q31.2. The advances in CF therapy extended the mean length of life in these patients up to 36 years and improved their life quality. Early diagnosis is essential for proper therapy. Molecular examination in these patients does not necessarily confirm the clinical diagnosis. Standard molecular examination consists of maximum of 43 most frequent mutations of *CFTR* gene, whereas at present over 1400 mutations are known [7]. Due to large number of possible *CFTR* mutations and diverse genotype-phenotype correlation, it would be ideal to determine both mutations in every patient [5].

Case history

Clinical characteristics

22-year Caucasian male, birth mass 3490g, 9 pts. in Apgar score, frequent pneumonia and bronchitis noted from early infancy. CF was diagnosed at the age of 9 (1994) on the basis of clinical symptoms: chronic cough with expectoration of thick sputum, numerous alterations in auscultation, symptoms of chronic hypoxxygenation (clubbing) and positive sweat test.

Performed bronchography revealed numerous changes in the bronchi (left lower lobe and lingua). Unequal distribution of contrast medium and decreased number of bronchi branches was also described. In lung function testing mild ventilation disturbances were revealed. In sputum culture *Staphylococcus aureus* was observed. The patient was hospitalized twice due to severe exacerbation of lung disease. Since 1998, after *Bordetella parapertussis* infection, a significant deterioration of spirometric values was noted, respectively: FEV1 - 30% and FVC - 55% of predicted value with concomitant *Pseudomonas aeruginosa* colonization (Fig. 1). Number of severe exacerbations was systematically increasing with accompanying effort dyspnoea. In 2001 patient was hospitalized in Intensive Care Unit due to left-sided spontaneous pneumothorax. The FEV1 and FVC were lowered until systemic and inhaled steroids applied.

During follow-up, from December 2001 to May 2005, following radiographic changes were observed (according to Brasfield score):

- lung distension, visible as depressed diaphragmatic leafs - 2nd stage
- linear markings in both lung fields - 2nd stage
- bronchi cuffing - 3rd stage
- large lesions visible as fibrosis - 3rd stage

Although, patient was classified as 2nd/3rd stage, on the basis of general status and x-ray examination, the incident of pneumothorax fulfill criteria for 5th stage in Brasfield score.

Additional HRCT has revealed subpleural bullas, bronchiectases, nodular cystic lesions, emphysema,

Correspondence: A. Minarowska, 3rd Dept. of Children's Diseases, Medical University of Białystok, Waszyngtona 17, 15-274 Białystok, Poland; e-mail: minar@mp.pl

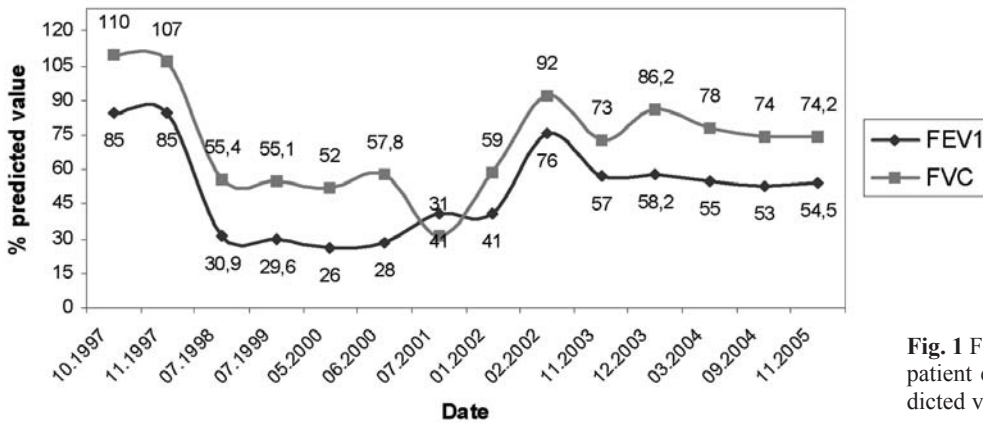


Fig. 1 FEV1 and FVC changes in presented patient expressed as percentage of on predicted values

adhesions limiting the pneumothorax and numerous, enlarged mediastinal lymph nodes. Advancement of x-ray changes was also evaluated using Bhalla score [2].

All performed imaging examinations correlated well with patients' severe clinical status, however the genotype was unknown.

At the age of seventeen, after incident of pneumothorax, severe lung disease was diagnosed: nutritional status indices were as follows Cole-Stanfield Index: 66%, Schwachman Score: 40 pts, blood oxygenation parameters O_2 66.4%, pO_2 34.9 mmHg, pCO_2 45.2 mmHg. Systemic steroid therapy, followed by inhaled steroids, brought significant amelioration of nutritional status - Cole-Stanfield Index: 83%, Schwachman Score 40 pts, and blood oxygenation parameters: O_2 95%, pO_2 34.9 mmHg, pCO_2 37.2 mmHg.

Molecular examination

Standard molecular examination revealed large deletion del2,3, the mutation in second allele remained unrecognized. Therefore whole gene sequencing was performed. Analysis was performed in 5 ml of whole blood. DNA was isolated from leukocytes using QIAGEN kit and 27 exons of *CFTR* gene were amplified in PCR using primers from VariantSEQR™ Resequencing Set (Applied Biosystems). Automatic sequencing was performed on AB-Prism 3700 (Applied Biosystems).

Results

In molecular testing a rare mutation, 2184insA (prevalence in Polish population <1% [8]), in exon 13 of *CFTR* gene has been found (Fig. 2). Furthermore two common sequence variants were found: 1540G/A and 4521G/A respectively in exons 10 and 24.

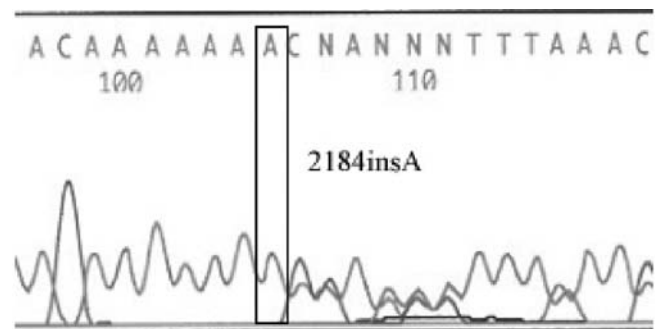


Fig. 2 2184insA mutation in presented patient

Discussion

From over 1400 known mutations of *CFTR* gene all types of nucleotides sequence changes are observed: non-sense mutations, frameshift, splicing, small and large deletions, insertions. Large deletions make around 3% of all mutations in *CFTR* gene. The prevalence of del2,3 in polish population is 2% [1]. This mutation belongs to severe class of *CFTR* mutation - the defect in which deletion of 21kb including exons 2 and 3 is related with severe CF course (high concentration of chloride ions in sweat, pancreatic insufficiency, early *Pseudomonas aeruginosa* colonization) [3].

2184insA mutations, which insertion of adenine in position 2184 causes frameshift, was described for the first time in two German patients [4]. Described clinical case correspond with severe CF course. Prevalence of this mutation is relatively high in Eastern Europe and in Russia (>7%) [6].

At this time there was no published case of del2,3/2184insA genotype. According to literature, presence of one of the mutations, del2,3 or 2184insA, is responsible for severe cystic fibrosis course (high concentration of chloride ions in sweat, pancreatic insufficiency, early *Pseudomonas aeruginosa* colo-

nization) from early age. Delayed age of diagnosis and mild clinical symptoms does not confirm these observations. At the moment, natural history of presented patient is typical for genotype-phenotype correlation for identified mutations, but proper and complex therapy decreased the progress of lung disease. Therefore early molecular diagnosis of mutations in *CFTR* gene would allow to apply intensive therapy, what should hold back the *Pseudomonas aeruginosa* chronic colonization in respiratory tract and severe complications of lung disease. Noteworthy is a fact of good response for applied systemic and inhaled steroid therapy.

References

- [1] Aznarez I, Bal, J, Casals T, Estivill X, Moral N, Sands D, Nunes V, Sobczyńska-Tomaszewska A, Tsui L-C, Zielenski J. Analysis of mutations in the *CFTR* gene in Polish cystic fibrosis patients. Identifications of rare mutations. *Med Wieku Rozw*, 2000; 4(2): 149-59
- [2] Bhalla M, Turcios N, Aponte V, Jenkins M, Leitman BS, McCauley DI, Naidich DP. *Radiology*, 1991; 179: 783-8
- [3] Dörk T, Macek Jr M, Mekus F. Characterization of a novel 21-kb deletion, *CFTR*dele2,3 (21 kb), in the *CFTR* gene: a cystic fibrosis of Slavic origin common in Central and East Europe. *Hum Genet*, 2000; 106: 259-68
- [4] Dörk T, Mekus F, Schmidt K, Bosshammer J, Fislage R, Heuer T, Dziadek V. Detection of more than 50 different *CFTR* mutations in large group of cystic fibrosis patients. *Hum Genet*, 1994; 94: 533-42
- [5] Koch C, Cuppens H, Rainisio M, Madessani U, Harms HK, Hodson ME, Mastella G, Navarro J, Strandvik B, McKenzie SG. European Epidemiologic Registry of Cystic Fibrosis (ERCF): comparison of major disease manifestations between patients with different classes of mutations. *Ped Pulm*, 2001; 31: 1-12
- [6] Petrova NV, Kapranov NI, Ginter EK. Detection of frequent mutations of the *CFTR* gene in cystic fibrosis patients from Central Russia. *Genetika*, 1997; Jan 33(1): 106-9
- [7] Rowntree RK, Harris A. The phenotypic consequences of *CFTR* mutations. *Ann Hum Genet*, 2003; Sep 67 (Pt 5): 471-85
- [8] Witt M, Pogorzelski A, Bal J, Rutkiewicz E, Majka L, Sobczyńska A. Frequency of mutations and genotypes of the *CFTR* gene in cystic fibrosis adults in Poland. *Pneum Alerg Pol*, 1999; 3-4: 137-41

Received: November 14, 2006

Accepted after revision: November 21, 2006