

Epstein-Barr virus (EBV) infection in B-cell non-Hodgkin's lymphomas in children: virus latency and its correlation with CD21 and CD23 molecules

Aldona Kasprzak¹, Rafał Spachacz¹, Jacek Wachowiak², Katarzyna Stefańska², Maciej Zabel^{1,3}

¹Department of Histology and Embryology, University of Medical Sciences, Poznań;

²Department of Haematology and Paediatric Oncology, University of Medical Sciences, Poznań;

³Department of Histology and Embryology, University of Medical Sciences, Wrocław, Poland

Abstract: Epstein Barr virus (EBV) infection of human B lymphocytes *in vitro* results in immortalisation of the cells and augmented membranous expression of numerous B-cell activation molecules, including CD23. Other studies demonstrated that only those B lymphocytes which carry the surface CD21 (EBV receptor) become transformation-competent. Inspired by the relatively unclear relations between expression of EBV and those of CD21 and CD23 *in vivo* conditions we have decided to define correlations between tissue markers of EBV and of CD21 and CD23 molecules in B-cell non-Hodgkin's lymphomas (NHLs) in children. The studies were performed on an archival tissue material originating from children with B-cell NHLs (n=26) using immunocytochemical techniques, *in situ* hybridisation, and PCR. Our studies confirmed the latent phase of EBV infection in all of the EBV-positive patients. Viral proteins as well as viral RNAs (EBERs) was found both in the cytoplasm, in cell nuclei and in cell membranes of mainly the transformed lymphocytes B. Expression of the latent proteins (EBNA2 and LMP1) and that of EBERs in B-cell NHLs was significantly higher as compared to children with non-neoplastic lesions. The studies demonstrated reciprocally positive correlations between expressions of CD21 and CD23 in our children, but no correlation could be demonstrated between expression of EBV tissue markers and that of CD21 and/or CD23. Positive correlation was confirmed between expression of EBNA2 and LMP1 as well as between expression of the two proteins and EBERs in B-cell NHLs. Our studies have shown mainly latency III pattern of EBV. We have also demonstrated a novel form of EBV latency with no EBERs expression. The high detectability of EBV-positive cases both in the group of B-cell NHLs (77%), and in the group with non-neoplastic lesions (64%) suggested that only more pronounced tissue expression of EBV markers in B-cell NHLs as compared to the non-neoplastic material may point to a potential role of EBV in pathogenesis of lymphoma in this group of population in our country.

Key words: B-cell non-Hodgkin's lymphoma - EBV tissue markers - CD21 and CD23 - Immunocytochemistry - Hybridization *in situ* - ImmunoMax technique - PCR

Introduction

The Epstein-Barr virus (EBV), a double-stranded DNA virus, a member of *Herpesviridae* family, subfamily of *Gammapherpesvirinae* [1], is associated with the development of both lymphoid and epithelial tumours. The principal target cells for EBV infection involve primary B lymphocytes but the virus can infect also T lymphocytes and epithelial cells [2-6]. The

infection of human B lymphocytes *in vitro* results in immortalisation of the cells and augmented membranous expression of numerous B-cell activation molecules, including CD23, CD30, CD39, CD40, CD44, and cellular adhesion molecules such as ICAM-1, LFA-1, and LFA-3 [7,8]. EBV infects B lymphocytes binding to the type 2 complement receptor (CR2, CD21), which is followed by internalisation of the virus [9]. The three-dimensional structure of CD21 fragment (CD21 SCR1-SCR2) has been recognised, which most probably is responsible for binding of EBV [10]. In cellular penetration of EBV surface HLA class II molecules also take part [11]. Following viral internalisation, DNA of the virus forms an epi-

Correspondence: A. Kasprzak, Dept. Histology and Embryology, University of Medical Sciences, Święcickiego 6, 60-781 Poznań, Poland; tel.: (+4861) 8546441, fax.: (+4861) 8545440, e-mail: akasprza@amp.edu.pl

somal form in cell nuclei of the host and the latent form of the infection becomes stabilised [7]. At present, four patterns of EBV latency are recognised [12,13]. In the strict type I latency, represented mainly by Burkitt lymphoma (BL) cells, viral gene expression is restricted to the two EBER genes, the BART gene, and the EBNA1 (EBV nuclear antigen 1) gene [13]. In latency II additional expression of three latent-membrane proteins, LMP-1, LMP-2A and LMP-2B is observed. It is encountered most frequently in Hodgkin's lymphoma. Latency III is seen in lymphoproliferative diseases arising in immunocompromised individuals and EBV-transformed lymphoblastoid cell lines. In this group all six EBNA, all three LMPs and the two EBERs are expressed [12,13]. Type IV latency is less strictly defined and pertains infectious mononucleosis patients and patients with a post-transplant lymphoproliferative disease [13]. Some patients distinguish also the so called putative latency program (latency 0), in which no latent gene undergoes expression [12].

Principal mediators of EBV-induced growth and cellular transformation of B lymphocytes *in vitro* include EBNA2 and LMP1 proteins [7]. EBNA2 is indispensable for transformation of primary B lymphocytes, leading to transactivation of other cellular and viral genes [2,14]. The protein augments expression of genes coding CD21, CD23, LMP1 and LMP2 proteins in B lymphocytes [2,7,8]. In the mouse model LMP1 was found to be critical but not mandatory for the generation of proliferating B cells *in vitro* [15]. BZLF1 (ZEBRA) is a DNA-binding protein, which expression precedes the switch from latent to lytic infection [2]. BZLF1 is a viral transactivator protein triggering expression of lytic genes and downregulation of latent genes, culminating in cell death and release of infectious virions. This protein also up-regulates expression of other immediate early genes as well as expression of ZEBRA itself. These genes, in turn, up-regulate the expression of early gene products (viral DNA polymerase and thymidine kinase) [2,16]. Two small RNAs (EBER-1 and EBER-2) represent the most vast types of EBV RNA in the latent infection and undergo continuous expression in EBV-positive tumours, independently of their pattern of latency [2,7,12].

Studies performed *in vitro* demonstrated that CD21 plays role of an EBV receptor and only those B lymphocytes which carry the surface CD21 become transformation-competent [2,9,17]. A more pronounced expression has been noted in more differentiated cell lines originating from B lymphocytes [18]. Lower amounts of CD21 were detected on cells of naso-pharyngeal epithelium, immature T lymphocytes and cultures of the cells [3,19-21].

In order to clarify role of Epstein-Barr virus (EBV) in oncogenesis of B-cell non-Hodgkin's lymphomas in

children a comparative analysis was performed involving expression of three viral proteins, EBV RNA (EBER), EBV DNA as well as their correlations with CD21 and CD23 expression in lymphoid organs. Due to the potential role of EBV in development of B-cell NHLs, also in nonendemic areas, we have decided to characterise the patterns of EBV latency in children in our country.

Material and methods

Tissue material. Archival paraffin blocks with surgical material (lymph nodes and extra-nodular neoplastic lesions) originated from 26 children with B-cell non-Hodgkin's lymphomas of 1 to 16 years of age (mean age: 8±4 years), including 25 boys and one girl, diagnosed in 1999-2003 in the Department of Haematology and Paediatric Oncology, University of Medical Sciences in Poznań. The studied material was sampled before start of any therapy. In 12/22 examined sera of B-cell NHLs, IgG anti-EBV capsid antigen (VCA) were positive; in one child both IgM and IgG anti-VCA were positive. The histopathological diagnosis and selected clinical data are presented in Table 1. The comparison group (non-neoplastic changes) included lymphoid organs (palatine tonsils, lymph nodes, appendices) sampled from 8 boys and 3 girls (n=11; mean age: 12±4 years) with no detectable signs/symptoms of EBV-related diseases, in whom complete diagnostic efforts excluded neoplastic type of the lesions. Positive control included selected organs (lymph nodes, liver, spleen, lungs, kidneys) sampled upon autopsy of a 3-year-old child deceased due to acute diffuse primary EBV infection (infectious mononucleosis syndrome). The studies were conducted on serial, 5 µm paraffin sections, placed on the SuperFrost/Plus microscopical slides. The archival material was fixed in a buffered 10% formalin and embedded in paraffin using the routine procedure.

Immunocytochemical studies. Mouse anti-human monoclonal antibodies were employed, directed against EBNA2 (1:50), LMP1 (1:50), BZLF1 (ZEBRA) (1:20), CD20 (1:20), CD45RO (1:2), CD57 (1:100), CD68 and anti-human Von Willebrand Factor (both ready for use dilutions) (all MAbs from DAKO, Glostrup, Denmark), CD3 (1:50), CD21 (1:100) and CD23 (ready to use) (NOVOCASTRA Labs, Newcastle upon Tyne, UK). Then, the sections were treated with primary MAb at night at 4°C, then secondary biotinylated link anti-mouse and anti-rabbit IgG (DAKO) and with the streptavidin-biotin-peroxidase complex (ABC) (DAKO). The studies followed the classical ABC technique [22], associated with the ImmunoMax technique [23] (for detecting CD21, CD23 and ZEBRA). In both techniques microwave-oven pretreatment for antigen retrieval was used. In the ImmunoMax technique, the key reaction involved 8 min incubation with biotinylated tyramine (PerkinElmer life Sciences, Inc.) in dilution 1:50 at RT. This was followed by another application of streptavidin complex. The colour reaction was evoked with the HRP substrate, 0.05% 3,3'-diaminobenzidine tetrahydrochloride (DAB; DAKO) in 0.05 M Tris-HCl buffer, pH=7.6, supplemented with 0.001% H₂O₂. In tissue sections, endogenous peroxidase was blocked with 1% H₂O₂. Control reactions employed control sera of the respective species in 0.05 M Tris-HCl, pH=7.6, supplemented with 0.1% BSA and 15 mM sodium azide (negative control) (DAKO).

Most of the histological preparations were subjected to double immunocytochemical reactions, including lymphocyte B (CD20+), T (CD3+, CD45RO+), NK-like cells (CD57+), macrophage marker (CD68+) or marker of endothelial cells (Von Willebrand Factor) and one of the EBV proteins. The terminal reaction product was visualised using DAB (brownish-black signal) or Vector VIP sub-

Table 1. Selected clinical data on children with B-cell non-Hodgkin's lymphomas.

Patient	Sex/age (years)	Type of NHL-B	Tumor localisation	Anti-VCA	
				IgG	IgM
1.	M/4	LL type B	mandibular and cervical lymph nodes	neg.	neg.
2.	M/7	BL	ileo-caecal region	neg.	neg.
3.	M/12	BL	tonsil	not tested	
4.	M/8	BL	ileo-caecal region	pos.	neg.
5.	M/7	LL type B	abdominal cavity	neg.	neg.
6.	M/5	BL	axillar lymph node	neg.	neg.
7.	M/2	LL type B	head, orbit	neg.	neg.
8.	M/4	LL type B	axillar, inguinal lymph nodes	pos.	neg.
9.	M/3	BLL	maxilla	neg.	neg.
10.	M/6	DLL B-cell	appendix	neg.	neg.
11.	M/4	BLL	tonsil, cervical lymph nodes	pos.	neg.
12.	M/1	LL type B	occiput	neg.	neg.
13.	M/10	BL	mesentery, ileum	pos.	neg.
14.	M/16	BL	tonsil	pos.	pos.
15.	M/3	BLL	mediastinum	not tested	
16.	M/9	LL type B	caecum	pos.	neg.
17.	M/7	LL type B	occiput	pos.	neg.
18.	M/2	LL type B	abdominal cavity	neg.	neg.
19.	M/6	BL	tonsil	pos.	neg.
20.	M/14	DLL B-cell	mediastinum	pos.	neg.
21.	F/16	BL	appendix	pos.	neg.
22.	M/8	LL type B	caecum	not tested	
23.	M/10	BL	caecum	pos.	neg.
24.	M/15	BL	mesentery, omentum	neg.	neg.
25.	M/10	BLL	appendix	pos.	neg.
26.	M/11	LL type B	mandible, maxillary sinus	not tested	

Designations: BL - Burkitt's lymphoma; BLL- Burkitt's like lymphoma; DLL - diffuse large lymphoma; LL - lymphoblastic lymphoma; pos. - positive; neg. -negative; VCA - EBV capsid antigen.

strate kit for peroxidase (Vector Labs, Burlingame, CA, USA) (purple reaction product). Some preparations were counterstained with hematoxylin and mounted, using a glycerol-based mounting medium. Control reactions were based on substituting specific antibodies with normal sera of the respective species in 0.05 M Tris-HCl, pH=7.6, supplemented with 0.1% BSA and 15 mM sodium azide (negative control).

In situ hybridization. For this purpose the fluorescein-conjugated Epstein-Barr Virus Probe ISH Kit was used (NOVOCASTRA) for demonstrating EBV-encoded small nuclear non-polyadenylated RNAs (EBER1 and 2). The protocol of ISH reaction suggested by NOVOCASTRA was used, with the earlier described modifications of our own [23]. The preliminary stages of the ISH protocol were followed by incubation of paraffin sections with the probe for

2 h at the temperature of 37°C, then washed 3x3 min in TBS, containing 0.1% Triton X-100. This was followed by 30 min incubation with blocking solution (normal rabbit serum diluted 1:5 with TBS, containing 3% bovine albumin and 0.1% Triton X-100) at RT and 30 min incubation with rabbit anti-FITC/AP diluted 1:100 with TBS, 3% v/v BSA, 0.1% v/v Triton X-100. Subsequently, the sections were washed in TBS and in alkaline phosphatase substrate buffer, pH=9.0, for 5 min. The next stage involved 14 to 16 h incubation in the solution containing 5-bromo-4-chloro-3-indolylphosphate (BCIP) and nitro blue tetrazolium (NBT) in dimethylformamide solution, dissolved at the ratio of 1:50 in a buffer (100 mM Tris/HCl, 100 mM NaCl, 50 mM MgCl₂). One µl levamisole hydrochloride was added per each ml of the diluted enzyme substrate. Terminal stage involved washing of the preparations in distilled water (2x5min) and mounting them in an aqueous balsam

Table 2. Evaluation of EBNA1, LMP1, CD21, CD23 and EBERs expression in studied preparation [according 24]. The final score represents a product of the positive cells score (A) and the score reflecting intensity of the colour reaction (B).

A	B
0: no cells with positive reaction	0: no colour reaction
1: to 10% cells with positive reaction	1: low intensity of colour reaction
2: 11 to 50% cells with positive reaction	2: average intensity of colour reaction
3: 51 to 80% cells with positive reaction	3: intense colour reaction
4: >80% cells with positive reaction	

No reaction: score 0 points. Weak reaction: score 1 to 2 points. Average intensity of the reaction: score 3 to 4 points. Intense reaction: score 6 to 12 points

(DAKO). Positive control for the hybridocytochemical reaction involved paraffin preparations of EBV infected organs from autopsy material and EBV-positive paraffin slides supplied by the producer of the kit (NOVOCASTRA).

Isolation of DNA from paraffin sections and PCR technique.

Tissue fragments were extracted twice with xylene and were washed twice in ethanol. After drying them, DNA was isolated from the samples. For this purpose, DNA isolation buffer was prepared, devoted to isolation of the acids from paraffin embedded tissues. The buffer contained 50 mM Tris, pH 8.5; 1 mM EDTA; 0.5% Tween 20 and 200 µg/ml proteinase K. 200 µl of the buffer was added to each sample. After 18 h incubation at 37°C the tubes were centrifuged for 30 s, placed in 95°C for 8-10 min and centrifuged again for 30 s. The tubes were stored at -20°C. PCR reaction was performed using the following primers for the EBNA1 EBV gene fragment (Institute of Biochemistry and Biophysics (IBB) PAN, Warszawa, Poland):

EB1: 5'-TGC GAG TAA TTG GTG ATG AG-3' (upstream)

EB2: 5'-TCG TCA GAC ATG ATT CAC AC-3' (downstream)

PCR reaction was performed in Eppendorf-type tubes, charged consecutively with: 2.5 µl 10× amplification buffer [Tris-HCl, KCl, (NH₄)₂SO₄, 15 mM MgCl₂ (Qiagen), pH=8.7; 0.5 l dNTP (10 mM; Qiagen)], 1 µl of each primer (0.5 µM; IBB), 5 µl DNA template, 0.2 µl Taq DNA polymerase (2.5 U; Qiagen) and distilled water to the final volume of 25 µl. In order to increase effectiveness of amplification of the DNA isolated from paraffin embedded tissues, the thermic profile of PCR reaction was modified and the number of reaction cycles was increased. Tubes with the prepared reaction mixture were placed in a thermocycler (DNA-Engine, PTC-200, Peltier Thermal Cycler). After preliminary denaturation at 94°C (3 min), 35 cycles were executed, each involving denaturation at 94°C (30 s), annealing of primers at 56°C (30 s) and elongation at 72°C (1 min). The second PCR was conducted in the same conditions but 2 µl of the reactive mix following the first PCR reaction was used as a template. Every time a negative control reaction was run, employing all the components required for PCR reaction and water in place of DNA. The reaction product was analysed immediately or after some time, storing it at the temperature of -20°C. In order to evaluate PCR, its products were subjected to electrophoresis in 2% agarose gel in 1×TBE buffer (5×TBE: Tris 54g, boric acid 27.5g, EDTA 0.5mM pH=8.0, water up to 1000 ml), with ethidium bromide supplementation (0.25 µg/ml), at 100-120V. Every lane was charged with 15 µl sample plus 5 µl stain

Table 3. Semi-quantitative evaluation of selected markers of EBV infection and of CD21/CD23 molecules in children with B-cell non-Hodgkin's lymphomas using IRS scale [24].

No of patient	ZEBRA	EBNA2	LMP1	EBERs	EBV DNA	CD21	CD23
1.	0	0	0	0	negative	2	6
2.	0	0	4	6	positive	3	6
3.	0	0	0	0	negative	3	2
4.	0	2	6	3	positive	0	0
5.	0	3	3	0	negative	2	1
6.	0	12	6	6	negative	0	0
7.	0	0	3	6	negative	0	0
8.	0	0	6	9	positive	3	3
9.	0	0	0	0	negative	0	0
10.	0	0	0	0	negative	3	6
11.	0	0	0	0	negative	6	0
12.	0	0	0	0	negative	0	0
13.	0	0	2	3	positive	0	0
14.	0	0	3	0	positive	0	3
15.	0	4	8	nt	negative	0	0
16.	0	3	6	8	positive	nt	nt
17.	0	3	4	3	positive	3	3
18.	0	6	8	10	positive	0	6
19.	0	10	8	8	positive	1	2
20.	0	2	8	0	negative	3	6
21.	0	8	10	3	positive	0	0
22.	0	3	4	0	negative	0	0
23.	0	3	4	6	negative	0	4
24.	0	0	6	0	positive	0	0
25.	0	0	0	0	positive	0	3
26.	0	0	10	0	negative	3	3

Designation: nt - not tested

(orange G). pUC19/Msp I (MBI Fermentas) was used as a sizing marker of DNA fragments. Gels were viewed and photographed under UV lamp. The amplified fragment originated from the region of the EBNA1, it was 480 bp in length.

Semiquantitative evaluation of the results and statistics. The contents of EBV antigenic proteins, EBERs as well as of CD21 and CD23 were calculated in B-cell NHLs and in non-neoplastic lesions by two pathologist employing the semiquantitative IRS scale, according to Remmele and Stegner [24] (Table 2), taking into account intensity of the colour reaction and the number of positive cells. The final score represented a product of scores representing the two variables and ranged from 0 to 12 points. In every preparation 10 visual fields were appraised at the magnification of 400× and mean scores were calculated. The means were compared compared using the Mann-Whitney U test for non-parametric independent data and the Wilcoxon test for non-parametric dependent data. The exact Fisher's test was applied to compare manifestation of DNA EBV in individual groups. Correlations between data rows were determined employing Spearman's rank correlation index.

Table 4. Semi-quantitative evaluation of selected markers of EBV infection and of CD21/CD23 molecules in children with non-neoplastic lesions using IRS scale [24].

No of patient	Sex/age	ZEBRA	EBNA2	LMP1	EBERs	EBV DNA	CD21	CD23
1.	F/9	0	0	3	0	positive	0	3
2.	M/15	0	0	0	0	negative	3	6
3.	F/15	0	0	0	0	negative	2	2
4.	M/12	0	0	8	3	positive	0	0
5.	M/12	0	0	4	3	positive	0	4
6.	M/7	0	0	0	0	negative	3	9
7.	F/17	0	0	2	2	positive	0	3
8.	M/6	0	0	0	0	positive	3	4
9.	M/5	0	0	0	0	negative	6	6
10.	M/13	0	0	3	3	positive	3	4
11.	M/17	0	0	2	2	positive	0	3

Results

Immunocytochemistry

EBNA2 and LMP1 proteins. Expression of EBNA2 protein was demonstrated in 12/26 examined patients with B-cell NHLs (46%). Nuclear localisation of the protein prevailed in individual, scattered neoplastic cells (Fig. 1A). The cells involved mainly lymphocytes of CD20+ phenotype. LMP1 protein was demonstrated in 19/26 studied B-cell NHLs (73%), in individual, scattered cells or in their groups. Both cytoplasmic and membranous localisation of the protein was observed (Fig. 1B). The reaction was most frequent in cells of the CD20+ phenotype (Fig. 1C). Co-localisation of CD3 or CD45RO and LMP1 protein was observed in individual cases. Presence of the two viral proteins in the same tumour occurred in 12/26 cases (Table 3). In the group of patients more LMP1 could be demonstrated as compared to EBNA2 and ZEBRA ($p=0.01$ and $p=0.0001$ respectively). The total frequency of EBV-positive children amounted to 77% when presence of at least one tissue marker of EBV was taken as indicating EBV positivity. In the non-neoplastic material, expression of EBNA2 could not be demonstrated in any of the patients while expression of LMP1 was documented in 6/11 (54%) cases (Table 4). Expression of LMP1 was significantly lower as compared to B-cell NHLs ($p=0.007$) (Table 5). Co-expression of LMP1 and CD20+ developed mainly in lymphocytes in the enlarged lymphoid follicles of studied organs. Among the children, 64% presented expression of at least one EBV tissue marker. In the autopsy material of the child deceased due to infectious mononucleosis (positive control) markedly augmented expression of the two latent proteins was noted in every of the studied organs (the data were not subjected to statistical analysis). The proteins were detected in B lympho-

Table 5. Comparative immunocytochemical and hybridocytochemical scoring of EBV proteins, EBERs, CD21 and CD23 in B-cell NHLs vs non-neoplastic lesions in children.

	NHLs-B cell	Non-neoplastic lesions
ZEBRA	0.00±0.00***	0.00±0.00***
	NS	
EBNA2	2.27±0.66	0.00±0.00
	p=0.005	
LMP1	4.19±0.65*	2.00±0.49**
	p=0.007	
EBERs	2.84±0.68	1.18±0.27
	NS	
CD21	1.28±0.33	1.82±0.39
	NS	
CD23	2.16±0.46 ¹	4.00±0.46 ²
	p=0.05	

The Table lists mean values ± SEM

Designations: NS - not significant; p - level of significance, *- $p=0.01$; ** - $p=0.03$ between EBNA2 i LMP1; *** - $p=0.0001$; $p=0.03$ between LMP1 and ZEBRA, respectively; ¹ $p=0.06$ and ² $p=0.01$ between CD21 and CD23.

cytes (CD20+), cells of CD21+ phenotype (B lymphocytes, follicular dendritic cells) and individual T lymphocytes (CD3+ or CD45RO+), macrophages (CD68+) and cells of CD57+ phenotype (Fig. 2A and B). Numerous enlarged cells of CD20+ and CD68+ phenotype were noted, which manifested expression of EBV proteins.

BZLF1 (ZEBRA) protein. Cells immunopositive for the protein were demonstrated in every organ of the child with the diffuse form of EBV infectious mononu-

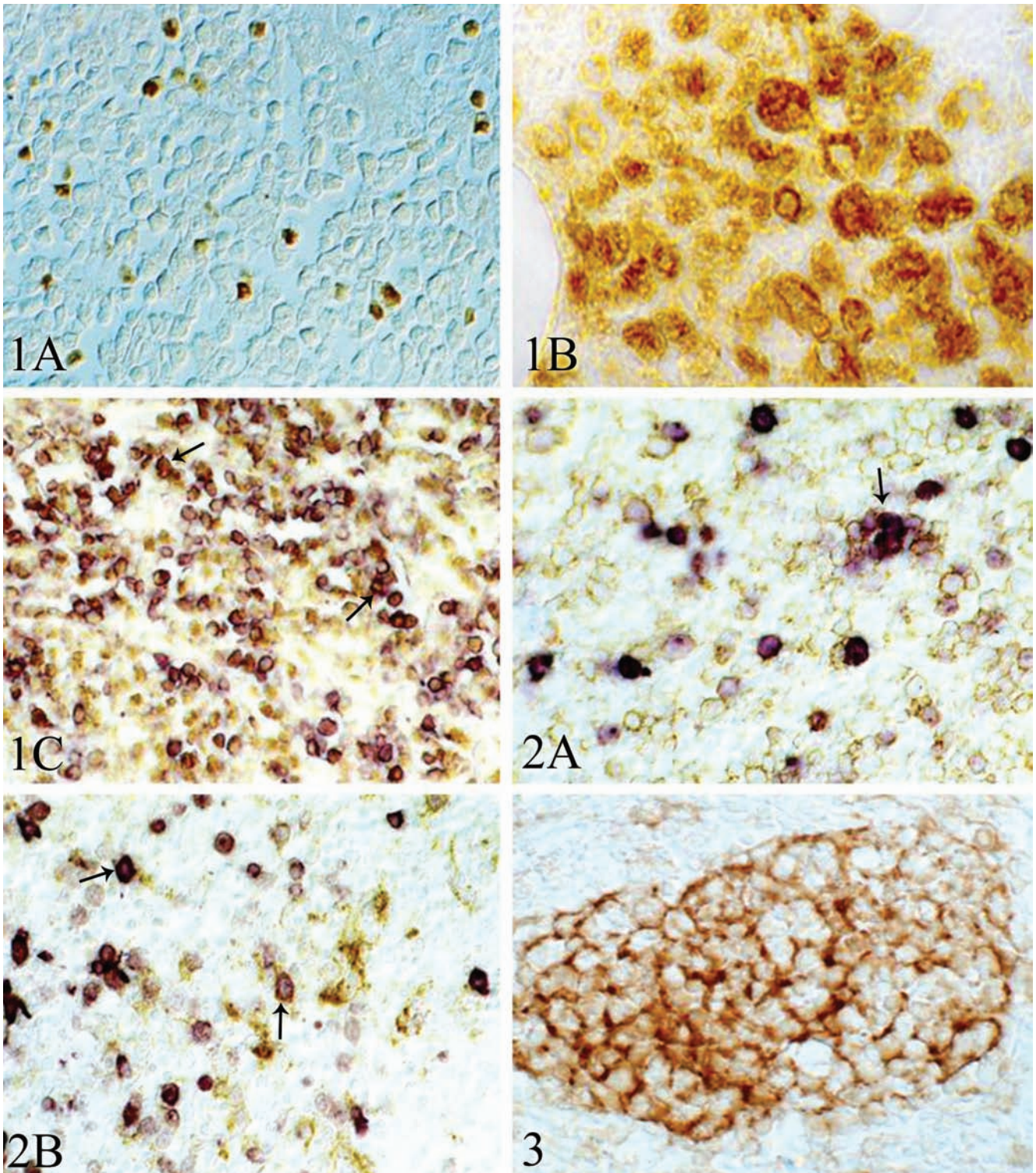


Fig. 1. Expression of EBV latent proteins in B-cell non-Hodgkin's lymphoma. **A.** Nuclear localisation of the EBNA2 in scattered cells. **B.** Membranous and cytoplasmic localisation of LMP1 in a group of cells. **C.** Double-labelling immunocytochemistry reveals co-localisation of LMP1 (brown staining) and CD20+ (purple staining) in individual tumour cells (arrow). ABC method. Nomarski optics (magnification $\times 400$ (A, C), $\times 550$ (B)). **Fig. 2.** Expression of EBV latent proteins in infectious mononucleosis (positive control). **A.** Double-labelling immunocytochemistry reveals co-expression of LMP1 (purple staining) and CD20+ (brown staining) in a few cells (arrow), while others express either LMP1 or CD20+. **B.** Double labelling immunohistochemistry for co-localisation of LMP1 (purple staining) and CD21+ (brown staining) cells (arrow). ABC-double staining (magnification $\times 400$). **Fig. 3.** Immunocytochemical localisation of CD21 in lymph nodule of a child with non-neoplastic lesions. ABC-Immunomax technique (magnification $\times 400$).

cleosis and they were most numerous in the lungs and lymph nodes. Cellular localisation of the protein resembled that of latent proteins even if less immunopositive cells were detected. In none of the B-cell NHLs cases nor in the material with non-neoplastic lesions could expression of BZLF1 protein be disclosed.

CD21 and CD23 molecules. Expression of CD21 was demonstrated in 11/25 (44%), and that of CD23 in 14/25 patients with B-cell NHLs (56%). CD23+ cells were slightly more numerous as compared to CD21+ cells ($p=0.06$, borderline significance). In the material with non-neoplastic lesions, CD21 was detected in 6/11 patients (54%), and CD23 in 10/11 patients (91%) and in these cases CD23+ cells were significantly more numerous than CD21+ cells ($p=0.01$). CD23+ cells were also significantly more numerous in the group than in B-cell NHLs ($p=0.05$) (Table 5). Expression of both molecules in all studied tissues (lymphomas, non-neoplastic lesions and infectious mononucleosis) manifested a membranous pattern and involved mainly lymphocytes within lymphoid follicles (B lymphocytes, follicular dendritic cells) (Fig. 3).

In situ hybridization

Expression of Epstein-Barr virus small RNAs (EBERs) was demonstrated in 12/25 patients with B-cell NHLs (48%). Product of the hybridocytochemical reaction was noted in individual, scattered cells or cells in small groups (Fig. 4A). In the material with non-neoplastic lesions, expression of EBERs was observed in 5/11 examined children (45%) in individual cells. No significant quantitative differences were disclosed between expression of EBER in B-cell NHLs and that in non-neoplastic cells. In the autopsy material of the child with EBV infectious mononucleosis expression of EBERs was evident. It was most intensely in lymph nodes and spleen (Fig. 4B). In positive control tissue material from the producer of the kit (NOVOCASTRA), expression of EBERs was also evident and was noted at the nuclei of EBV-infected cells (Fig. 4C).

Polymerase chain reaction

A fragment of EBV genome (EBNA1) of 480 bp was detected in 12/26 examined children with B-cell NHLs (46%) (Table 3). Except of one case, the DNA was detected in all the patients together with at least one EBV protein and/or EBERs. Parallel expression of EBERs, the two proteins and EBV DNA was documented in 6 cases of children with B-cell NHLs, who, in parallel proved to be seropositive in five cases (Table 2 and 3). In one child (case no 18) tissue detec-

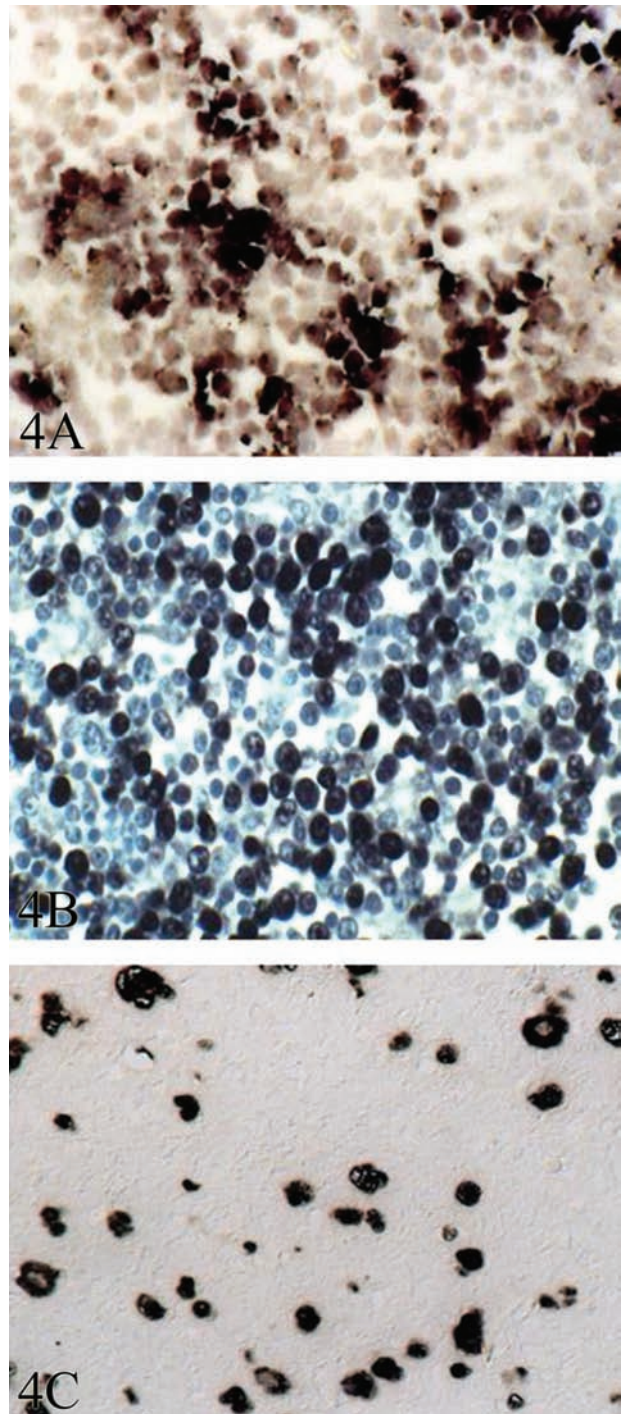


Fig. 4. A. Hybridocytochemical reaction for EBV-RNAs (EBERs) in a small group of B-cell NHLs. B. Intense hybridocytochemical reaction for EBERs in EBV-positive lymph node of infectious mononucleosis (positive control). C. Many EBERs-positive cells of control material from the producer of the kit (magnification $\times 400$). Hematoxylin counterstained (B).

tion of EBV infection was more sensitive than using serological method. In the material of 8 patients (31%) no DNA was detected even if expression of at least one EBV protein and/or EBERs was detected. In the non-neoplastic material EBV DNA was detected in 7/11

Table 6. Suggested latency patterns in EBV-positive cases of B-cell NHLs and non-neoplastic material (control).

EBV proteins expressed	EBERs positive cases		EBERs negative cases		Latency patterns*
	B-cell NHLs	control	B-cell NHLs	control	
EBNA2-LMP1-	0	0	0	0	0 or I
EBNA2-LMP1+	4 (16%)	5 (45%)	3 (12%)	1 (9%)	II
EBNA2+LMP1+	8 (32%)	0	3 (12%)	0	III
EBNA2+LMP1-	0	0	0	0	IV

Designations: *- according Kuppers [13]. Numbers in brackets indicate percentage of patients with a given type of EBV latency per the total number of patients in the studied group (e.g. B-cell NHLs n=25; non-neoplastic children n=11)

studied patients (64%). In 6 of them LMP1 and/or EBER were also detected by immunocytochemistry. No significant differences in frequency of DNA EBV detection were present between the group of children with B-cell NHLs and the group with non-neoplastic lesions (exact Fisher's test). PCR-amplified fragment of 480 bp length (fragment of EBNA1 gene) from the B-NHLs and controls is demonstrated on Fig. 5.

Correlations between cellular markers of EBV and CD21/CD23 molecules

In children with B-cell NHLs, positive correlation was demonstrated between expression of EBNA2 and LMP1, EBNA2 and EBER as well as between LMP1 and EBER (Spearman correlation coefficient of 0.629; 0.489; 0.512, respectively, $p < 0.05$). No correlation could be disclosed between expression of cellular EBV markers on one hand and those of CD21 and CD23 on the other. Positive correlation was demonstrated between expression of CD21 and CD23 (Spearman correlation coefficient of 0.485, $p < 0.01$) in the group of patients. In the material of non-neoplastic lesions expression of LMP1 was positively correlated with that of EBERs (Spearman correlation coefficient of 0.834, $p < 0.05$). Positive correlation was disclosed between expression of CD21 and that of CD23 (Spearman correlation coefficient of 0.737, $p < 0.05$). Also in this group of patients no correlation could be disclosed between expression of cellular EBV markers on one hand and those of CD21 and CD23 on the other.

Latency pattern of EBV

Taking into account expression of the two latent phase proteins (EBNA2 and LMP1) as well as expression of EBERs, potential latency patterns were examined in the studied children. The suggested latency patterns in EBV positive patients are shown in Table 6. The evaluation did not include one child with B-cell NHLs, in whom EBERs were not examined in tissue. The new element involved demonstration of a novel latency type, with negative EBERs, in 6/25 (24%) of the stud-

ied children with B-cell NHLs. Independently of EBERs expression, in children with B-cell NHLs type III of latency prevailed (11 patients).

Correlations between cellular markers of EBV and patient's age or histological diagnosis

Neither in the group of children with B-cell NHLs nor in the group with non-neoplastic lesions could correlation be observed between patient's age and examined cellular markers of EBV. No significant relationships could also be noted between specific histological diagnoses and expression of EBV markers.

Discussion

Several data point to involvement of EBV as a co-factor in development of lymphoid and epithelial malignancies, but the mechanisms involved remain unclear [3,4,25,26]. In nonendemic regions of the world the association of lymphoma with EBV is less stable and can be noted in 20-80% cases [26].

EBNA1 and EBERs are the only EBV genes consistently expressed in EBV positive Burkitt's lymphoma tumours [26,27], although some reports have documented the expression of LMP1 and EBNA2 in few tumour cells of some cases of endemic Burkitt's lymphoma [28], and LMP1 in several cases of sporadic Burkitt's lymphoma [29]. Cellular localisation of EBV proteins and/or EBV RNA (EBER) was described mainly in lymphocytes B and plasma cells, lymphocytes T, oral cavity and pharyngeal epithelium as well as in tumours derived from the cell populations [2,13,30].

Our present results have confirmed the expression of EBNA2 and LMP1 in B-cell NHLs, mainly in cells of the CD20+ phenotype (B lymphocytes) but also in cells of CD21+ phenotype (B lymphocytes, follicular dendritic cells) in individual cases. In the EBV infectious mononucleosis patient expression of EBV proteins involved an additional cell population (CD45RO+, CD57+, CD68+). Expression of the protein of the lytic infection stage (ZEBRA) has been

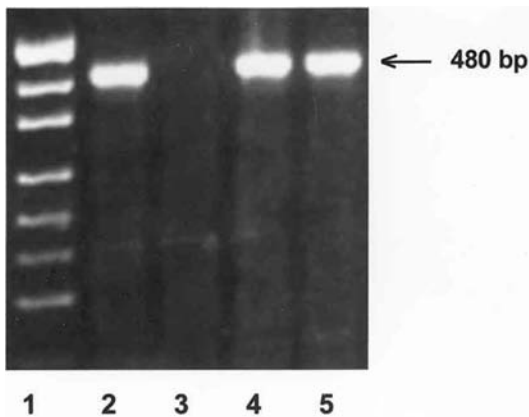


Fig. 5. Electrophoresis in 2% agarose of PCR-amplified EBV-DNA fragment of 480 bp length (EBNA1) from the tumour of B-cell NHL and controls. Legend: 1 - pUC 19 DNA/Msp I (*Hpa II*) size marker; 2 - PCR-amplified product of EBV-DNA (EBNA1) (480 bp) using oligonucleotide primers EB1 and EB2 in positive control material; 3 - EBV- negative lymphoma; no product in PCR reaction; 4 - PCR-amplified product of EBV-DNA (EBNA1) (480 bp) in B-cell NHL (sample no 26749-5); 5 - PCR-amplified product of EBV-DNA (EBNA1) (480 bp) in EBV positive appendix (sample no 28907).

observed exclusively in the child with disseminated form of infectious mononucleosis. Niedobitek *et al.* showed ZEBRA (BZLF1) trans-activator protein expression both in tissues of patients with infectious mononucleosis and in a few tumor cells in 6 cases of endemic Burkitt's lymphoma [28,30].

In our children with non-neoplastic lesions a significantly lower expression of EBV proteins was noted, as compared to children with B-cell NHLs and in no other case expression of EBNA2 could be demonstrated. Results of present study on expression of all EBV markers in non-neoplastic lesions cannot be related to literature data. Studies employing PCR techniques and a newly developed genotyping technique applied to saliva and peripheral blood are available, which demonstrated both presence of EBV genome and of specific sequences of *LMP1* gene in 15-22% healthy, immunocompetent individuals [31,32]. In a variable proportion of cases (10 to over 80%) EBV DNA has also been demonstrated in organs obtained upon autopsy from patients with without apparent EBV-related diseases. More numerous EBV-positive cases have been detected in lymphoid organs [33], which has been confirmed in present studies on detection of DNA in children with non-neoplastic lesions (64%, lymphoid organs).

In our study, differences have been noted in distribution of the immunopositive cells in the patients. In children with B-cell NHLs the cells with the protein expression have tended to be scattered throughout the tumour. In the non-neoplastic material, focal expression of LMP1 and EBER has been documented in nor-

mal or enlarged lymphoid follicles. No correlation could have been disclosed between expression of EBV tissue markers and a specific histological diagnosis.

In order to define latency patterns in the studied archival material, expression of the two latent proteins (EBNA2, LMP1) and EBERs in tissue has been taken into account. The obtained data have shown that EBERs cannot be demonstrated in all cases with expression of the latent proteins. The till now defined EBV latency forms should include expression of EBERs [13,34]. Six of our EBV positive children with NHLs have manifested no expression of EBERs despite the presence of other tissue markers of EBV infection. Recently, however, a novel type of EBV latency has been demonstrated, without expression of the EBER genes in hepatocarcinoma tissue [35]. In our previous study we documented an EBER-negative pattern of EBV latency in children, as well as in adult patients with B-cell NHLs [36]. In general, expression of EBERs in present study has not significantly differed between children with B-cell NHLs and non-neoplastic material. In the group of B-cell NHLs the latency programme III have most frequently provided the suggested forms of latency. The patterns are most frequently encountered in Hodgkin's disease and in primary effusion lymphoma [13,34]. Latency III is also encountered in some post-transplant lymphoproliferative disorders and in lymphoblastoid cell lines [28]. This type of latency, defined also as the growth transcription programme, encompasses expression of all the nine latent proteins and is responsible for the capacity of EBV to transform normal, resting lymphocytes B *in vitro* to proliferating lymphoblasts. The programme remains under control of the EBNA2 gene [12]. In all, except one, of our children with the diagnosis of Burkitt's lymphoma tissue expression of EBV has been accompanied by expression of at least one of EBV proteins (EBNA2 and/or LMP1). This does not confirm the general observations of other authors on exclusive expression of EBNA1 and EBERs (latency I) in endemic Burkitt's lymphomas [2,7,13]. The expression of LMP1, in the absence of EBNA2, has already been observed in EBV positive acquired immunodeficiency syndrome (AIDS)-related BL cases [29,34]. Even we did not test all of the known viral proteins, we have provided potential EBV latency patterns *in vivo* in children with nonendemic forms of BL. In our tissue material the latency patterns have proven to be more complex than indicated by histological diagnoses and the till now published reports. In paediatric cases of Burkitt's lymphoma we have confirmed the numerous reports of other authors on the potential for a phenotypic drift from latency I to latency III, which has been observed previously in some BL cell lines and that a similar phenomenon may occur in Burkitt lymphoma *in vivo* [28]. Our

studies have demonstrated expression of various phenotypes of the two EBV latent proteins in a proportion of cells in B-cell NHL tumors in children and may supplement the till now described EBV latency forms in nonendemic areas. In the tissue material with the non-neoplastic lesions the type II latency prevailed, with expression of EBERs as well as of LMP2 protein. In the patients EBV DNA has also been demonstrated.

Several literature references back up the hypothesis that EBNA2 represents the principal inducer of LMP1 and LMP2 expression [2,7], even if also an *in vitro* evidence is available on the absence of correlation between expressions of the two proteins [37].

Our present results have demonstrated positive correlations between expression of EBNA2 and LMP1 as well as between that of the two proteins and EBERs in children with B-cell NHLs. Both EBNA2 and LMP1 are known to activate primary B lymphocytes and participate in their transformation, inducing expression of, *i.e.*, CD21 and CD23 genes [2,8,14,17]. The *in vitro* studies indicate that expression of CD21 is related to the stage of cell cycle and is more pronounced at the G1 phase. Higher amounts of CD21 have been observed in the more differentiated cells of human cell line of B lymphocytes [18].

In our studies no quantitative differences could have been noted in expression of CD21 between patients with B-cell NHLs as compared to the group with reactive stimulation of lymphoid system. Positive correlations involved reciprocal expression of CD21 and CD23 in B-cell NHLs children and non-neoplastic material. In both group of patients significantly more CD23 than CD21 has been detected. On the other hand, we have been unable to confirm the positive correlation between expression of EBV tissue markers and that of CD21/CD23 in B-cell NHLs and therefore, in our tumour patients, EBV has shown no significant effect on increased expression of the molecules. In the case of CD23 expression, which has been significantly lower in B-cell NHLs as compared to children with non-neoplastic lesions, this might be possibly explained by the modulating effect of EBNA2 (present only in B-cell NHLs) on expression of CD23. In the *in vitro* studies, EBNA2 protein decreased expression of CD23 on cell membranes, resulting in augmented level of CD23 steady-state RNA coding for the form A of the protein, which is not detectable at the cell surface but directly secreted [19].

We are unable to confirm the *in vitro* observations, indicating induction of CD21 and CD23 gene expression in primary B lymphocytes by EBV infection [8,14]. Involvement of EBNA2 and LMP1 in transformation of B lymphocytes in the form of *in vivo* activation of CD21 and CD23 molecules is probably of a more complex nature and may be related to the stage

of lymphocyte differentiation, as suggested by some authors of *in vitro* experiments [18].

Summing up, it should be stressed that studies employing various techniques of molecular biology have permitted for a more complete appraisal of the actual EBV expression in B-cell lymphomas, definition of the new latency forms of the virus and for precise detecting of EBV replication sites in the cells. The total detectability of EBV tissue markers both in B-cells NHLs (77%), and in the group of non-neoplastic lesions (64%) in our patients suggests that the notion of EBV infection representing a sufficient proof for the oncogenic action of EBV should be treated as highly equivocal. The definitely more pronounced cellular expression of latent tissue markers of EBV in B-cell NHLs children as compared to the non-neoplastic material may point to a potential role of EBV in pathogenesis of lymphoma in this group of population. Isolated detection of EBV DNA in tissue material should be treated with caution as a pathogenetic index if no EBV clonality tests have been performed. Other authors have also pointed to high proportion of EBV-positive persons who manifest no clinical signs/symptoms of EBV-related diseases [31, 33]. Except of EBV, recently various other potential co-factors are discussed of the endemic development of Burkitt's lymphoma, such as malaria, arboviruses and extracts of a commonly used plant, *Euphorbia tirucalli* [38]. Disclosure of such co-factors active in our geographic zone will involve further investigations and on a larger group of patients.

References

- [1] Roizman B. The family herpesviridae: general description, taxonomy, and classification. In: Roizman B, ed. *The herpesviruses*. New York. 1982:1-23.
- [2] Baumforth KRN, Young LS, Flavell KJ, Constandinou C, Murray PG. The Epstein-Barr virus and its association with human cancers. *J Clin Pathol: Mol Pathol*. 1999;52:307-322.
- [3] Jones JF, Shurin S, Abramowsky C et al. T-cell lymphomas containing Epstein-Barr viral DNA in patients with chronic Epstein-Barr virus infections. *N Engl J Med*. 1988;24:733-741.
- [4] Kobayashi I, Shima K, Saito I et al. Prevalence of Epstein-Barr virus in oral squamous cell carcinoma. *J Pathol*. 1999;189:34-39.
- [5] Sixbey JW, Davis DS, Young LS, Hutt-Fletcher L, Tedder TF, Rickinson AB. Human epithelial cell expression of an Epstein-Barr virus receptor. *J Gen Virol*. 1987;68:805-811.
- [6] Takada K. Role of Epstein-Barr virus in Burkitt's lymphoma. *Curr Top Microbiol Immunol*. 2001;258:141-151.
- [7] Kieff E, Rickinson AB. Epstein-Barr virus and its replication. In: Knipe DM, Howley PM, Griffin DE et al., eds. *Fields' Virology*, 4th ed., Philadelphia: Lippincott, Williams and Wilkins; 2001:2511-2573.
- [8] Wang F, Gregory C, Sample C et al. Epstein-Barr virus latent membrane protein (LMP1) and nuclear proteins 2 and 3C are effectors of phenotypic changes in B lymphocytes: EBNA-2 and LMP1 cooperatively induce CD23. *J Virol*. 1990; 64:2309-2318.

- [9] Tanner J, Weis J, Fearon D, Whang Y, Kieff E. Epstein-Barr virus gp350/220 binding to the B lymphocyte C3d receptor mediates adsorption, capping, and endocytosis. *Cell*. 1987; 50:203-213.
- [10] Protá AE, Sage DE, Stehle T, Fingeróth JD. The crystal structure of human CD21: implications for Epstein-Barr virus and C3d binding. *Proc Natl Acad Sci USA*. 2002;99:10641-10646.
- [11] Borza CM, Hutt-Fletcher LM. Alternate replication in B cells and epithelial cells switches tropism of Epstein-Barr virus. *Nature Med*. 2002;8:594-599.
- [12] Hochberg D, Middeldorp JM, Catalina M, Sullivan JL, Luzuriaga K, Thorley-Lawson DA. Demonstration of Burkitt's lymphoma Epstein-Barr virus phenotype in dividing latently infected memory cells in vivo. *Proc Natl Acad Sci USA*. 2004;101:239-244.
- [13] Kuppers R. B cell under influence: transformation of B cells by Epstein-Barr virus. *Nature Rev*. 2003;3:801-812.
- [14] Cordier-Bussat M, Billaud M, Calender A, Lenoir GM. Epstein-Barr virus (EBV) nuclear-antigen-2-induced up-regulation of CD21 and CD23 molecules is dependent on a permissive cellular context. *Int J Cancer*. 1993;53:153-160.
- [15] Dirmeier U, Neuhierl B, Kilger E, Reisbach G, Sandberg ML, Hammerschmidt W. Latent membrane protein 1 is critical for efficient growth transformation of human B cells by Epstein-Barr virus. *Cancer Res*. 2003;63:2982-2989.
- [16] Young LS, Murray PG. Epstein-Barr virus and oncogenesis: from latent genes to tumours. *Oncogene*. 2003;22:5108-5121.
- [17] Boyd AW, Fecondo J. Role of the CD21 antigen in lymphocyte transformation by Epstein-Barr virus. *Immunol Cell Biol*. 1988;66:159-165.
- [18] Pillemer SR, Tsokos GC, Barbieri SA, Balow JE, Golding B. The CR2 receptor (CD21) shows increased expression in the more differentiated cells of an antigen-specific B cell line. *Cell Immunol*. 1990;125:386-395.
- [19] Shore A, Dosch HM, Gelfand EW. Expression and modulation of C3 receptors during early T-cell ontogeny. *Cell Immunol*. 1979;45:157-166.
- [20] Stevenson M, Volsky B, Hedenskog M, Volsky DJ. immortalization of human T lymphocytes after transfection of Epstein-Barr virus DNA. *Science*. 1986;233:980-984.
- [21] Young LS, Sixbey JW, Clark D, Rickinson AB. Epstein-Barr virus receptors on human pharyngeal epithelia. *Lancet*. 1986; 1:240-242.
- [22] Hsu SM, Raine L, Fanger H. Use of avidin-biotin-peroxidase complex (ABC) in immunoperoxidase techniques. *J Histochem Cytochem*. 1981;29:577-580.
- [23] Kasprzak A, Zabel M, Wysocki J et al. Detection of DNA, mRNA and early antigen of the human cytomegalovirus (HCMV) using Immunomax technique in autopsy material of children with intrauterine infection. *Virchows Arch*. 2000; 437:482-490.
- [24] Remmele W, Stegner HE. Vorschlag zur einheitlichen Definition eines immunoreactiven Score (IRS) für den Immunohistochemischen Östrogenrezeptor - Nachweis (ER-ICA) im Mammakarzinomgewebe. *Pathologie*. 1987;8:138-140.
- [25] Habeshaw G, Yao QY, Bell AI, Morton D, Rickinson AB. Epstein-Barr virus nuclear antigen 1 sequences in endemic and sporadic Burkitt's lymphoma reflect virus strains prevalent in different geographic areas. *J Virol*. 1999;73:965-975.
- [26] Tao Q, Robertson KD, Manns, Hildesheim A, Ambinder RF. Epstein-Barr virus (EBV) in endemic Burkitt's lymphoma: molecular analysis of primary tumor tissue. *Blood*. 1998;91: 1373-1381.
- [27] Gregory CD, Rowe DM, Rickinson AB. Different Epstein-Barr virus (EBV) B cell interactions in phenotypically distinct clones of a Burkitt lymphoma cell line. *J Gen Virol*. 1990; 71:1481-1495.
- [28] Niedobitek G, Agathangelou A, Rowe M et al. Heterogeneous expression of Epstein-Barr virus latent proteins in endemic Burkitt's lymphoma. *Blood*. 1995;86:659-665.
- [29] Carbone A, Gloghini A. Expression of Epstein-Barr virus-encoded latent membrane protein 1 in nonendemic Burkitt's lymphomas. *Blood*. 1995;87:1202-1204.
- [30] Niedobitek G, Agathangelou A, Herbst H, Whitehead L, Wright DH, Young LS. Epstein-Barr virus (EBV) infection in infectious mononucleosis: virus latency, replication and phenotype of EBV-infected cells. *J Pathol*. 1997;182:151-159.
- [31] Walling DM, Brown AL, Etienne W, Keitel WA, Ling PD. Multiple Epstein-Barr virus infection in healthy individuals. *J Virol*. 2003;77:6546-6550.
- [32] Idesawa M, Sugano N, Ikeda K et al. Detection of Epstein-Barr virus in saliva by real-time PCR. *Oral Microbiol Immunol*. 2004;19:230-232.
- [33] Cheung WY, Chan ACL, Loke SL et al. Latent sites of Epstein-Barr virus infection. *Am J Clin Pathol*. 1993;100: 502-506.
- [34] Hamilton-Dutoit SJ, Rea D, Raphael M et al. Epstein-Barr virus-latent gene expression and tumor cell phenotype in acquired immunodeficiency syndrome-related non-Hodgkin's lymphoma. Correlation of lymphoma phenotype with three distinct patterns of viral latency. *Am J Pathol*. 1993;143: 1072-1085.
- [35] Sugawara Y, Mizugaki Y, Uchida T et al. Detection of Epstein-Barr virus (EBV) in hepatocellular carcinoma tissue: a novel EBV latency characterized by the absence of EBV-encoded small RNA expression. *Virology*. 1999;256:196-202.
- [36] Kasprzak A, Spachacz R, Hałóń A et al. Tissue markers of Epstein-Barr virus (EBV) infection in B-cell non-Hodgkin's lymphomas. *Med Wieku Rozwoj*. 2006;X:639-648.
- [37] Cordier-Bussat M., Calender A, Vuillaume M, Bornkamm GW, Lenoir GM. Expression of the Epstein-Barr virus (EBV) latent membrane protein is tightly regulated, independently of EB nuclear antigen 2 and of EBV integration or copy number. *Virus Res*. 1993;27:55-69.
- [38] van den Bosch CA. Is endemic Burkitt's lymphoma an alliance between three infections and a tumour promoter? *Lancet*. 2004;5:738-746.

Submitted: 26 February, 2007

Accepted after review: 19 April, 2007