

Histological and immunohistological aspects of the ovarian cycle of the algerian wild sand rat, *Psammomys obesus* Cretzschmar, 1828

Amina Boubekri¹, Thérèse Gernigon-Spychalowicz¹, Farida Khammar¹, Jean-Marie Exbrayat²

¹Université des Sciences et de la Technologie Houari Boumédiène, Faculté des Sciences Biologiques, Laboratoire de Recherche sur les Zones Arides, Alger, Algérie

²Université de Lyon, Laboratoire de Biologie Générale, Université Catholique, Laboratoire de Reproduction et Développement Comparé, E.P.H.E. Lyon, France

Abstract: The sand rat, *Psammomys obesus*, is largely used as a model for studying several metabolic disorders. In order to perform breeding laboratory conditions, the reproductive function of this species was investigated. Using histological and immunohistochemical techniques, several aspects of the ovaries were studied throughout the sexual cycle. During the ovarian cycle, the different stages of folliculogenesis, from primordial to Graafian follicle, have been shown; the differentiation of both granulosa and theca cells, the formation of the antrum, cumulus oophorus and corona radiata were described. Broken follicles and corpora lutea have been observed, confirming a spontaneous ovulation in isolated females. Steroid activities were analysed using immunohistochemical techniques. Estrogen, androgen and progesterone hormones were visualized in the different compartments of the ovary.

Key words: Ovary - Folliculogenesis - Histology - Immunohistochemistry - Sand rat - Rodents.

Introduction

The sand rat, *Psammomys obesus*, is largely used as a model for studying several metabolic disorders. This gerbillidae living in desert areas [1] is strictly submitted to Chenopodiaceae, rich in salt and water [2]; when it is confined to a standard laboratory diet, *Psammomys obesus* develops diabetes [3] and other pathology [4,5]. In laboratory conditions, breeding of this animal is difficult [6,7]. In order to perform breeding of Algerian *Psammomys obesus*, the reproductive function of this species was investigated. In the male, different studies were already published [8-11]. In the female, the estrous cycle, and the histological and cytological seasonal variations of the gonads and reproductive tract were studied [12-16]. The purpose

of the present study was to describe several structural and functional aspects of the ovaries of *Psammomys obesus*, living in Algerian Sahara. Immunohistochemical methods allowed us to study ovarian function, the preliminary results were presented.

Materials and methods

Animals. The sand rat, *Psammomys obesus* Cretzschmar, 1828, is a diurnal rodent, belonging to Gerbillidae family. Animals were caught from Beni-Abbes area: 30°7N-2°10W of North Occidental Algerian Sahara. Chenopodiaceae vegetation constituted their diet. In laboratory, the sex of animals was determined and individuals isolated in cages. Only adult non-pregnant females were used.

Methods. Estrous cycles were monitored by daily vaginal smears and only the animals exhibiting a minimum of two consecutive 4-5 day long estrous cycles [12] were considered. At each phase of the estrous cycle, three females were killed. In order to proceed to histological and immunohistological studies, ovaries were removed and fixed in Bouin's solution or in 4% paraformaldehyde in phosphate buffered saline solution [17-19]. Some ovaries were frozen in liquid nitrogen and preserved at -70°C for next studies. Ovaries were embedded in paraffin wax (Merck, Germany) and serially sectioned at 5µm in thickness (Leitz vertical microtome). The sections were mounted on normal or Super Frost glass slides.

Correspondence: A. Boubekri, Université des Sciences et de la Technologie Houari Boumédiène, Faculté des Sciences Biologiques, Laboratoire de Recherche sur les Zones Arides, BP 132 El Alia 16100 Alger, Algeria; tel.: (+21321) 47950, fax.: (+21321) 247217, e-mail: Boubekri_a@yahoo.fr, khammar@yahoo.fr, tgermigon@yahoo.com, jmexbrayat@univ-catholyon.fr

For immunohistochemistry, prior to hormonal localization, the protocol was performed as presented in [20]. After dewaxing and hydrating, the sections were surrounded with Pap Pen, and treated with 3% hydrogen peroxide to inhibit endogenous peroxidase activity, then they were rinsed in PBS buffer (Sigma pH=7.4; 0.01 M). The primary antibody was applied during 30 minutes at room temperature (Rabbit anti-17 β -estradiol antibody (Biomeda), Rabbit anti-progesterone (Biomeda) and then rinsed three times for 5 minutes in PBS. The secondary antibody is biotinylated and applied directly on the primary antibody during 30 minutes at ambient temperature. After applied streptavidin-peroxidase during 30 minutes, the enzymatic reaction was visualised by the use of the substrate-chromogen solution (Amino-Ethyl-Carbazole: AEC) during 10-15 minutes at ambient temperature. The sections were counterstained with aqueous hematoxylin and then mounted in aqueous medium (Crystal mount).

Histological analysis. The ovarian sections were viewed and examined at different magnifications, and photographed with a Zeiss photomicroscope. The follicles were classified as healthy or atretic. Follicles were considered atretic if two or more pyknotic granulosa cells were found on the same section or if the oocyte was completely degenerate [21,22]. Morphometric study was performed according to Gougeon (1996) [23]. These measures were made [24,25] only in the section containing the nucleus of the oocyte [22].

Results

Histological results

General histology of ovaries. Each ovary was normally enclosed in a fibrous capsule. Two compartments were distinguished: the peripheral zone or cortex, the most important part, with many follicles in various stages of growth, the sizes and morphology of which being very different; and the medulla with an important blood network. The hilus region, loosely connected the ovary with the oviduct (Fig. 1). Degenerated follicles were also observed. Corpus luteum and albicans were scattered in the stroma.

Ovarian follicles: histology of the folliculogenesis. The edge of the ovary was covered by a single squamous or cuboidal germinal epithelium; surrounded with, the tunica albuginea, a dense connective tissue. At periphery of the cortex, numerous primordial follicles of 17-20 μ m in size were observed (Fig. 2). Each one contained a primary oocyte (arrested in prophase of the meiotic division), of 11-15 μ m in diameter, surrounded by two or three flattened follicular cells. Some intermediary follicles presented both flattened and cuboidal follicular cells were observed.

Primary follicles. Primary follicles were also seen. Here, the oocytes were now surrounded with a thin zona pellucida, and a granulosa constituted as a single layer of cuboidal cells. The basement membrane (membrane of Slavjansky) was clearly apparent. The diameter of primary follicles can be different according to the average diameter of the oocyte (Fig. 3). The smallest primordial follicles were surrounded by 8 to 13 follicular cells and the average diameter was

27.5 μ m, the oocytes were 16.3 μ m in mean diameter. The largest primordial follicles were surrounded by 25-29 follicular cells and were 63.5 μ m in mean diameter. The oocytes reached 38.5 μ m in mean diameter. These observations indicated that the oocyte enlarged in the largest primary follicles, started the maturation and the growth process. Few primary follicles appeared surrounded by some stromal cells. This envelope could be the undifferentiated theca cells, the *Theca folliculi*. Some primary growing follicles were recognisable by proliferating granulosa cells.

Secondary follicle or preantral follicle. The follicles were centred by the oocyte. This oocyte contained a central nucleus, the germinal vesicle, with many nucleoli. The size of the oocyte was constant whatever the preantral follicle. In the small ones, the granulosa was 2-3 cells thick, the zona pellucida appeared clearly stained with periodic acid-Schiff. The preantral follicles were characterised by an enlarged granulosa. The proliferating follicular cells expressed an intense mitotic activity (Fig. 4). The granulosa cells appeared as an homogeneous. As the preantral follicle grew, the division of granulosa cell continued and the number of layers increased to form a stratified epithelium, 2 to 10-12 layer cells thick. When preantral follicle reached a diameter of about 225 μ m with a 6 to 12 cells-thick granulosa, the theca interna differentiated and the antral cavity began to be formed. In the largest healthy follicles, 275 μ m in mean diameter, the inner cells of the theca folliculi, was composed of large spindle-shaped or polyhedral cells with oval or elliptical nuclei and forms an epithelioid layers of 3 or 4 cells layers; the outermost follicular cells were flattened; they were arranged as a concentric arrangement and enmeshed in a network of connective fibers. This part was well vascularized and formed the wall of the follicle; the *theca folliculi* differentiated into *theca interna* and *theca externa* (Figs. 4 and 5). Irregular spaces appeared among the cells of granulosa, filled with follicular fluid.

Tertiary follicle or antral follicle. The largest healthy preantral follicles developed from the early small antral stage. Its size increased by a proliferation of cells and the accumulation of fluid to form the antrum, a single cavity. Follicle morphology changed progressively. The oocyte quickly grew and reached 70 μ m in the largest antral follicles. The volume of antrum increased by confluence of the intercellular spaces. Some granulosa cells surrounding the oocyte appeared closely associated between them, constituting the cumulus oophorus, the compact cumulus cell-oocyte complex. The peripheral granulosa layer cells, observed near the basement membrane, formed the mural granulosa cells (Fig. 6). In the theca, the theca

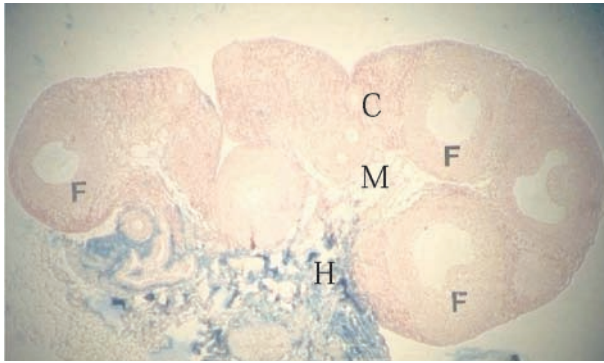


Fig. 1. Ovarian morphology of the sand rat. Transection of the entire ovary shows different regions: cortex (C) with many growing follicles (F), medulla (M) with important connective tissue and blood vessels and the hilus (H). Heidenhain Azan (magnification $\times 70$).

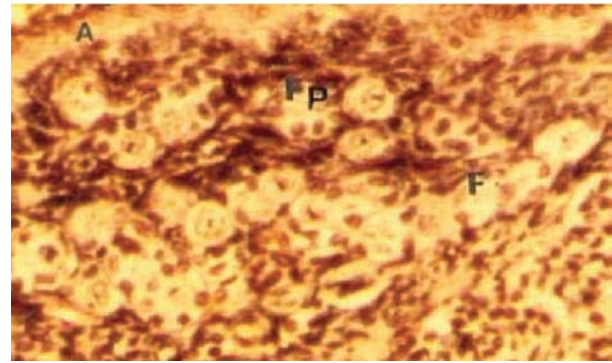


Fig. 2. Primordial follicles in the cortex of the sand rat ovary. Part of peripheral cortex with primordial follicles: primary oocytes surrounded by few flattened follicular cells. A: Albuginea. Masson Trichrome (magnification $\times 200$).

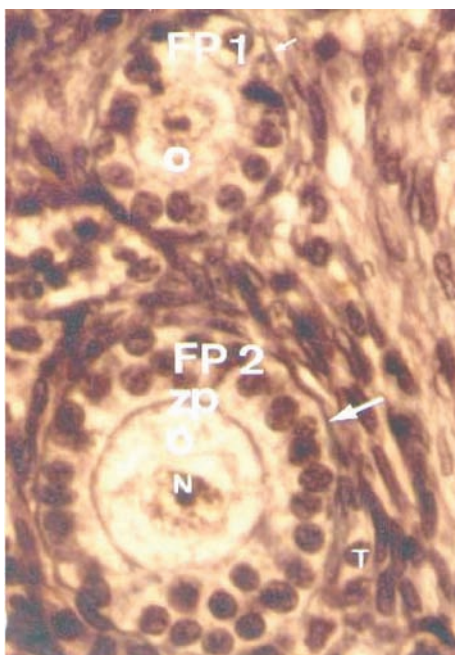


Fig. 3. Primary follicles in the sand rat ovary. Oocytes were surrounded by a single complete layer of cuboidal granulosa cells. Note the presence of small (Fp1) and large (Fp2) primary follicles that differ in diameter by the mean diameter of their oocyte (O). The arrow: Lamina basalis, T: Theca folliculi, N: nucleus, ZP: Zona pellucida. Masson Trichrome (magnification $\times 500$).

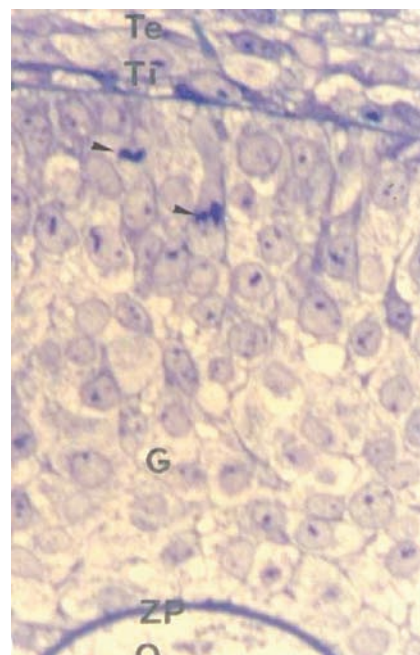


Fig. 4. Preantral follicle in the sand rat ovary. A part of large healthy preantral follicle with: morphological differentiation of the theca folliculi into theca externa (Te) and theca interna (Ti). The arrow: proliferating granulosa (G) cells, ZP: clearly structured zona pellucida, O: Primary oocyte. Semithin sections. Methylene Blue (magnification $\times 500$).

interna appeared more pronounced than previously (Fig. 7). The large healthy antral follicles developed from the maturing follicles to form preovulatory follicles; in *Psammomys*, healthy, largest antral follicle in terminal growth, were also observed. These preovulatory follicles were characterized by the large size that reached about 500 μm diameter; these oocytes occupied the centre of the follicle but the germinal vesicle became eccentric in position. The granulosa cells surrounding the oocyte, formed a ring, the corona radiata. The oocyte was embedded in the cumulus area (Fig. 8) that became limited by the enlarging antrum. The mural granulosa was clearly seen.

Ovulatory follicle. Ovulatory follicles were observed during estrus. The healthy largest follicles in terminal growth, were mature follicles or Graafian follicles. They occupied a large part of the ovarian cortex and were nearly to the free surface of the gonad. In *Psammomys*, Graafian follicles (Fig. 9) were characterised by the presence of secondary oocyte in which the second meiotic division metaphase was observed, indicating the germinal vesicle breakdown. This follicle was observed after LH surge (Fig. 10). At this stage, the cumulus cell-oocyte complex formed a thick region protruding into the antrum. The connection with the rest of the granulosa cells was reduced. The follicular wall changed in aspect;

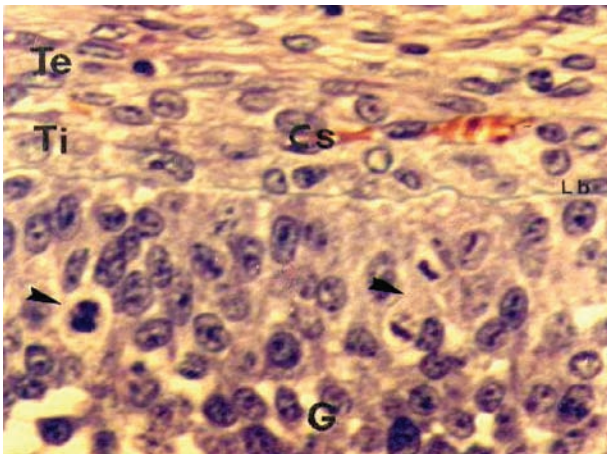


Fig. 5. Early antral follicle in the sand rat ovary. Differentiated theca into theca externa (Te) and epithelioid theca interna (Ti). Te: Flattened cells of the theca externa both well vascularised, Cs: Capillary. The arrow: dividing granulosa (G) cells. Lb: lamina basalis. Masson Trichrome (magnification $\times 500$).

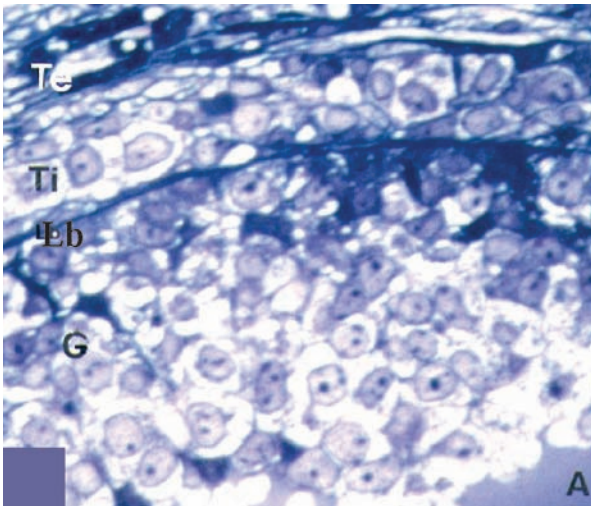


Fig. 7. Preovulatory follicle in the sand rat ovary. Healthy, large follicle of 514 μ m. Note the pronounced differentiation of the theca on theca externa (Te) and theca interna (Ti). G: granulosa; A: Antrum; Lb: lamina basalis. Semithin section. Methylene Blue (magnification $\times 500$).

the basement membrane became blurred and the blood vessels of the theca deeply penetrated in the theca interna (Fig. 11). The region in which the follicle was near the surface of the ovary became thinner. The germinal epithelium overlying this area became squamous; the ovulation will take place at this level. In the *Psammomys obesus*, the ovulation process occurred in a cyclic manner every 5–1 days in normal estrous cycle (Fig. 12). At this time, the oocyte surrounded with the cumulus oophorus was found in the oviduct lumen (Fig. 13). The broken follicles were observed in the ovary. Mural granulosa and the theca cells remained in the follicle. The collapsed follicular wall was undergoing luteinization to form the corpus luteum.

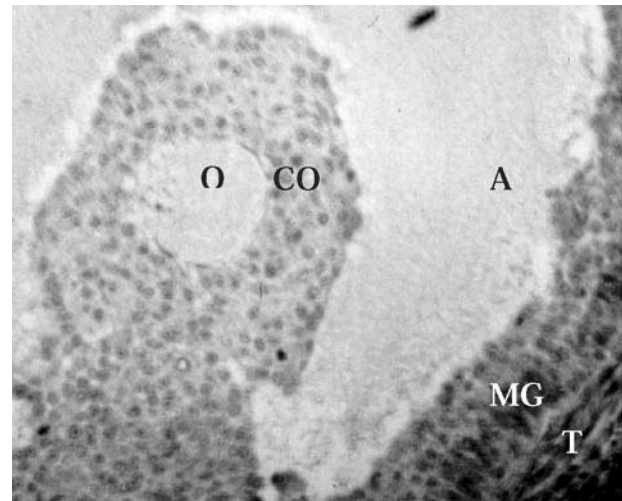


Fig. 6. Antral follicle morphology in the sand rat ovary. Part of large healthy antral follicle with: the Theca folliculi (T), the mural granulosa (MG), the antrum (A) and the cumulus oophorus (CO). O: The primary oocyte remains central. Masson Trichrome (magnification $\times 70$).

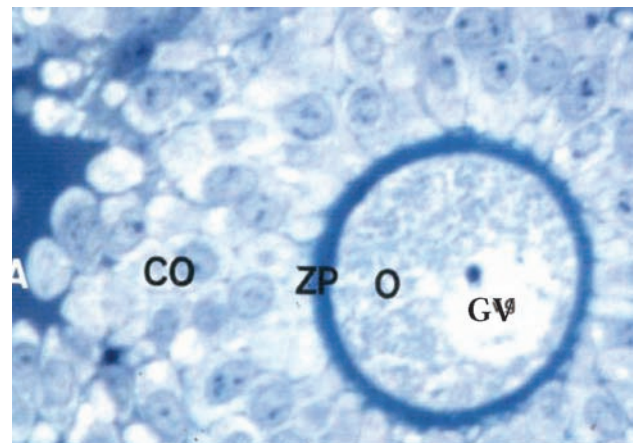


Fig. 8. Primary oocyte in preovulatory follicle of the sand rat. The primary oocyte (O), with intact germinal vesicle (GV), surrounded by the zona pellucida (ZP) and the cumulus oophorus (CO). A: antrum. Semithin section. Methylene Blue (magnification $\times 500$).

Corpus luteum formation. Following the ovulation, the luteal phase was characterised by numerous corpora lutea. The histology of the broken follicle wall changed with luteinization. The vessels of the theca interna sprouted and invaded the follicle. The granulosa cells, now in relation with the capillary vessels, became enlarged and lighter, forming the granulosa lutein cells; the theca cells were entrained with blood among the granulosa cells; they appeared darker and became the thecal lutein cells (Fig. 14). Finally, both these two types of lutein cells formed an homogeneous luteum tissue; the invasion of the broken follicle with blood vessels and connective tissue forming a central clot; these corpora lutea (Fig. 15) were formed in

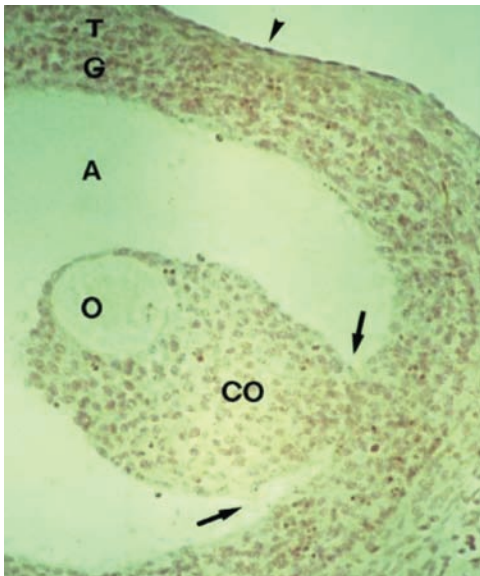

Fig. 9. Female in estrus. Healthy, large follicle of about 520 micrometers diameter. The secondary oocyte (O) remains central. The final enlargement of the follicle induced the protrusion (the arrows) of the ooculus oophorus complex (CO and O) into the antrum cavity (A). T: theca. G: Mural granulosa; Arrowhead: Apex. Masson Trichrome (magnification $\times 70$).

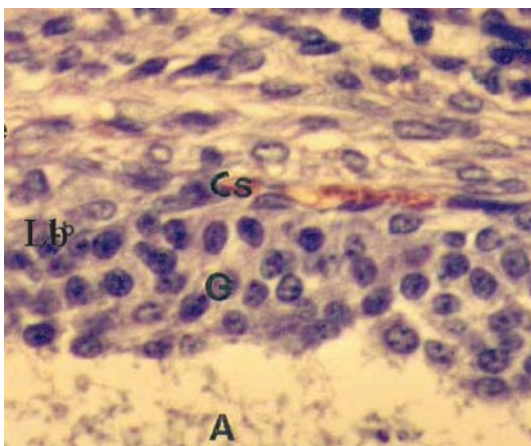


Fig. 11. Part of the follicular wall in ovulatory follicle. Note the deep theca blood vessels and the lamina basalis (Lb) that becomes blurred. G: mural granulosa. A: antrum. Masson Trichrome (magnification $\times 500$).

cyclic manner. In the isolated *Psammomys* females used for this study, the corpus luteum histologically and functionally decreased. The lutein cells became loaded with lipid in connective tissue, at the end of luteal phase, the corpus luteum degenerated and became corpus albicans.

Follicle atresia. In *Psammomys* ovary, the atresia was observed at all stages of follicle development. In the atretic follicles, we observe numerous cells with pyknotic and apoptotic nucleus process. Many oocytes

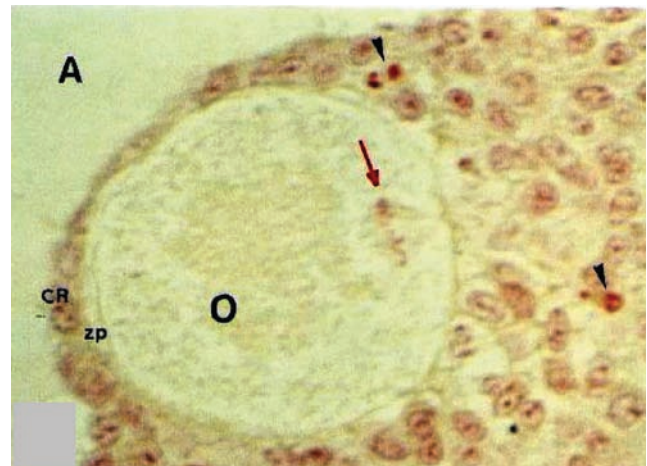


Fig. 10. Secondary oocyte from an ovulatory follicle. Note the alignment of the chromosomes along the metaphase plate of the second meiotic division (Arrow). O: oocyte; ZP: zona pellucida; CR: corona radiata; A: antrum. Arrowhead: apoptotic cells that appear normally in ovulatory follicle. Masson Trichrome (magnification $\times 500$).

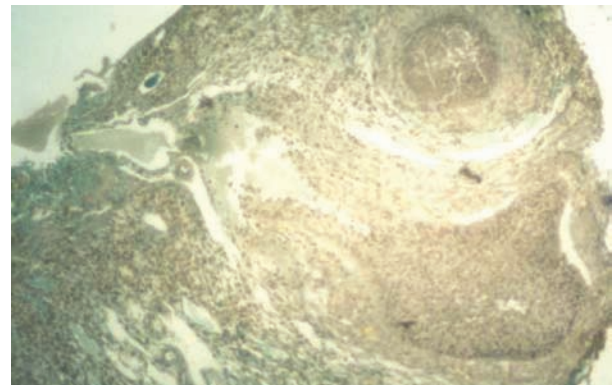


Fig. 12. Ruptured follicle at ovulation. The collapsed follicular wall was consisted of the mural granulosa and theca cells. Masson Trichrome (magnification $\times 200$).

were in pseudomaturing phase or became eccentric, essentially in preantral follicles.

Preliminary immunohistological results

To study functional aspect of ovarian *Psammomys obesus*, in the reproductive period, immunohistochemistry was used prior to hormonal localization. 17-estradiol antibody, allowed to localize this steroid hormone in follicular cells. In antral follicle, significant immunoreactivity was observed in both the oocytes and granulosa cells. Theca cells were totally devoid of label (Fig. 16). In the cell, the immunoreactivity had cytosolic localisation (Fig. 18).

Progesterone antibody label was observed in different part of the ovary; in the larger preantral follicle and

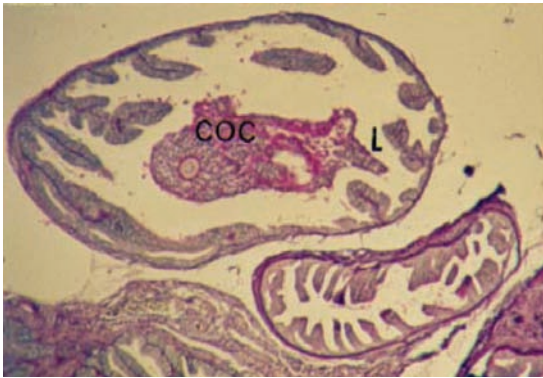


Fig. 13. Released oocyte complex at ovulation in the sand rat oviduct. Oocyte that is surrounded by the cumulus oophorus cells (COC) is found in the oviduct lumen (L). Acid Periodic Schiff-Groath Hematoxylin (magnification $\times 70$).

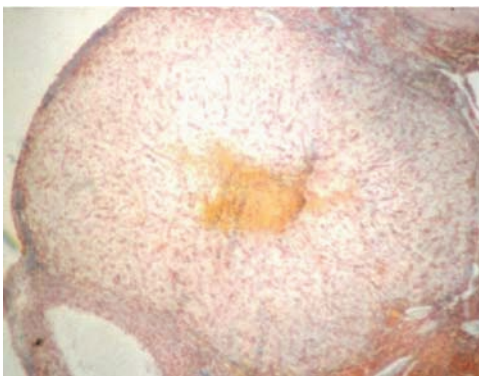


Fig. 15. Corpus luteum of the cycle in *Psammomys obesus* ovary. Mixture of granumosa lutein cells, theca lutein cells and blood vessels. Heidenhain Azan (magnification $\times 500$).

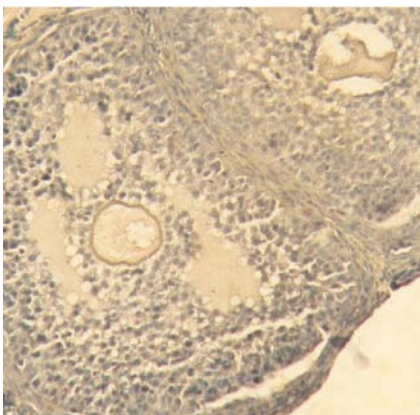


Fig. 17. Immunohistochemistry control reaction: by omission of the first antibody. Hematoxylin (magnification $\times 200$).

in antral follicle, the theca interna cell have a stronger immunostaining than the granulosa. The oocyte was slightly labelled (Fig.19). The immunoreactivity was important in the stroma. In the corpus luteum, luteal cells express the progesterone antibody (Fig. 20) and the 17β -estradiol antibody labels (Fig. 21); the first

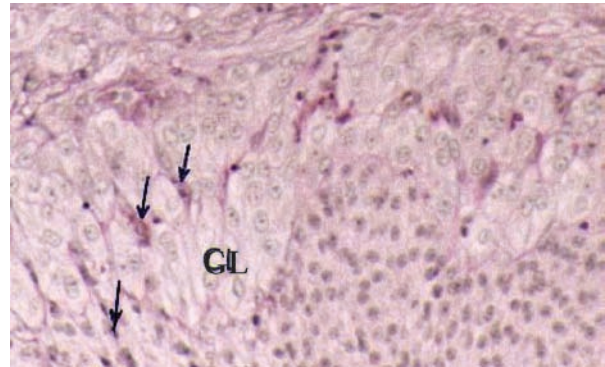


Fig. 14. Corpus luteum formation after ovulation. Histological changes of the ruptured follicle wall. The vessels sprout and invade the follicular tissue (arrows). Granulosa cells become enlarged and formed granumosa lutein cells (GL); the theca cells, were entrained by the blood among the granulosa cells, appear darker and become theca lutein cells. Acid Periodic Schiff-Groath Hematoxylin (magnification $\times 500$).

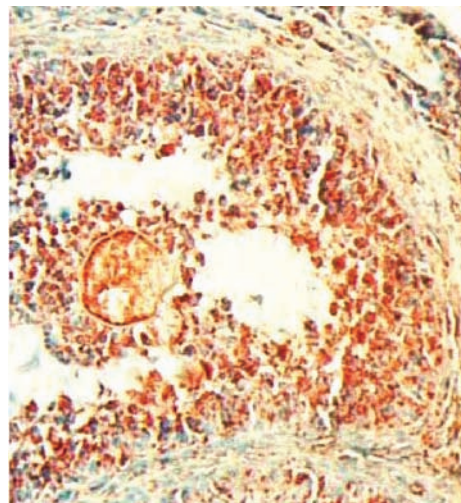


Fig. 16. Immunohistochemical localisation of 17β -estradiol in antral follicle. Stronge immuno-reactivity was observed in both the oocytes and granulosa cells, theca cells were totally devoid of label. Anti 17β -estradiol antibody. Chromogen: AEC (magnification $\times 200$).

one was heavily. This immunohistological study is still in progress; the steroid hormones distribution of labelled and unlabeled cells is studied in the different compoments and cells in the different types of follicle (growing or atretic) and during the phases of the oestrous cycle.

Discussion

The ovarian follicle has two major functions. It provides for the maturation and release of a fertilizable oocyte. It also forms the corpus luteum, which promotes and maintains implantation of the embryo. For these processes to occur, the follicle has to grow, ovu-

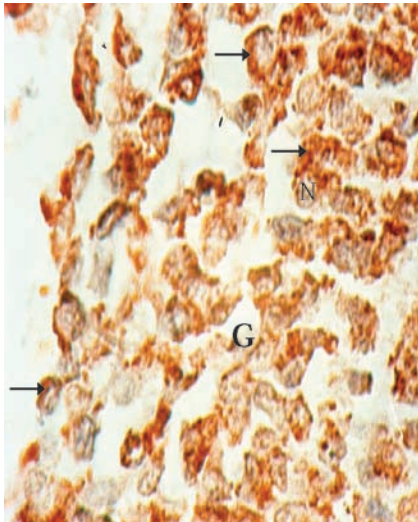


Fig. 18. Cytosolic localisation of 17 -estradiol antibody in the granulosa cells of preantral follicle of *Psammomys obesus*. Arrows: cytosolic label. G: granulosa cells; N: nucleus. Staining red (magnification $\times 500$).

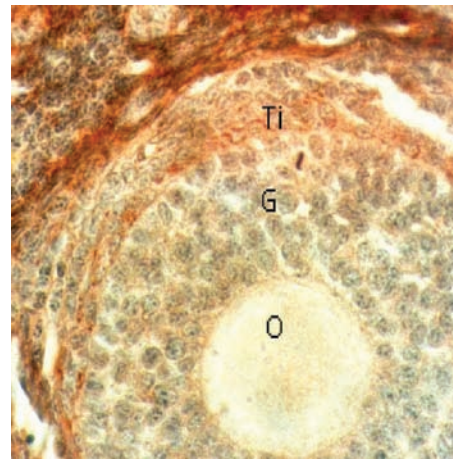


Fig. 19. Immunohistochemical localisation of progesterone in a large preantral follicle. The theca interna cell (Ti) have more intense immunostaining than the granulosa (G), while the oocyte (O) was moderately label; the immunoreactivity was distinctly in the stroma. Anti-progesterone antibody. Chromogen: AEC (magnification $\times 200$).

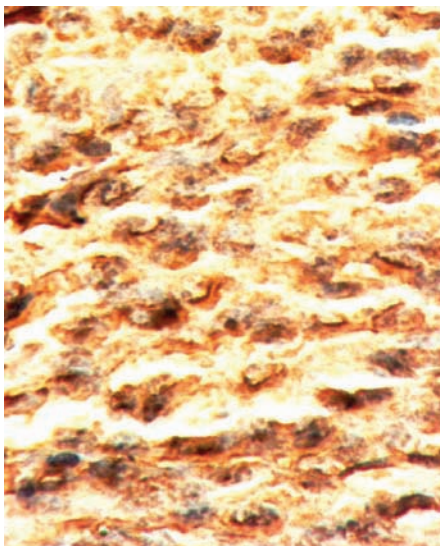


Fig. 20. Immunohistochemical visualisation of progesterone in the corpus luteum cells of ovarian sand rat. Chromogen: AEC (magnification $\times 500$).

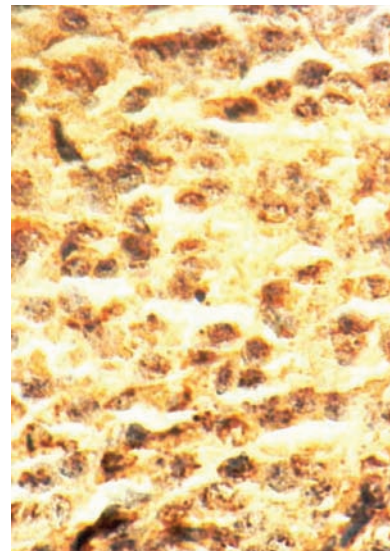


Fig. 21. Immunohistochemical visualisation of 17 -estradiol antibody binding in the corpus luteum cells of ovarian sand rat. Chromogen: AEC (magnification $\times 500$).

late, and luteinize [26]. The histological study, of the ovarian wild sans rat, *Psammomys obesus*, show that during the ovulatory cycle, the different stages of folliculogenesis, progressing from primordial to Graafian follicle, occurs normally; the differentiation of both granulosa and theca cells, the formation of the antrum, cumulus oophorus and corona radiata have been described. The broken follicles and numerous corpora lutea have been observed, confirming a spontaneous ovulation in isolated *Psammomys* females as estimated by the estrous cycle study [12,13].

Primordial, intermediary and primary follicles constituted the population of nongrowing follicles as defined by Gougeon and Chainy (1987) [27] in women. In mature rats, this population is mainly composed of primordial follicles [28]. In *Psammomys*, these three types of follicles were continually observed. The histomorphological process of folliculogenesis in the growing follicles developing from preantral to ovulating follicles observed in *Psammomys obesus*, appear similar to that described in the mouse [29,30], the rat [31], the hamster [32,33] and the mon-

golian gerbil [34]. The ovulatory process involves resumption of oocyte meiosis, the break of the follicular wall and luteinization, all these changes are induced synchronously by the preovulatory LH surge [26], this process were observed in *Psammomys obesus* at oestrus. Indeed, we have observed the morphological changes that express the maturation of the oocyte, the break of the Graafian follicle and the structural process of luteinization. Follicular growth and development has three stages: recruitment, selection and dominance, those stages have been studied using histomorphometrical relationship changes [12,15,16]. The steroidogenic pathway within the ovary gives rise to progestins, androgens and oestrogens. In *Psammomys obesus*, the steroid activities were analysed by means of immunohistochemical techniques to localise the ovarian steroid hormones, in a first step and then to detect the cellular enzymatic content that relate to follicular steroidogenesis. In addition to its role in triggering the preovulatory surge of gonadotropins, estradiol is an important intraovarian growth, differentiation, and survival factor in *Psammomys obesus*, though the granulosa cells of antral follicle were strongly immunoreactive than the theca cells, the precise localisation of the P450 aromatase is necessary. In the present work, we have described the folliculogenesis process, in the wild sand rat, *Psammomys obesus* ovaries, by histomorphological study and immunohistological approach.

Acknowledgments: I would like to thank the technicians of the Unite de Recgerche sur les Zones Arides (FSB) in Béni-Abbes for trapping the animals. Immunohistochemical part of this work was supported by Accord programme algéro-français 00 MDU 489 CMEP. Thanks to Dr. J. Estabel for advice on immunohistochemical methods and Ms. M.T. Laurent for there kindly assistance.

References

- [1] Petter F. Répartition géographique et écologique des rongeurs désertiques (du Sahara occidental a l'Iran oriental). *Mammalia*. 1961;25:N° Spécial.
- [2] Daly M, Daly S. On the feeding ecology of *Psammomys obesus* (Rodentia, Gerbillidae) in the Wadi Saoura, Algeria. *Mammalia*. 1973;37:546-561.
- [3] Schmidt-Nielsen K, Haines H, Hackel DB. Diabetes mellitus in the sand rat induced by standard laboratory diets. *Science*. 1964;143:689-690.
- [4] Von Dorsche HH, Scheven C, Stiller KJ, Timm D. Quantitative histochemical study of pancreatic islets of the sand rats (*Psammomys obesus*) in diabetes mellitus. I.1 Cytomorphometric measurement of insulin content. *Acta Histochem*. 1984;75:199-203.
- [5] Silberberg R. The vertebral column of diabetic rat (*Psammomys obesus*). *Exp Cell Biol*. 1988; 56:217-220.
- [6] Chirvan-Nia P, Ratsimamanga AR. Conditions permettant une plus longue survie et la reproduction de *Psammomys* (rat des sables) maintenu en laboratoire. *CR Acad Sc Paris*. 1973;277: 2727-2730.
- [7] Alder JH, Roderig CH, Gutman A. Breeding sand rats (*Psammomys obesus*) with a diabetic predisposition for laboratory investigations. *Refuah Vet*. 1976;33:1-8.
- [8] Amirat Z, Khammar F, Brudieux R. Variations pondérales saisonnières de l'appareil reproducteur, de la surrénale et du rein chez le Rat des sables (*Psammomys obesus*) du Sahara occidental algérien. *Bull Soc Hist Nat Afr Nord*. 1975;66: 31-60.
- [9] Khammar F, Brudieux R. Seasonal changes in plasma concentration of gonadotropins and in the responsiveness of the pituitary and the testis to GnRH in a desert rodent, the sand rat (*Psammomys obesus*). *Reprod Nutr Dev*. 1991;31:675-682.
- [10] Gernigon T. *Etudes cytologiques et biochimiques des variations saisonnières de l'appareil reproducteur mâle d'un rongeur saharien diurne, le Rat des sables (Psammomys obesus)*. These Doct. Etat, USTHB, Alger ; 1992.
- [11] Gernigon T, Berger M, Lecher P. Seasonal variations of ultrastructure and production of androgen-dependent proteins in the seminal vesicles of a Saharian rodent (*Psammomys obesus*). *J Endocr*. 1994;142:37-46.
- [12] Boubekri A, Khammar F, Gernigon T. The oestrous cycle of *Psammomys obesus*, (Rodentia, Gerbillidae) living in algeria. In: Zaime A. (Ed.) *Biodiversity and adaptation, Proceeding Fifth Rodens et Spatium*, Rabat, Maroc. 1996: 149-154.
- [13] Boubekri A. Etude histologique et cytologique des variations saisonnières de l'appareil reproducteur femelle d'un rongeur déserticole diurne, le rat des sables, *Psammomys obesus* Cretzschmar, 1828, dans son biotope. These de Magister, FSB-USTHB, Alger; 1998.
- [14] Boubekri A, Gernigon T. Variations saisonnières de la fonction de reproduction femelle, d'un rongeur déserticole diurne, le rat des sables, dans son biotope : adaptation structuro-fonctionnelle. *Premieres Journées Franco-tunisiennes de la Zoologie*. Septembre 1999, Nabeul, Tunisie.
- [15] Boubekri A, Gernigon T, Khammar F, Exbrayat JM. Normal cyclic ovarian function in Algerian sand rat, *Psammomys obesus*. *8th International conférence Rodens Spatium*. July 2002, Louvain-la-Neuve (Belgium).
- [16] Boubekri A, Gernigon T. Variations saisonnières de l'activité ovarienne du Rat des sables, *Psammomys obesus*, du Sud ouest algérien. *38^{eme} Congrès de la Société Francophone de Chronobiologie*. Mai 2006, Lyon.
- [17] Martoja R, Martoja-Pierson M. *Initiation aux techniques de l'Histologie Animale*. Masson, Paris; 1967.
- [18] Gabe M. *Techniques histologiques*. Masson, Paris; 1968.
- [19] Exbrayat JM. Méthodes classiques de visualisation du génome en microscopie photonique. TEC et DOC, Paris; 2000.
- [20] Boubekri A, Gernigon T, Khammar F, Exbrayat JM. Approche immunohistochimique de l'ovaire du rat des sables du sud ouest algérien, en période de reproduction. *Rev Fr Histotechn*. 2004;17:21-29.
- [21] Hage AJ, Groen-Klevant AC, Welschen R. Follicle growth in the immature rat ovary. *Acta Endocrinol*. 1978;88: 375-382.
- [22] Gosden RG, Telfer E, Faddy MJ, Brook DJ. Ovarian cyclicity and follicular recruitment in unilaterally ovariectomized mice. *J Reprod Fert*. 1989;87:257-264.
- [23] Gougeon A. Initiation of ovarian follicular growth: few facts and many hypothesis. In: Filicori M, Flamigni C, eds. *The ovary: regulation, dysfunction and treatment*. Amsterdam: Elsevier Sciences; 1996: 3-12.
- [24] Mhawi AJ, Kauka J, Moolik J. Follicle and oocyte growth in early post-natal calves: cytochemical, autoradiographical and electron microscopical studies. *Reprod Nutr Dev*. 1991;31:115-126.
- [25] Norris ML, Adams CE. Sexual development in the Mongolian gerbil, *Meriones unguiculatus*, with particular reference to the ovary. *J Reprod Fert*. 1974;36:245-248.
- [26] Channing CP, Hillensjo T, Schaerf FW. Hormonal control of oocyte meiosis, ovulation and luteinization in mammals. *Clin Endocrinol Metab*. 1978;7:601-24.

- [27] Gougeon A, Chainy GBN. Morphometric studies of small follicles in ovaries of women at different ages. *J Reprod Fert.* 1987;81:433-442.
- [28] Meredith S, Dudenhoefter G, Jackson K. Classification of small type B/C follicles as primordial follicles in mature rats. *J. Repr. Fert.* 2000;119:43-48
- [29] Allen E. The estrous cycle in the mouse. *Am J Anat.* 1922;30:297-371.
- [30] Pederson T, Petters H. Proposal for a classification of oocytes and follicles in the mouse ovary. *J Reprod Fer.* 1968;17: 555-557.
- [31] Singh S, Gouraya SS. Follicular growth pattern in the House Rat (*Rattus rattus*). *Eur J Morphol.* 1993;31:257-267.
- [32] Norman RL Greenwald GS. Follicular histology and physiological correlates in the preovulatory hamster. *Anat Rec.* 1971;95:95-108.
- [33] Roy SK, Greenwald GS. Effects of FSH and LH in incorporation of [3H] Thymidine into follicular DNA. *J Reprod Fert.* 1986;78: 201-209.
- [34] Norris ML Adams CE. Sexual development in the Mongolian gerbil, *Meriones unguiculatus*, with particular reference to the ovary. *J Reprod. Fert.* 1974;36:245-248.
- [35] Rosenfeld CS, Wagner JS, Roberts RM, Lubahn. DB. Intraovarian actions of oestrogen. *Reproduction.* 2001;122:215-226.