

Angiogenesis in gliomas

Agnieszka Lebelt¹, Janusz Dzieciol¹, Katarzyna Guzińska-Ustymowicz²,
Dorota Lemancewicz¹, Lech Zimnoch³, Elżbieta Czykier⁴

¹Department of Human Anatomy, ²Department of General Pathomorphology, ³Department of Medical Pathomorphology, ⁴Department of Histology, Medical University of Białystok, Poland

Abstract: Brain gliomas are characterized by invasive growth and neovascularisation potential. Angiogenesis plays a major role in the progression of gliomas and its determination has a great prognostic value. The aim of the study was to assess the vascularisation of chosen brain gliomas and to estimate how it is correlated with tumour histological type, malignancy grade, location and size, and with age and sex of patients. Tumour vascularisation analysis was based on the determination of microvascular proliferation (MVP) and microvessel density (MVD). Microvascular proliferation was measured with immunohistochemical methods using mouse monoclonal antibodies to detect cell proliferation antigens. The following antibodies were used Ki-67 and PCNA (DAKO). Identification of vessels was performed by CD31 antibody and anti-human von Willebrand factor (DAKO). The highest microvascular proliferation and microvascular density were observed in multiform glioblastomas and the lowest in oligodendrogliomas. Significant correlation was observed between the vascularisation and malignancy grade.

Key words: Angiogenesis - Glioma - Ki-67 - PCNA - Microvascular proliferation - Microvessel density

Introduction

Neoplasms arising from glial cells, called gliomas, are the most common brain tumours, accounting for over 50% of all brain neoplasms [1]. Although their biology has been known, these tumours still have exceptionally unfavourable prognosis.

In 1971, J. Folkman hypothesized that the growth of solid tumours is angiogenesis-dependent and that therapeutic actions undertaken to inhibit this process are a likely antineoplastic therapy [1-5]. This also refers to brain gliomas.

Brain gliomas are characterized by invasive growth and neovascularisation potential. Angiogenesis is a basic mechanism allowing tumour growth [4,6]. Increased neoplastic proliferation of glial cells runs parallel to endothelial vascular proliferation, which apart from cell atypia and necrosis, is one of the malignancy evaluation criteria. Depending on tumour's histological type and malignancy grade, angiogenesis exhibits varied intensity [7,8]. Highly malignant tumours show markedly pronounced proliferation of

vascular endothelial cells, increasing tumour vasculature [9]. In the microscopic picture, proliferating vessels assume the forms from fine capillaries to well-developed glomerular structures [10].

Tumour vessels form two populations. One consists of physiologically existing intratumoral vessels, the other includes capillaries formed via angiogenesis in response to angiogenic factors [11].

In recent years, it has been demonstrated that angiogenesis has a great role in glioma progression and its determination is one of the major prognostic factors [12-15].

The aim of the study was to assess vascularisation of chosen brain gliomas and to find correlations between vascularisation and histological type of the neoplasms, its malignancy grade, location, size and age and gender of patients. The angiogenic potential in gliomas was analysed according to the morphology of microvascular proliferation and by assessment of the vascular density.

Materials and methods

Patients. Ninety-nine patients (54 women and 45 men) aged 18-80 years with clinically diagnosed brain tumour were included in the study. Based on histopathological investigations performed to determine tumour's histological type and malignancy grade, the patients were divided into study groups according to the WHO

Correspondence: A. Lebelt, Dept. of Human Anatomy, Medical University of Białystok, Mickiewicza Str. 2a, 15-230 Białystok, Poland; tel.: (+4885) 7485661, e-mail: anatomia@amb.edu.pl

Table 1. Microvascular proliferation, microvessel density, diameter et location of tumors in the respective study groups.

Group	Histological type grading	G	Number of cases	Ki-67 PI of MVP		PCNA PI of MVP		MVD		Diameter (cm)	Location of tumors (%)				
				\bar{X}	SD	\bar{X}	SD	\bar{X}	SD		Frontal lobe	Temporal lobe	Parietal lobe	Motor and sensory area	Area of posterior contact
				I	Astrocytoma	G2	22	7.58	4.51		11.26	5.78	7.86	2.34	4.96
II	Anaplastic astrocytoma	G3	31	12.75	2.56	15.81	3.44	18.00	3.41	5.27	32.3	25.8	12.9	12.9	16.1
III	Glioblastoma multiforme	G4	23	22.93	6.11	29.33	8.02	31.50	12.28	3.75	13	43.5	17.4	8.7	17.4
IV	Oligodendroglioma	G2	12	1.11	0.29	1.53	0.27	6.75	2.66	3.63	50	25	0	25	0
V	Anaplastic oligodendroglioma	G3	11	12.42	3.02	16.82	5.45	12.00	3.24	4.69	45.5	27.3	18.2	9.1	0

PI - proliferation index, MVP - microvascular proliferation, MVD - microvessel density, \bar{x} - mean, SD - standard deviation.

classification [16]. Group I consisted of patients with astrocytoma (22 patients, mean age 43.18), group II - patients with anaplastic astrocytoma (31 patients, mean age 55.84), group III - patients with multiform glioblastoma (23 patients, mean age 62.04), group IV - patients with oligodendroglioma (12 patients, mean age 44.5) and group V had patients with anaplastic oligodendroglioma (11 patients, mean age 54.64) (Table 1).

Imaging diagnostics. CT and/or MRI were performed in all the patients prior to surgery to determine tumour size and location (left/right hemisphere, frontal lobe, parietal lobe, temporal lobe, sensory-locomotor region and posterior contact region) (Table 1).

Histopathological examination. In each patient, intraoperative examination was performed to obtain preliminary diagnosis and to establish the extent of surgical procedure. Material for intraoperative analysis was routinely embedded in gel (Tissue Freezing Medium Jung) at a temperature of approximately minus 24°C, and stained with haematoxylin and eosin (HE).

After the preliminary diagnosis had been made, two specimens, approx. 10 mm × 10 mm × 1 mm, were obtained from the tumour tissue (when the amount of the material was too small, it was stored for further analysis) and fixed for 24 h in 10% buffered formalin solution at room temperature. After dehydration in alcohol series and xylene, the specimens were embedded in paraffin of temperature 55°C.

Material storage procedure allowed preservation of antigen structures and appropriate performance of immunohistochemical investigations.

Paraffin sections, 5 µm thick, were cut from paraffin blocks on a sledge microtome and placed on sialinized glass slides. In each case, HE staining was performed. Using the microscopic picture, final diagnosis was made of histological type and malignancy grade.

Immunohistochemical investigations, angiogenesis. Tumour vascularisation analysis was based on the determination of microvascular proliferation (MVP) and microvessel density (MVD).

Microvascular proliferation was measured with immunohistochemical methods using mouse monoclonal antibodies to detect cell proliferation antigens. The following antibodies were used: Ki-

67 (clone MIB-1, dilution 1:50, catalogue no M7240, DAKO) and PCNA (clone PC 10, dilution 1:100, catalogue no. M0879, DAKO). The specimens were prepared for immunohistochemical analysis with the methods recommended by the producer (DAKO).

For vessel visualization, the following antibodies were used against endothelial cell antigens: CD31 antibody (clone JC/70A, dilution 1:20, catalogue no M 0823, DAKO) and anti-von Willebrand factor (clone F8/86, dilution 1:25, catalogue no M 0616, DAKO). Assimakopoulou and Korkolopoulou used the same antibodies for vessel identification [13,17]. Microvascular proliferation was defined by determining the proliferation index (PI of MVP), which expressed the percentage of cells with positive nuclear reaction for Ki-67 and PCNA in comparison to the total number of endothelial cells examined. The antigen-antibody reaction intensity was assessed in the scale: /-/- lack of reaction, /+/- weak reaction - slightly brown colour of the nuclei, /++/- medium reaction - brown-dark brown colour of the nuclei, /+++/- intensive reaction - strongly brown colour of the nuclei. The proliferation index in each case was the average score of the proliferation indices of four microscopic fields at magnification of 400×. Vessel density was estimated as the number of vessels per 1 mm².

Morphometric programme Microlmage InCD UDF Packed Writing Software for Windows (Olympus) was used for the assessment of angiogenesis.

Statistical analysis. Statistica PL programme with Stat Soft test was used for statistical analysis of the results. For comparison of means, t-student's test was performed.

Ethical issues. The study was approved by the Bioethical Committee of the Medical University of Bialystok (R-I-003/182/2006).

Results

The highest proliferative activity of endothelial cells was found in multiform glioblastoma (Fig. 1). The average value of Ki-67 PI of MVP was 22.93 while PCNA PI of MVP - 29.33. The lowest mean values of PI of MVP of endothelial cells were observed in the

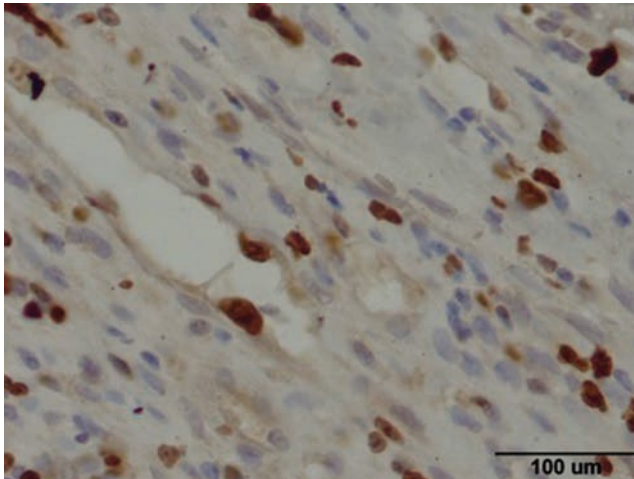


Fig. 1. Multiform glioblastoma. Endothelial cells with immunohistochemical reaction of Ki-67 (magnification $\times 400$).

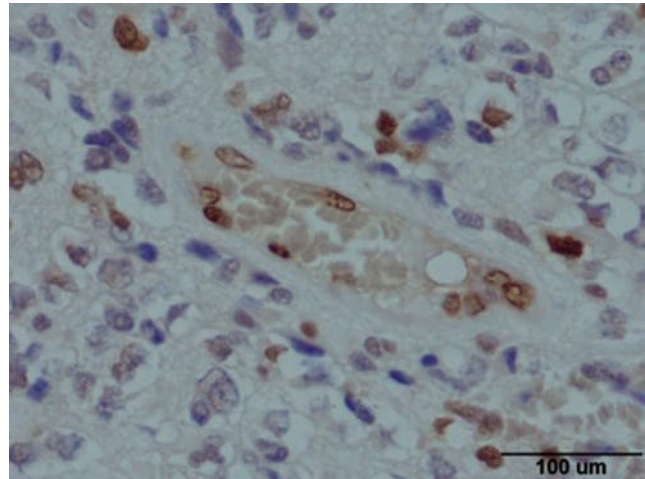


Fig. 2. Oligodendroglioma. Endothelial cells with immunohistochemical reaction of PCNA (magnification $\times 400$).

texture of oligodendrogliomas (Ki-67 PI of MVP-1.11, PCNA PI of MVP-1.53, Fig. 2).

All types of tumours exhibited simple vascular proliferation type. Enhanced glomerular proliferation type was found only in patients with multiform glioblastoma (group III, in 65.2% patients), assuming the form of single structures in 30.43% patients, numerous vascular groups in 26.08% and conglomerates in 8.69% patients. The highest vessel density was noted in elderly patients over 65 years of age. Only in these patients, glomerular conglomerates and numerous vascular groups were found.

The highest microvascular density (MVD) was revealed in multiform glioblastoma (mean 31.5 vessels/mm²), the lowest in oligodendroglioma (6.75 vessels/mm²).

In our study, anaplastic astrocytomas had the largest diameter (mean 5.27 ± 1.5 cm). Slightly smaller were astrocytomas (mean 4.96 ± 0.98 cm) and anaplastic oligodendrogliomas (mean 3.63 ± 1.07 cm).

In astrocytoma patients, the most frequent tumour location was the temporal lobe (40.9%), the least - the parietal lobe (9.1%). The most common site of anaplastic astrocytoma was the frontal lobe (32.3%) and the temporal lobe (25.8%).

Multiform glioblastoma was most frequently found in the temporal lobe (43.5%), least frequently in the sensory-locomotor region (8.7%).

The most common site of oligodendrogliomas, like in the case of anaplastic astrocytomas, was the frontal lobe (50%). Detailed data have been presented in Table 1.

Discussion

The values PI of MVP were varied and determined by tumour malignancy grade. The highest PI of MVP was found in multiform glioblastoma (mean 29.33 PCNA

PI of MVP and 22.93 Ki-67 PI of MVP). In the study conducted by Kern the values were lower (mean 9.4 for Ki-67) [8]. The values of PI of MVP were the lowest in oligodendrogliomas and did not differ much in the respective fields of the same tumour. The proliferative activity of endothelial cells was considerably intensified in anaplastic oligodendrogliomas, and in these neoplasms PI values differed more often between the respective fields.

In astrocytoma patients, PI of MVP values were lower compared to those noted in patients with anaplastic astrocytoma. Our results indicate that gliomas of higher malignancy grade show more intensified proliferation activity of vascular endothelial cells. This activity is also more varied in the respective fields of the same tumour.

The highest microvascular density (MVD) indicating tumour vascularisation was observed in multiform glioblastoma (from 16 to 52; ± 31.5), the lowest in oligodendroglioma (from 3 to 11; ± 6.75). Assimakopoulou described similar relations in vascularisation in the respective histological types of brain tumours [17]. However, compared to the data reported by Izycka, the scores for multiform glioblastoma are lower [18]. Vascular density in multiform glioblastoma is markedly higher than in tumours of lower histological grade [1]. Gupta also found a statistically significant correlation between vascular proliferation and tumour malignancy grade [19].

Angiogenesis has been known as a factor determining tumour growth rate and a potential relapse. Studies on gliomas have revealed an inverse correlation between vascular density and survival time. An increase in vascularisation significantly worsens prognosis. Thus, measurement of vascular density in tumour tissue can be an accessory prognostic factor in patients with brain tumours [8,9,12,14,17]. This has

been reported, among others, by Leon and Kern, although they found no significant differences in vascularisation between primary and recurrent multiform glioblastoma [8,14].

In our study, most blood vessels were situated in the tumour peripheral part. These observations are consistent with the data published by Wojtukiewicz [15]. Endothelial cells of the vessels lying on tumour periphery showed stronger reactions to CD31 antibodies and anti-factor VIII antibody.

The present analysis revealed a positive correlation between tumour diameter and proliferative activity of endothelial cells in the group of patients with astrocytoma and multiform glioblastoma, but not in the other groups.

In patients with brain gliomas, tumour location is of greater clinical value than its size. No significant difference was found in location depending on the hemisphere in any of the groups. No correlation was found between glioma location and MVP or MVD. In the current study, the incidence of brain tumour was higher in women. Only in the anaplastic astrocytoma group, men prevailed. No differences in age were observed between women and men.

In most cases, there was no correlation between age and tumour vascularisation. Only in patients with multiform glioblastoma over 65 years, vessel density was higher. Iżycka described a negative correlation between tumour vascularisation and patients' age. Patients' age has been also found to influence the rate of relapses of brain tumours [18].

References

- [1] Wesseling P, Ruiter D, Burger. Angiogenesis in brain tumors; pathobiological and clinical aspects. *Journal of Neuro-Oncology*. 1997;32:253-265.
- [2] Folkman J. Tumor angiogenesis: therapeutic implications. *N Engl J Med*. 1971;285:1182-1186.
- [3] Folkman J. What is the evidence that tumors are angiogenesis dependent? *J Nat Cancer Inst*. 1990;82:4-6.
- [4] Puduvalli VK. Inhibition of angiogenesis as a therapeutic strategy against brain tumors. *Cancer Treat Res*. 2004;117:307-336.
- [5] Purow B, Fine HA. Progress report on the potential of angiogenesis inhibitors for neurooncology. *Cancer Invest*. 2004;22(4):577-587.
- [6] Carrol RS, Zhang, Melnick MB et al. KDR activation in astrocytic neoplasms. *Cancer*. 1999;86:1335-1341.
- [7] Birner P, Piribauer M, Fischer I et al. Vascular patterns in glioblastoma influence clinical outcome and variable expression of angiogenic proteins: evidence for distinct angiogenic subtypes. *Brain Pathol*. 2003;13(2):133-143.
- [8] Kern MA, Feisel KD, Friese M et al. Proliferative activity of microvascular cells in glioblastomas does not correlate with time to recurrence. *Neurooncol*. 2003;63(1):9-13.
- [9] Lopes MB. Angiogenesis in brain tumors. *Microsc Res Tech*. 2003;60(2):225-230.
- [10] Liberski P. Neuroepithelial neoplasms. Multiform glioblastoma. In: Mossakowski MJ, ed. *Tumors of the nervous system*. Ossolinum, Wrocław; 1997:72-88.
- [11] Thompson WD, Shiach KJ, Fraser RA et al. Tumors acquire their vasculature by vessel incorporation, not vessel ingrowth. *J Pathol*. 1987;151:323-332.
- [12] Grotzer MA, Wiewrodt R, Janss AJ et al. High microvessel density in primitive neuroectodermal brain tumors of childhood. *Neuropediatrics*. 2001;32(2):75-79.
- [13] Korkolopoulou P, Patsouris E, Kavantzias N et al. Prognostic implications of microvessel mophometry in diffuse astrocytic neoplasms. *Neuropathol Appl Neurobiol*. 2002;28(1):57-66.
- [14] Leon SP, Folkerth RD, Black PM. Microvessel density is a prognostic indicator for patients with astroglial brain tumors. *Cancer*. 1996;77:362-372.
- [15] Wojtukiewicz M, Matuszewska EA, Zimnoch L. Angiogenesis in brain tumors-biological and clinical aspects. *Post Hig Med Dośw*. 1998;52(6):577-590.
- [16] Kleihues P, Louis DN, Scheithauer BW. The WHO classification of tumors of the nervous system. *J Neuropathol Exp Neurol*. 2002;61:215-225.
- [17] Assimakopoulou M, Sotiropoulou-Bonikou G, Maraziotis T. Microvessel density in brain tumors. *Anticancer Res*. 1997;17:4747-4753.
- [18] Iżycka E, Rzepko R, Borowska-Lehman J et al. Angiogenesis in glioblastoma-analysis of intensity and relations to chosen clinical data. *Folia Neuropathol*. 2003;41(1):15-21.
- [19] Gupta K, Radotra BD, Banerjee AK, Nijhawan R. Quantitation of angiogenesis and its correlation with vascular endothelial growth factor expression in astrocytic tumors. *Anal Quant Cytol Histol*. 2004;26(4):223-229.

Submitted: 23 February, 2007

Accepted after reviews: 24 September, 2007