

ASD AND PDA
CLOSUREASD and PDA closure with
Cera™ and CeraFlex™ devices

D.G. Buys, C. Greig and S.C. Brown

Department of Paediatric Cardiology, University of the Free State,
South Africa

Address for correspondence:

Daniel Buys
Paediatric Cardiology
1st Floor Universitas Hospital
Logeman Street
Bloemfontein
9301
South Africa

Email:

buysdg@ufs.ac.za

INTRODUCTION

Patent ductus arteriosus (PDA) and atrial septal defects (ASD) are two of the most common congenital cardiac lesions occurring in 0.5/1 000 and 0.67 - 2.1/1 000 of live births respectively, with a higher incidence of PDAs in premature babies.^(1,2) Historically the only treatment available for these lesions was surgery. The first percutaneous closure of a PDA by Porstman, et al.⁽²⁾ in 1967 and ASD closure by King and Mills in 1976,⁽³⁾ led to the development of various new techniques and devices over the past four decades.⁽⁴⁻⁶⁾ The advantages of percutaneous closure of these lesions are well described and are now the standard of care.

The CeraFlex™ devices come loaded, are attached by a nitinol wire (Figure 1a) and need to be flushed before implantation. The devices are self-expandable and retrievable. Advanced technology is used to cover the nitinol surfaces of the device with Titanium Nitride (TiN). This reportedly prevents Nickel leaching and ensures accelerated endothelialisation for rapid defect closure. The softer material provides for a compliant and flexible implant. Polytetrafluoroethylene (PTFE) is sewn into the PDA devices to decrease residual shunting. The ASD and patent foramen ovale (PFO) devices contain a polyethylene terephthalate (PET) membrane to ensure lower delivery sheath profiles and to promote defect closure. The device and delivery sheath sizes are comparable to other commercially available devices. Both the Cera™ and CeraFlex™ devices have CE approval.

ABSTRACT

Introduction and aim: Percutaneous closure of congenital cardiac defects is common practice. The aim of the study was to describe our experience in closing PDAs, PFOs and an ASD using the new Cera™ and CeraFlex™ devices.

Methods: Twenty patients were included in this retrospective review. All patients underwent device closure with the Cera™ and CeraFlex™ devices.

Results: All attempts at device closure were successful (n=20). Indications included PDA (n=16), ASD (n=1) and PFO (n=3). Median age at procedure was: PDA 1y 10mo (4mo - 10y 4mo), ASD 27y and PFO 50y 9mo (38y - 70y). Median weight at procedure was: PDA 10.5kg (4.9kg - 70kg), ASD 56kg and PFO 82.5kg (80kg - 113kg). Peri-procedural complications consisted of embolisation of 2 PDA devices, which could be repositioned.

Conclusion: The Cera™ and CeraFlex™ devices are effective for closure of PDAs, ASDs and PFOs.

SAHeart 2016;13:6-10

We discuss our experience using the new Cera™ and CeraFlex™ (Lifetech, Nashan, Shenzhen, China) devices in closing PDAs, an ASD and PFOs.

PATIENTS

This is a retrospective review of lesions closed using the Cera™ and CeraFlex™ devices.

Routine indications for defect closure were followed. An electrocardiogram (ECG) and echocardiogram were performed on all patients prior to the procedure. Pre-procedural echocardiogram concentrated on defect size, associated lesions and haemodynamic importance. Informed consent was obtained and active infection ruled out. All PDAs were haemodynamically important and no "silent" PDAs were closed. Procedures were performed under deep conscious sedation or general anaesthesia. Standard prophylactic antibiotic protocols were used (Cephalosporin 50mg/kg at start of procedure and 8 hrly IVI for 3 doses). Heparin (50UI/kg/IVI) was administered after cannulating the vessels, with added doses at 30min intervals if necessary. Haemodynamic data were collected and included a full set of venous and arterial oxygen saturations, pulmonary and systemic pressures for shunt and resistance calculations.

TECHNICAL ASPECTS

Standard procedural techniques were used to close these defects. Device sizes and delivery sheath dimensions are similar to other available devices. Device selection was done using the smallest measured diameter plus 2mm in the case of PDA closure and no more than 1 - 2mm larger than the ASD diameter using the stop flow balloon sizing method for ASD closure. The AcuMark™ (Lifetech Scientific, Nanshan District, Shenzhen, China) sizing balloon is available in 18mm and 28mm diameters. The balloons have 4 radiopaque bands at 10mm, 5mm and 2mm intervals and can be used as a distance reference. These markers are located proximal to the 40mm balloon. This is a soft compliant balloon that uses a 0.035 inch. guide wire. The PDA device shape is reminiscent of the ADO I (St Jude Medical, Cardiovascular Division, St Paul, MN) device design

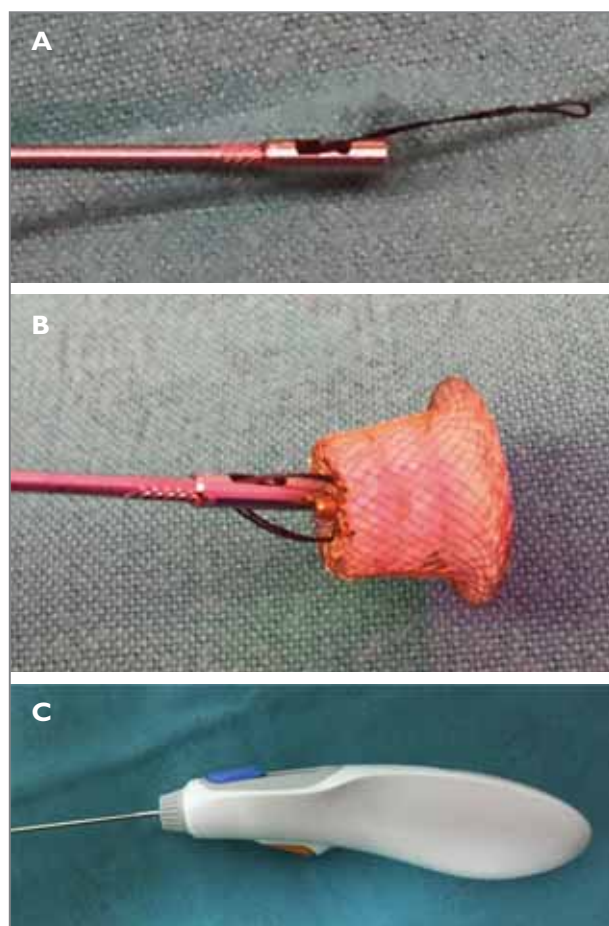


FIGURE 1: The delivery mechanism and nitinol loop that attaches the device to the delivery cable are illustrated.

A: Nitinol loop at end of delivery cable.

B: PDA device attached to the delivery cable before loading.

C: The delivery mechanism. The orange button must be triggered before the blue button can be moved backwards thereby releasing the device.

with a retention skirt and a stent portion (Figure 1b). The release mechanism consists of a safety button that needs to be triggered and then the release button can be moved backwards. This results in the release of the nitinol wire (Figure 1c). The Cera™ device implantation system consists of a detachable cable which screws into the device. This device is not pre-loaded and is released by turning the delivery cable anti-clockwise.

RESULTS

Twenty devices were implanted: PDA (n=16), ASD (n=1) and PFO (n=3). Clinical and implantation data can be viewed in Table 1. In the PDA group the median age was 1y 10mo (4mo - 10y 4mo) and median weight was 10.5kg (4.9kg - 70kg). Male to female ratio was 1:3 (4 males, 12 females). No significant gradients were observed in the left pulmonary artery and aorta post implantation. Complete closure was obtained in all patients.

The patient with an ASD was a 27-year-old female weighing 56kg. The median age and weight for PFO closure was 50y 9mo (38y - 70y) and 82.5kg (80kg - 113kg) respectively. Peri-procedural trans-esophageal echocardiogram confirmed no interference or obstruction of intra-cardiac structures.

Complications

No major complications were observed. Two PDA devices embolised to the aorta, one immediately after release and the other after 12 hours. These devices could be snared and repositioned with no further complications (see discussion). All patients were discharged within 24 hours, except the 2 patients with device embolisations.

Follow-up

Follow-up periods ranged from 1mo - 25mo. (mean 13.0 ± 7.6mo). All patients were asymptomatic with complete defect closure. There was no aortic or pulmonary artery obstruction that was noted on follow-up in the PDA group. In the ASD/PFO group, the ECGs were normal, the devices were in a good position and there was no valvular regurgitation or pericardial effusion.

DISCUSSION

Percutaneous closure of PDAs, ASDs and PFOs is a well-established technique that has a low complication rate. Our experience shows that the Cera™ and CeraFlex™ devices are effective in closing PDAs, ASDs and PFOs. Delivery sheath sizes are small and similar to other available devices. The release

TABLE 1: Clinical data

Number	Age	M/F	Diagnosis	Weight (kg)	Device/size		Sheath
					Cera	CeraFlex	
1	2y 10mo	M	PDA	12.5		6*8mm	7F
2	4mo	F	PDA	4.9		4*6mm	6F
3	10y 4mo	F	PDA	70		8*10mm	7F
4	11mo	M	PDA	6.4		4*6mm	6F
5	1y 9mo	F	PDA	10.5	8*10mm		7F
6	1y 2mo	F	PDA	10.5		4*6mm	6F
7	4y 1mo	F	PDA	19.3	6*8mm		7F
8	8y	F	PDA	16		6*8mm	7F
9	11mo	F	PDA	6		8*10mm	7F
10	3y	M	PDA	13.5		4*6mm	6F
11	3y 7mo	F	PDA	14	4*6mm		6F
12	2y 10mo	M	PDA	14	6*8mm		7F
13	1y 11mo	F	PDA	13		4*6mm	6F
14	11mo	F	PDA	6.1		4*6mm	6F
15	10y	F	PDA	20		8*10mm	7F
16	9mo	F	PDA	7.2		4*6mm	6F
17	27y	M	ASD	56		28mm	12F
18	70y	F	PFO	113		25mm	10F
19	38y	M	PFO	85		18mm	9F
20	63y	F	PFO	80		18mm	9F

mechanism is easy to use and effective. The PDA device cost is comparable to other available devices whilst the ASD and PFO devices are considerably less in our setting. An advantage of the CeraFlex™ device is that the device is in its final position before release due to the nitinol wire mechanism (Figure 3). ASD and PFO closure was successful in the selected patients. The devices could be recaptured if the position was unacceptable before release. Care was taken to confirm distance from AV valves, SVC, IVC and no impingement of the aorta before release. If a deficient aortic rim was of concern, the device was slightly oversized to prevent aortic impingement.

Our experience of the 2 PDA devices that embolised merits further discussion. Both of these patients were small (4.8kg and 6kg) and were closed using the smaller device (0406). In one patient the device embolised immediately and in the smaller infant the embolisation was noted 12 hours post implantation. The mechanism of embolisation may be due to a number of factors. Incorrect device selection may play a role. We do, however, take care not to cross the PDA before initial angiogram to ensure accurate measurements. We also use the

right anterior oblique (RAO) 30° view to measure the PDA in more than one plane. We then select a device as recommended by the manufacturer. If concern exists about sizing, we advance the delivery sheath through the PDA and repeat the aortogram for final measurements and sizing. In both cases the smaller device was used. One possible explanation is that the smaller device may take longer to conform to its original expanded size at body temperature. The authors speculate that the most likely cause may be that the nitinol wire loop becomes wedged in the mesh of the device at the anchor point. The delivery cable acts as a slingshot when one tries to withdraw the wire during release (Figure 2). Tension remains on the system with pulling in the direction of the pulmonary artery. As a result, the device jumps in the direction of the aorta on final release (slingshot mechanism) and may dislodge. This may be more likely to occur in smaller devices.

Following these 2 incidents, we now protect the aorta by placing a pigtail catheter in the ductal ampulla before final release. We also pull the sheath back into the IVC to reduce the tension on the delivery cable and wait for 5 - 10min before

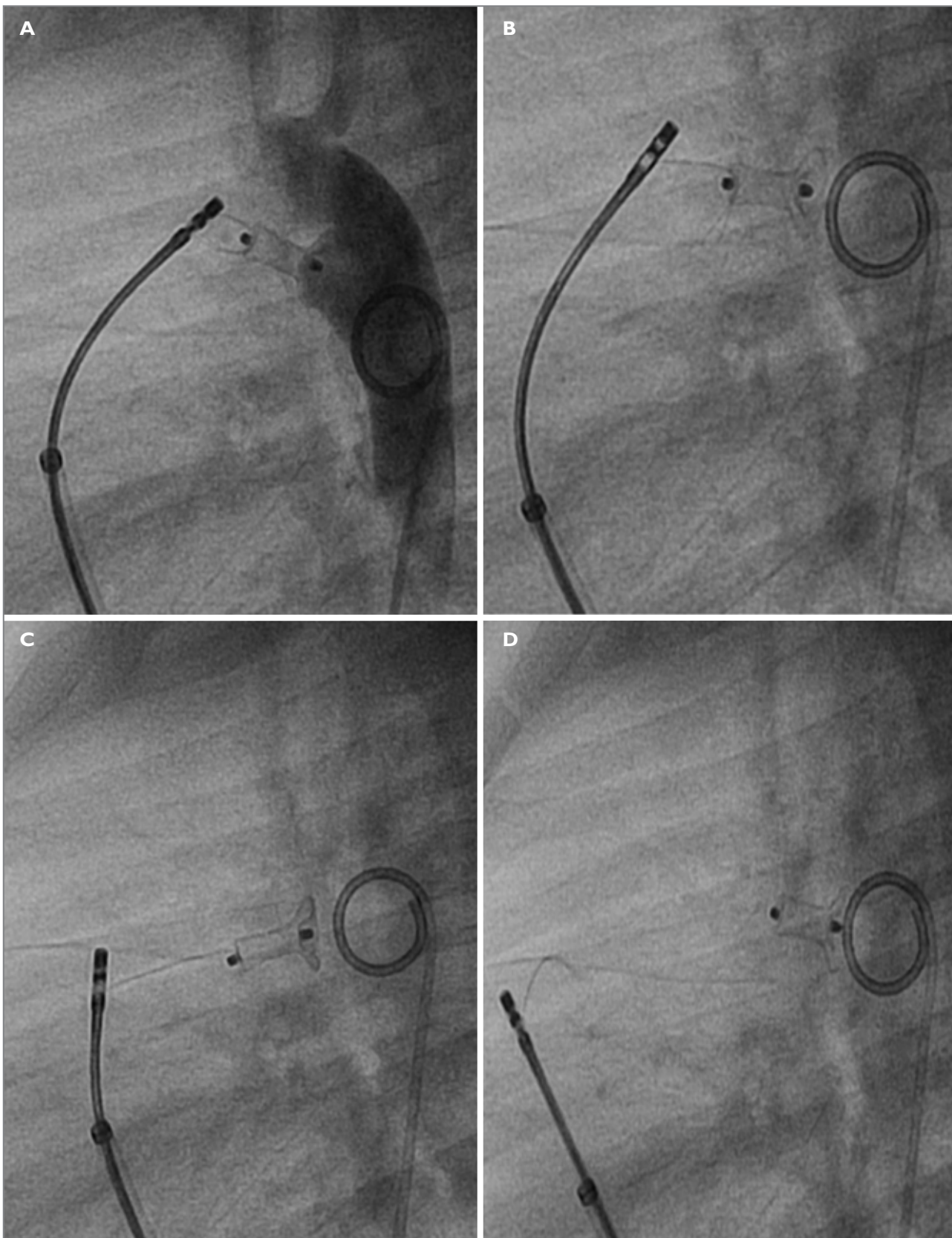


FIGURE 2: The slingshot mechanism is illustrated.

A: Tension on the device is noted with the nitinol wire still attached.

B & C: Traction on the device towards the pulmonary artery is demonstrated.

D: The device then jumps in the direction of the aorta. Note the pigtail catheter in the ductal ampulla.

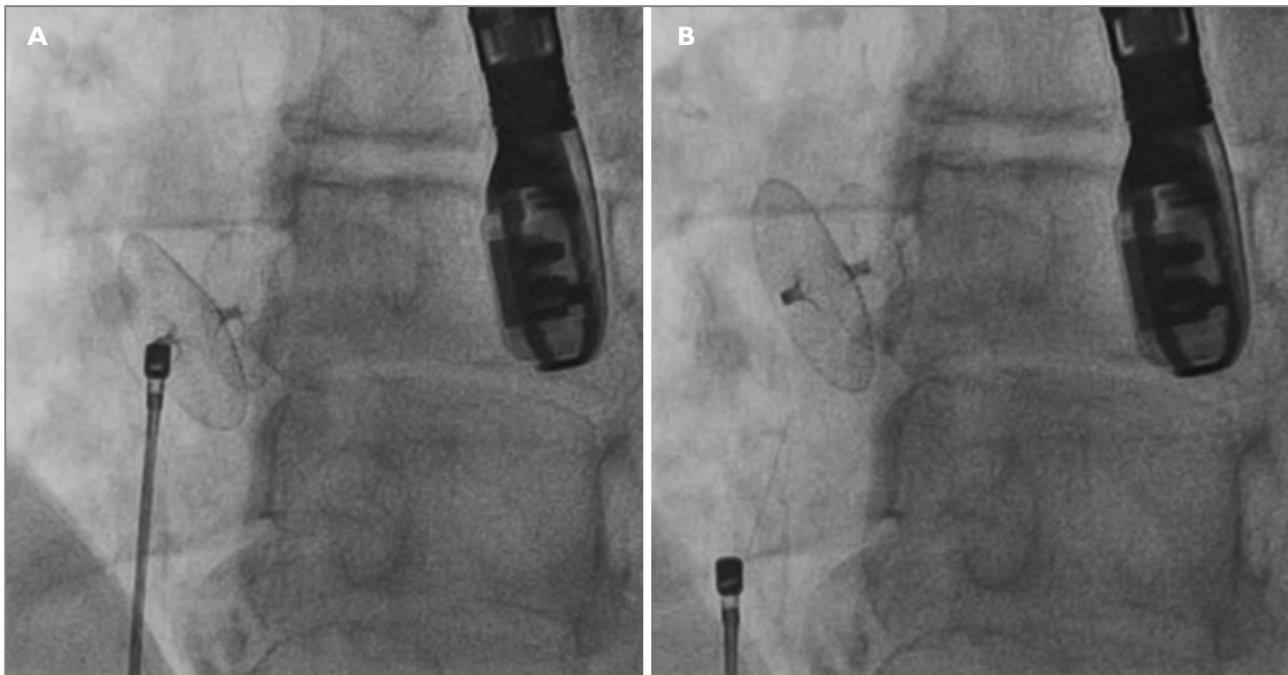


FIGURE 3: Illustrates the PFO device.

A & B: Illustrates the PFO device in its final position after deployment, before nitinol wire release.

final release. In both of these patients it was possible to snare the device in an antegrade fashion and reposition the same device with complete occlusion of the defect and no further complications.

Limitations

This is a retrospective review with a small number of patients and relatively short follow-up.

CONCLUSION

The Cera™ and CeraFlex™ devices are an effective alternative to commercially available devices. Certain precautionary measures are advised in small children where smaller devices are used.

Conflict of interest: none declared.

REFERENCES

1. Carr M. Paediatric atrial septal defects (online). Retrieved Nov 2, 2015: <http://emedicine.medscape.com/article/889394-overview>.
2. Baruteau A-E, Hascoet S, Baruteau J, et al. Transcatheter closure of patent ductus arteriosus: Past, present and future. *Arch of cardiovascular disease* 2014;107:122-132.
3. Astarcioglu MA, Kalcik M, Sen T, et al. Ceraflex versus Amplatzer occlude for secundum atrial septal defect closure Multicenter clinical experience. *Herz* 2015;40(2):146-150.
4. Suhaib K, Damien K, Qi-ling C, et al. Transcatheter closure of secundum atrial septal defects. *J Invasive Cardiol* 2013;25(5):257-264.
5. Dehghani H, Boyle AJ. Percutaneous device closure of secundum atrial septal defects in older adults. *Am J Cardiovasc Dis* 2012;2(2):133-142.
6. Tharakanatha R, Yarrabolu P, Syamasundar R. Transcatheter closure of patent ductus arteriosus. *Pediat Therapeut* 2012;85:1-8.