

## PERICARDIAL EFFUSION WITH CYSTIC MASS

# Image in cardiology

**A. Coetzee, C.G. Kyriakakis, P.G. Herbst and A.F. Doubell**

Division of Cardiology, Department of Medicine, Tygerberg Academic Hospital, University of Stellenbosch

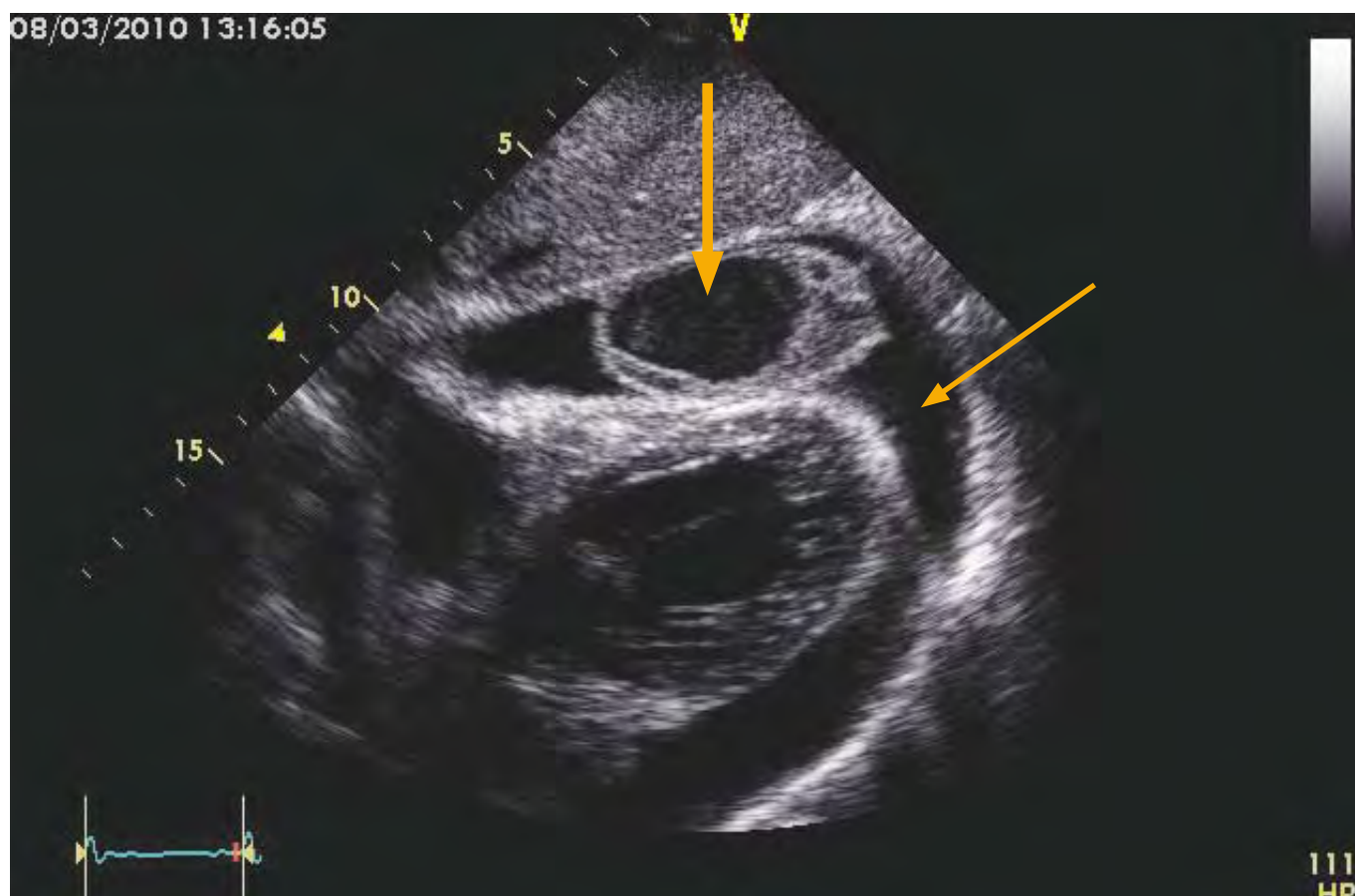
**Address for correspondence:**

Dr Ankia Coetzee  
Department of Medicine  
PO Box 19063  
Tygerberg  
7505  
South Africa

**Email:**

[afd@sun.ac.za](mailto:afd@sun.ac.za)

A 45-year-old man presented to medicine with a 2-month history of exertional dyspnoea and a non-productive cough. He was referred for echocardiographic evaluation after his chest radiograph (CXR) demonstrated a large globular cardiac shadow and left-sided pleural effusion. He works as a rural sheep farmer in the Eastern Cape region and was newly diagnosed with HIV from which he had no apparent clinical sequelae apart from a recent history of unquantified weight loss. Two months prior to this presentation he sustained a left parasternal stab wound chest from which he made a good recovery. His clinical examination revealed a raised jugular venous pressure (JVP), small left-sided pleural effusion and a 5cm scar at the left 3rd sternocostal junction from the stabbed chest.



**FIGURE 1:** This is a subcostal echocardiography image demonstrating a circumferential pericardial effusion (arrow) with an "egg-shaped" cyst-like mass (arrow: bold) seen adjacent to the liver. The epicardium is relatively smooth without large pericardial strands visualised.

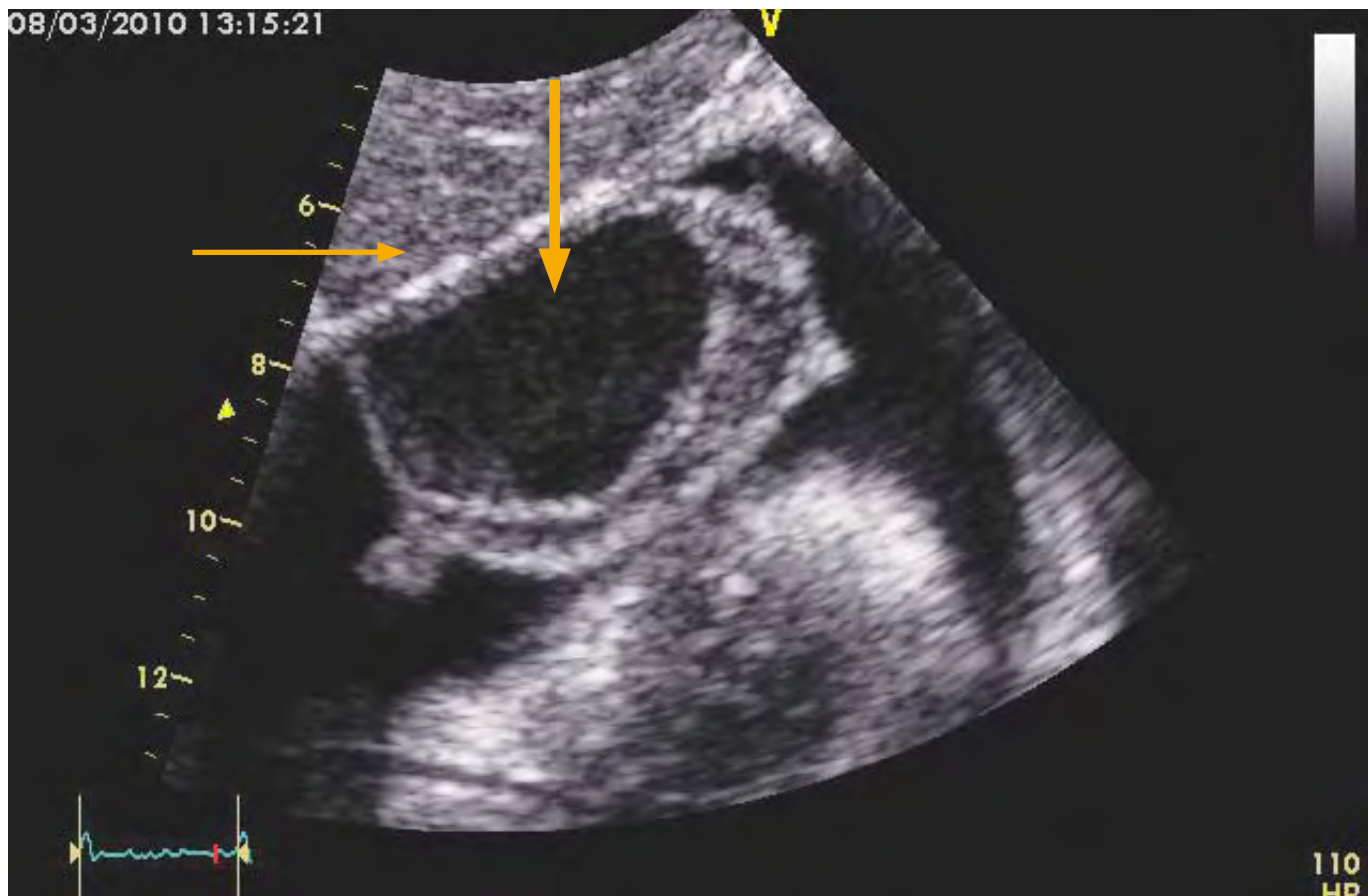
Echocardiography demonstrated a moderate to large circumferential pericardial effusion with early signs of cardiac tamponade and a cystic mass adjacent to the right ventricle. Interestingly there were no signs of organisation of the effusion and no pericardial strands were apparent.

At this stage we considered a differential diagnosis to explain the effusion and cystic mass. This included a TB pericardial effusion with an area of loculation, pericardial hydatid disease and pericardial effusion with organised haematoma related to the stab wound.

Pericardioscopy was performed next which showed a red, inflamed pericardium. No exudates were seen. The cyst appeared light yellow in colour with a smooth wall and was overlying the anterior part of the right ventricle. Pericardiocentesis drained 760ml of blood stained fluid. No pericardioscopy directed biopsy was attempted of the mass for fear of spreading daughter cysts throughout the pericardium should the diagnosis be hydatid disease. Pericardial

fluid and biopsies were sent for microscopy, auramine staining and culture as well as chemistry of the fluid including ADA determination.

The diagnostic test sequence in this case was driven primarily by the possibility of hydatid disease. This precluded pericardioscopy directed biopsy and aspiration of the cyst and necessitated surgical removal of the intact cyst. Negative Echinococcus serology (IgM) was not helpful to rule out hydatid disease in this case because of the absence of ultrasound evidence of hepatic involvement. Serology in extrahepatic hydatid disease, including cardiac involvement has lower sensitivity and specificity to rule out the disease. Cysts in the liver are more likely to elicit an antibody response than cysts elsewhere, and, regardless of localisation, antibody detection is least sensitive in patients with intact cysts.<sup>(1)</sup> Therefore, only positive serology is valuable and negative serology does not exclude the diagnosis.<sup>(2)</sup>



**FIGURE 2:** Zoom of the pericardial cystic mass (arrow: bold) seen sandwiched between the liver (arrow) superior and heart inferior. The interior of the cyst is homogenous without septation.

Hydatid disease, a parasitic infestation by a tapeworm of the genus *Echinococcus* rarely causes cardiac involvement although any cardiac structure can be affected. The manifestations depend on the size, location, and integrity of the cyst. The left ventricle is the most commonly involved site (75%) and the pericardium is involved in only 8% of cardiac cases.<sup>(3)</sup> The natural course of hydatid cysts of the heart is rupture.<sup>(4)</sup> This justifies aggressive surgical management.

### FINAL DIAGNOSIS

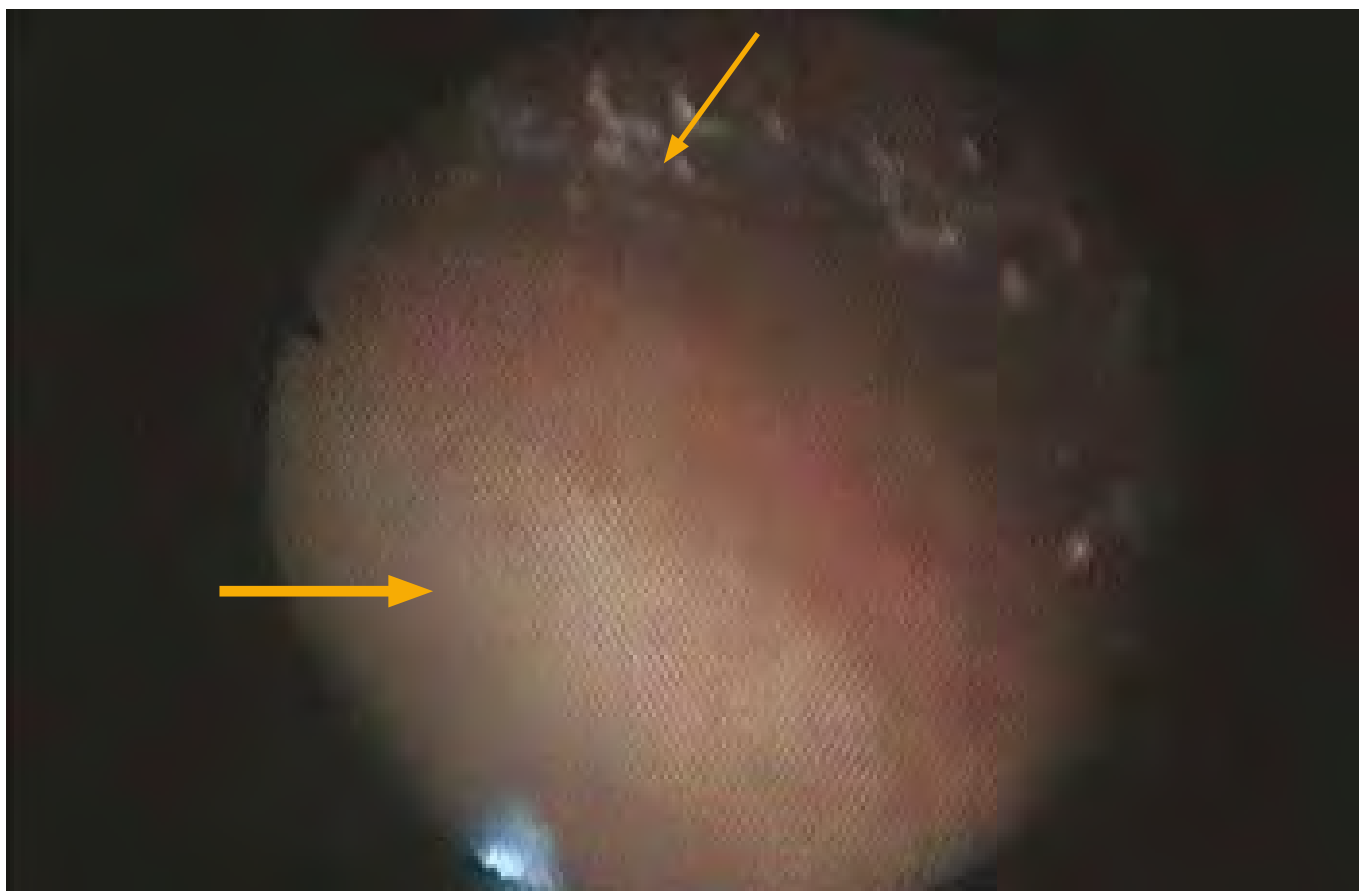
Our patient was demonstrated at surgery to have an organised haematoma related to the stab wound. The cyst had a friable fibrin shell with old blood inside the cyst cavity. All microscopy, histology and microbiological analysis of the cyst including fluid and tissue cultures were negative for tuberculosis. No further tests pointed to hydatid disease.

The pericardium is frequently involved following penetrating trauma to the anterior chest. Diagnosing pericardial involvement

is challenging in a haemodynamically stable patient in the absence of pericardial tamponade.<sup>(5)</sup> Delayed complications are not uncommon and it is advised to investigate all patients with precordial stab wounds with cardiac ultrasound or echocardiography.<sup>(6)</sup>

### REFERENCES

1. Lightowers MW, Gottstein B. Echinococcosis/hydatidosis: antigens, immunological and molecular diagnosis. In: Thompson RCA, Lymbery AJ, editors. Echinococcus and hydatid disease. Wallingford, UK: CAB International; 1995. p. 355-410.
2. Leow CK, Lau WY. Soft-tissue images. Hydatid disease of the liver. *Can J Surg* 2000;43(5):330-1.
3. Kaplan M, Demirtas M, Cimen S, et al. Cardiac hydatid cysts with intracavitary expansion. *Ann Thorac Surg* 2001;71:1587-90.
4. Di Bello R, Mennendez H. Intra-cardiac rupture of hydatid cyst of the heart. *Circulation* 1963;27:366-373.
5. Klinkenberg TJ, Kaan GL, Lacquet LK. Delayed sequelae of penetrating chest trauma: a plea for early sternotomy. *J Cardiovasc Surg (Torino)* 1994;35:173-5.
6. Harris DG, Janson JT, Van Wyk J, et al. Delayed pericardial effusion following stab wounds to the chest. *Eur J Cardiothorac Surg* 2003;23:473-6.



**FIGURE 3:** Pericardioscopy shows a rounded white-yellow mass seen here in the foreground (arrow: bold). Behind this is the pericardial space with air bubbles (arrow).