

## Case Report

### MYELODYSPLASTIC SYNDROME AND EXTRACAPILLARY GLOMERULONEPHRITIS: IS THERE A LINK?

Hamzi M.A.,\* Mahtat E.M.,\*\* Hassani K.,\* Asserraji M.,\* Benyahia M.,\* Oualim Z.\*

\* Department of Nephrology, Dialysis and Renal Transplantation, Military Training Hospital Mohamed V, Rabat, Morocco.

\*\* Department of Clinical Haematology, Military Training Hospital Mohamed V, Rabat, Morocco.

Myelodysplastic syndrome and extracapillary glomerulonephritis: Is there a link?

#### Abstract:

*Introduction:* The association of myelodysplastic syndrome and extracapillary glomerulonephritis is exceptional. Only two other cases have been reported.

*Reported case:* A 52-year-old patient with a history of myelodysplastic syndrome developed rapidly progressive glomerulonephritis. Renal biopsy identified extracapillary glomerulonephritis.

*Discussion:* The association of myelodysplastic syndrome with glomerulopathy is rare and often regarded as fortuitous. Only a few cases are described in literature on the subject. A relationship between the two diseases is possible but the causal link between these two diseases remains unknown.

*Conclusion:* The notion that myelodysplastic syndrome may be associated with various glomerular nephropathies involves looking for renal disease in this haematologic disorder.

*Key words:* Myelodysplastic syndrome, extracapillary glomerulonephritis, pathophysiology

#### Introduction:

The association of myelodysplastic syndrome (MDS) and extracapillary glomerulonephritis (ECGN) is exceptional. Only a few cases of this association have previously been described. All described cases are related to anti-neutrophil cytoplasmic antibodies [1,2]. It is not certain that the two pathologies are linked and their association can seem random. However, some common pathophysiological points may suggest the existence of a probable link between these entities.

#### Reported case:

We report a case of a 52-year-old man, who was followed for 20 years for MDS with involvement of the three bloodlines and monosomy 7, receiving symptomatic treatment (low transfusion requirements, granulocyte colony-stimulating factor) without any specific treatment. This patient was hospitalised in an intensive care unit for severe sepsis due to pulmonary infection with acute renal failure. Empirical antibiotic therapy was established with a favourable course of the infection. The persistence of renal failure led to patient

---

Address correspondence and reprint request to : Dr Hamzi M.A. Hôpital militaire d'instruction Mohammed V, Service de Néphrologie, Dialyse et Transplantation rénale. Hay Riad, BP 10000, Rabat, Maroc.  
Email: [acideamine83@yahoo.fr](mailto:acideamine83@yahoo.fr)

admission in our department. The initial assessment showed renal insufficiency (creatinine at 5.2 mg/dL), proteinuria at 0.6 g/day and microscopic haematuria. A histological study of renal biopsy identified an extracapillary cellular and fibro-cellular proliferation (six glomeruli among 11) without tubulo-interstitial or vascular lesion (Figure 1 and 2). In immunofluorescence, the biopsy showed mesangial deposits of IgM without other specific deposits. Electronic microscopy was not performed. Antineutrophil cytoplasmic antibodies were negative. The rest of the laboratory tests commonly applied to rapidly progressive glomerulonephritis (anti-DNA, anti-glomerular basement membrane, fractions C3 and C4 complement, viral serologies ((hepatitis B and C, HIV)) and cryoglobulinemia) showed no significant abnormalities. The patient subsequently received daily bolus of methyl-prednisolone (500 mg per day) relayed by oral prednisone (1mg/kg/per day) for three days. The outcome was favourable, with a rapid and significant improvement of renal function. Corticosteroid was rapidly reduced and then stopped after seven weeks (creatinine at 1.3 mg/dL after two months). After one year of follow up, serum creatinine was 1.5 mg/dL.

### Discussion:

MDS are a heterogeneous group of disorders characterised by impairment of clonal haematopoietic stem cells and leading to a morphologically abnormal and ineffective haematopoiesis (bone marrow failure) for one or more of the three blood cell lines [3]. The ineffective haematopoiesis is partly due to increased apoptosis of bone marrow precursors. Patients with MDS often develop sepsis. Bacterial infections are the commonest cause [4]. Patients with monosomy 7 and partial deletions of long arm of chromosome 7 have been demonstrated to have impaired neutrophil function [5]. Various glomerular nephropathies associated with MDS have been reported in literature on the subject (table) [1,2,6-10]. In the specific case of post-infectious ECGN,

it appears that genetic factors are necessary for the induction of the disease. Thus, during an epidemic of a 'nephritogenic' germ, only a few patients present with glomerulonephritis, and clinical presentation will differ from one patient to another. Real defects in the glomerular basement membrane were observed during ECGN. These gaps would be secondary to the action of proteolytic enzymes and oxygen radicals released by leukocytes in contact with the glomerular endothelium. These leukocytes are activated by various factors [11] which are the main pro-inflammatory cytokines, particularly IL-1 and TNF- $\alpha$  [12].

Several studies show that chromosomal and gene abnormalities might contribute to dysplastic and apoptotic phenotype of MDS by inhibiting cell survival signals and/or increased pro-apoptotic signals. Other publications have reported elevated levels of TNF- $\alpha$  and IL-2 in MDS [13,14]. TNF- $\alpha$  secreted by undifferentiated bone marrow mononuclear cells is identified as a key cytokine in the genesis of apoptosis in MDS [15]. The pathophysiological mechanism involved in the genesis of glomerular nephropathy in patients with MDS is still unclear. A pathogenic role has been attributed to immune dysregulation [16]. TNF- $\alpha$  is increased in both ECGN and MDS, but it could be a late consequence of the immunological cascade that leads to the appearance of ECGN. The hypothesis of a common genetic predisposition is evoked because of the presence of a genetic predisposition during ECGN and the existence of a great diversity of genetic abnormalities in MDS.

The diagnosis of MDS and glomerulopathy was simultaneous in most described cases [1,2,6,8]. In some of these cases the etiopathogenic treatment of one entity leads to the curing of another [2,6]. In the case of our patient, ECGN has occurred after a long evolution of an MDS complicated by a late severe infection.

### Conclusion:

It remains unclear why MDS may be associated with other glomerulopathies such as extra

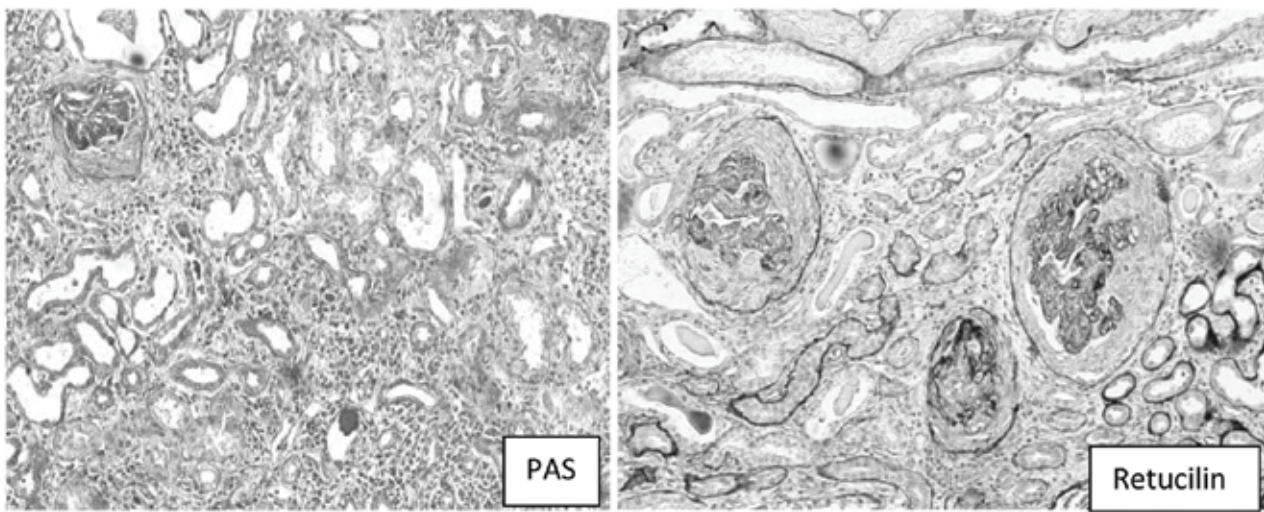
capillary glomerulonephritis (ECGN). However, renal impairment must be looked for in MDS.

#### References:

1. Komatsuda A. *Crescentic glomerulonephritis accompanied by myeloperoxidase anti-neutrophil cytoplasmic antibodies in a patient suffering from myelodysplastic syndrome with trisomy 7*. Am J Kidney Dis 1998; 31: p. 336-340.
2. Morschhauser F. *Glomerular injury in chronic myelomonocytic leukemia*. Leuk-Lymphoma 1995; 18: p. 479-483.
3. Heaney M.L. *Myelodysplasia*. New England Journal of Medicine 1999; 340: p. 1649-1660.
4. Pomeroy C., Oken M.M., Rydell R.E., et al. *Infection in the myelodysplastic syndromes*. Am J Med 1991; 90: p. 338-44.
5. Ruutu P., Ruutu T., Repo H., et al. *Defective neutrophil migration in monosomy 7*. Blood 1981; 58: p. 39-45.
6. Paydas S. *A case with membranous glomerulonephritis and myelodysplastic syndrome*. Nephron 1992; 62: p. 231-232.
7. Enright H. *Paraneoplastic autoimmune phenomena in patients with myelodysplastic syndromes: Response to immunosuppressive therapy*. British Journal of Haematology 1995; 91: p. 403-408.
8. Doukkali O. *Glomérulonéphrite extra-membraneuse et syndrome myélodysplasique*. Néphrologie 2004; 25 (2): p. 59-61.
9. Saitoh T. *Myelodysplastic syndromes with nephrotic syndrome*. American Journal of Haematology 1999; 60: p. 200-204.
10. Hayashi S. *A case of myelodysplastic syndrome associated with IgA nephropathy*. Nippon Ronen Igakkai Zasshi 1999; 36: p. 373-376.
11. Bonsib S.M. *Glomerular basement membrane discontinuities: Scanning electron microscopic study of acellular glomeruli*. American Journal of Pathology 1985; 119: p. 357-360.
12. Atkins R.C. *Modulators of crescentic glomerulonephritis*. Journal of the American Society of Nephrology 1996; 11: p. 2271-8.
13. Kitagawa M. *Overexpression of tumour necrosis factor (TNF)-alpha and interferon (IFN)-gamma by bone marrow cells from patients with myelodysplastic syndromes*. Leukaemia 1997; 11: p. 2049-2054.
14. Zombos N. *Increased levels of soluble interleukin-2 receptors and tumour necrosis factor in serum of patients with myelodysplastic syndromes*. Blood 1991; 77: p. 413-414.
15. Raza A. *Novel insights into the biology of myelodysplastic syndromes: Excessive apoptosis and the role of cytokines*. Int J Haematol 1996; 63: p. 265-278.
16. Bogdanovi R. *Glomerular involvement in myelodysplastic syndromes*. Pediatric Nephrology 2001; 16: p. 1053-1057

Table: glomerular nephropathies associated with MDS previously reported.

Authors	Described glomerulonephritis	Number of cases
Komatsuda A. [1]	Extracapillary glomerulonephritis	1 case
Morschhauser F. [2]	Extracapillary glomerulonephritis AL Amyloidosis	1 case 1 case
Paydas S. [6]	Membranous glomerulonephritis	1 case
Enright H. [7]	Membranous glomerulonephritis	1 case
Doukkali O. [8]	Membranous glomerulonephritis	1 case
Saitoh T. [9]	Diffuse mesangial proliferation	1 case
	Nephrotic syndrome	4 cases
Hayashi S. [10]	Ig A nephropathy	1 case
Reported case	Extracapillary glomerulonephritis	1 case



Photos 1 and 2: Renal biopsy examined by light microscopy (Periodic acid-Schiff (1) and reticulin (2) stains): circumferential epithelial Croissants.

**Résumé:**

**Introduction:** L’association d’un syndrome myélodysplasique (SMD) et d’une glomérulonéphrite extra-capillaire est exceptionnelle. Seuls deux cas ont été décrits jusqu’à présent.

**Observation:** Il s’agit d’un patient de 52 ans, avec un antécédent de syndrome myélodysplasique, qui a développé un syndrome de glomérulonéphrite rapidement progressive. La biopsie rénale a objectivé une glomérulonéphrite extra-capillaire.

**Discussion:** L’association d’un syndrome myélodysplasique à une glomérulopathie est exceptionnelle et souvent considérée comme fortuite. Seuls quelques cas sont décrits dans la littérature. Une relation entre les deux pathologies est possible. Le lien de causalité entre ces deux affections demeure inconnu.

**Conclusion:** la notion selon laquelle le syndrome myélodysplasique peut s’accompagner de néphropathies glomérulaires diverses implique de rechercher une atteinte rénale au cours de cette affection hématologique.