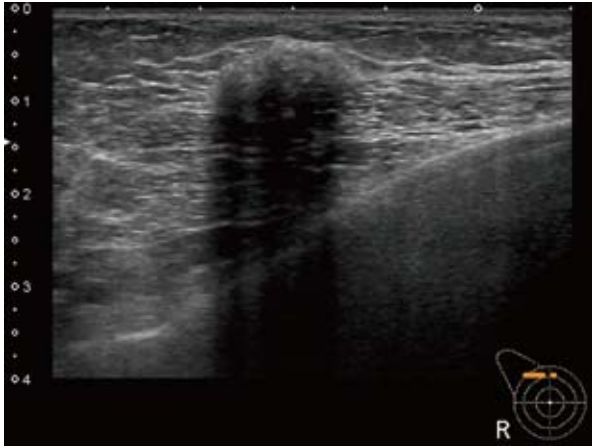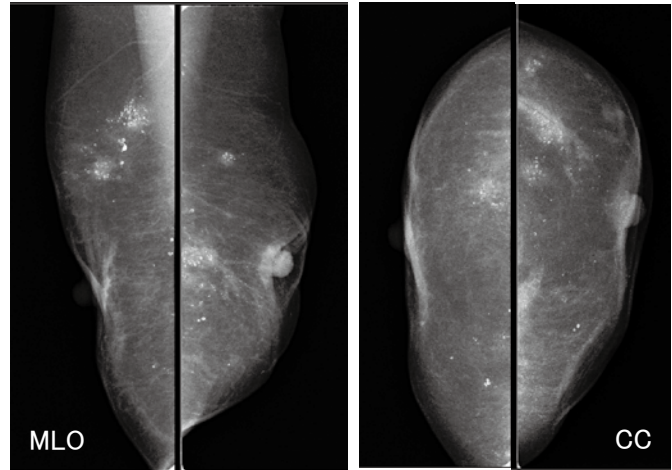
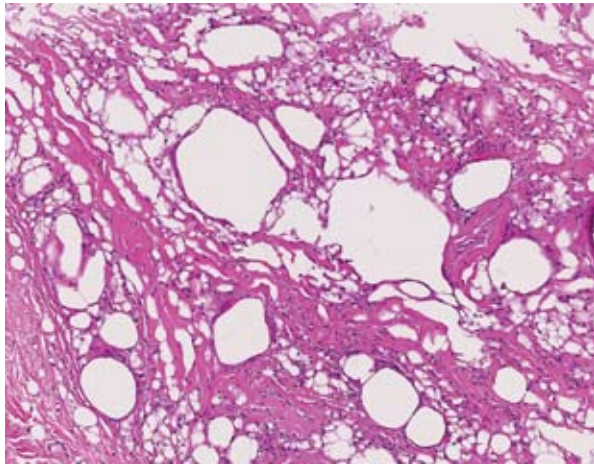


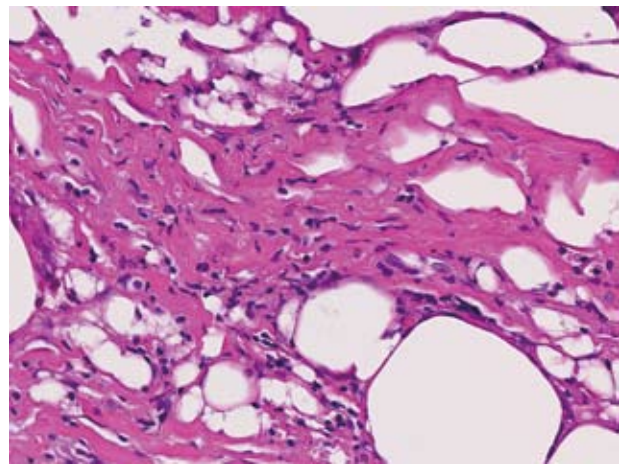
**Fig. 1** Ultrasound examination revealed a hypoechoic mass in the upper right breast. The mass was 2.9×1.7 cm with irregular, ill-defined borders and posterior echo attenuation.



**Fig. 2** Mammography revealed some areas of elevated density with coarse, lucent-centered calcifications in bilateral breasts but no clear findings of malignancy.



**A**



**B**

**Fig. 3** Core needle biopsy sample : Marked fibrous hyperplasia and proliferation of fibroblast-like spindle cells were observed. Infiltration of neutrophils and plasma cells was observed in the stroma. There were spindle cells with no atypia cells and scarce mitotic figures. Thus, the patient was diagnosed with inflammatory pseudotumor (hematoxylin and eosin stain. **A** : ×100, **B** : ×400).

posterior echo attenuation (Breast Imaging Reporting and Data System (BI-RADS) category 4b (intermediate suspicion for malignancy)) (Fig. 1). Mammography revealed some areas of elevated density with coarse, lucent-centered calcifications in bilateral breasts but no clear findings of malignancy (Fig. 2). Histopathological findings of core needle biopsy showed marked fibrous hyperplasia and proliferation of fibroblast-like spindle cells. Infiltration of neutrophils and plasma cells was observed in the stroma. There were spindle cells with no atypia and scarce mitotic figures. Thus, the patient was diagnosed with inflammatory pseudotumor (Figs. 3A and B). IgG4 im-

munostaining was negative (results not shown). The patient received only follow-up observation without surgical resection as per the patient's wishes. There has not been any change as of May 2013.

## DISCUSSION

Inflammatory pseudotumor is a benign nodular lesion with tumor-like clinical presentation. However, its histological features include non-specific inflammation and mesenchymal repair. There is proliferation of spindle cells with the characteristics mainly of myofibroblasts or fibroblasts. Marked infiltration of inflammatory cells is also seen including of lymphocytes and

Table 1 Case report of inflammatory pseudotumor of the breast

Case	Author (s)	Year of publication	Age	Sex	Medical history	Circumstance of discovery	Size (cm)	Preoperative diagnosis	Surgical resection or follow-up alone	Recurrence/ follow-up period	Other
1	Vecchio GM	2011	22	M	Injury	Self-discovered breast mass	7	No	Resection	No/10 mo.	
2	Sari A	2011	54	F	Non-contributory	Self-discovered breast mass	2.7	No	Resection	No/4 mo.	
3	Hill PA	2010	53	F	Non-contributory	Self-discovered breast mass	3.5	No	Resection	Unknown	IgG4+
4	Kim SJ	2009	60	F	Non-contributory	By MMG exam	1.5	Yes (using MMT)	Resection	No/2 yr	
5	Park SB	2009	47	F	Non-contributory	Self-discovered breast mass	3.5	Yes (using CNB)	Resection	No/3 yr	
6	Akbulut M	2007	38	F	Non-contributory	Self-discovered breast mass	1	No	Resection	No/1 yr	
7	Khanafshar E	2005	33	F	Non-contributory	Self-discovered breast mass	2	Unknown	Resection	Yes/after 3 mo	
			75	F	Non-contributory	Self-discovered breast mass	3	Unknown	Resection	No/7 mo	
			47	F	Previous breast cancer resection	By MRI exam	Unknown	Unknown	Follow-up	No change/6 mo	
8	Zen Y	2005	46	F	Non-contributory	Self-discovered breast mass	2.1	Unknown	Resection	No/12 mo	High serum IgG4
9	Ilván S	2005	60	F	Non-contributory	Self-discovered breast mass	1	No	Resection	No/85 mo	
10	Zardawi IM	2003	79	F	Non-contributory	By MMG exam	<1.5	No	Resection	Yes/after 9 yr	
11	Haj M	2003	31	F	Non-contributory	Self-discovered breast mass	6	Yes (using CNB)	Resection	Unknown	
12	Sastre-Garau X	2002	64	F	Non-contributory	By MMG exam	3	No	Resection	No/33 mo	
13	Gobbi H	1999	86	F	Non-contributory	Self-discovered breast mass	1.5	No	Resection	Unknown	
14	Yip CH	1997	66	F	Non-contributory	Self-discovered breast mass	3	No	Resection	Yes/ after 5 mo	
15	Chetty R	1997	16	F	Non-contributory	Self-discovered breast mass	2	Unknown	Resection	No/12 mo	
			46	F	Non-contributory	Self-discovered breast mass	2	Unknown	Resection	No/12 mo	
			18	F	Non-contributory	Self-discovered breast mass	8	Unknown	Resection	No/6 mo	
16	Bisceglia M	1995	38	F	Non-contributory	By MMG exam	1	Unknown	Resection	No/12 mo	
17	Coffin CM	1995	13	F	Non-contributory	Unknown	4	Unknown	Resection	No/12 mo	
18	Pettinato G	1988	29	F	Non-contributory	Self-discovered breast mass	4.5	No	Resection	No/30 mo	
19	Ishizuna K (this case report)	2013	78	F	Previous augmentation mammoplasty	Self-discovered breast mass	2.9	Yes (using CNB)	Follow-up	No change/6 mo	

plasma cells<sup>1,2)</sup>. Inflammatory pseudotumor can occur in any part in the body but it most commonly involves the lung, liver, orbit, gastrointestinal tract, and soft tissues. It rarely occurs in the breast, and there have been only 19 articles (23 cases) of English-language reports since Pettinato reported the first case in 1988 (PubMed search by keywords “inflammatory pseudotumor” and “breast”) (Table 1)<sup>3~20)</sup>.

The mean age was 47.8 years (range 13–86 years) for 23 cases, including the patient in our report. These patients consisted of 1 man and 22 women. Three patients had a history of injury or surgery. Five patients had a breast mass discovered by mammography or MRI, and seventeen patients had a self-discovered breast mass. All patients had a solitary mass and the mean size was 3.0 cm (range : 1–8 cm). Cytological examination was performed in 6 patients<sup>7,9,12,13,16,20)</sup> but a definitive diagnosis could not be made. Needle biopsy or mammotome biopsy was performed in five patients<sup>3~6)</sup>, of whom four were diagnosed with inflammatory pseudotumor. Except in our patient, determination of malignancy could not be made based on imaging findings, and the mass was surgically resected. Three of twenty-one patients with surgical resection had recurrence in the breast.

There are only a small number of imaging reports on inflammatory pseudotumor of the breast. It is depicted in mammographic images as a high-density mass with ill-defined borders in many cases<sup>3~8)</sup>. One case had spicules<sup>9)</sup>. In many cases, inflammatory pseudotumor is depicted in mammary ultrasound images as a hypoechoic mass with irregular, ill-defined borders<sup>4,6,8)</sup>. One case with echogenic halo has been reported<sup>4)</sup>. Thus, there are cases in which differentiation is difficult between inflammatory pseudotumor of the breast and breast cancer based on imaging, and most reported cases had undergone surgical resection for diagnosis and treatment.

Some studies have suggested that inflammatory pseudotumors are associated with infection, injury<sup>21)</sup>, local ischemic changes due to thromboembolism<sup>22)</sup>, EB virus<sup>23,24)</sup>, and IgG4-related disease<sup>12,14)</sup>. However, there has not been a consensus on the cause of inflammatory pseudotumor. Lymphovascular invasion, local recurrence<sup>7,9,10)</sup>, or distant metastasis<sup>25)</sup> can sometimes occur. Abnormalities of chromosome 2p23 and

ALK-1 protein expression are observed in some cases. Thus, there has been a recent proposal to classify inflammatory pseudotumor as a true neoplasm<sup>26,27)</sup>.

The patient in our report had an inflammatory pseudotumor of the breast after augmentation mammoplasty. Ultrasound findings raised suspicion of breast cancer, and core needle biopsy was performed which revealed an inflammatory pseudotumor. The pathogenesis of inflammatory pseudotumor has not yet been elucidated, and more cases need to be accumulated. Inflammatory pseudotumors have malignant potential as mentioned previously. Normally, surgical resection should be considered, but the patient in our report was an elderly person and did not wish to undergo surgery. Thus, she received only follow-up observation without surgery, and no changes have been observed.

## CONCLUSION

We reported a case of inflammatory pseudotumor that occurred after augmentation mammoplasty. There are only a small number of reported cases of inflammatory pseudotumor of the breast. It will be necessary to accumulate more cases to elucidate its pathogenesis.

## REFERENCES

- 1) Narla LD, Newman B, Spottswood SS, et al : Inflammatory pseudotumor. *RadioGraphics* **23** : 719, 2003.
- 2) Coffin CM, Dehner LP, Meis-Kindblom JM : Inflammatory myofibroblastic tumor, inflammatory fibrosarcoma, and related lesions : an historical review with differential diagnostic considerations. *Semin Diagn Pathol* **15** : 102, 1998.
- 3) Sari A, Yigit S, Peker Y, et al : Inflammatory pseudotumor of the breast. *Breast J* **17** : 312-314, 2011.
- 4) Kim SJ, Moon WK, Kim JH, et al : Inflammatory pseudotumor of the breast : a case report with imaging findings. *Korean J Radiol* **10** : 515-518, 2009.
- 5) Park SB, Kim HH, Shin HJ, et al : Inflammatory pseudotumor (myoblastic tumor) of the breast : a case report and review of the literature. *J Clin Ultrasound* **38** : 52-55, 2010.
- 6) Haj M, Weiss M, Loberant N, et al : Inflammatory pseudotumor of the breast : case report and literature review. *Breast J* **9** : 423-425, 2003.
- 7) Yip CH, Wong KT, Samuel D : Bilateral plasma cell granuloma (inflammatory pseudotumour) of the

- breast. *Aust N Z J Surg* **67** : 300-302, 1997.
- 8) Bisceglia M, Fusilli S, Zaffarano L, et al : Inflammatory pseudotumor of the breast. Report of a case and review of the literature. *Pathologica* **87** : 59-64, 1995.
  - 9) Zardawi IM : Inflammatory myofibroblastic tumor of the breast. *Acta Cytologica* **47** : 1077-1081, 2003.
  - 10) Khanafshar E, Phillipson J, Schammel DP, et al : Inflammatory myofibroblastic tumor of the breast. *Ann Diagn Pathol* **9** : 123-129, 2005.
  - 11) Vecchio GM, Amico P, Grasso G, et al : Post-traumatic inflammatory pseudotumor of the breast with atypical morphological features : A potential diagnostic pitfall. Report of a case and a critical review of the literature. *Pathol Res Pract* **207** : 322-326, 2011.
  - 12) Hill PA : Inflammatory pseudotumor of the breast : a mimic of breast carcinoma. *Breast J* **16** : 549-550, 2010.
  - 13) Akbulut M, Gunhan-Bilgen I, Zekioglu O, et al : Fine needle aspiration cytology of inflammatory myofibroblastic tumour (inflammatory pseudotumour) of the breast : a case report and review of the literature. *Cytopathology* **18** : 384-387, 2007.
  - 14) Zen Y, Kitagawa S, Minato H, et al : IgG4-positive plasma cells in inflammatory pseudotumor (plasma cell granuloma) of the lung. *Hum Pathol* **36** : 710-717, 2005.
  - 15) Ilvan S, Celik V, Paksoy M, et al : Inflammatory myofibroblastic tumor (inflammatory pseudotumor) of the breast. *APMIS* **113** : 66-69, 2005.
  - 16) Sastre-Garau X, Couturier J, Derré J, et al : Inflammatory myofibroblastic tumour (inflammatory pseudotumour) of the breast. Clinicopathological and genetic analysis of a case with evidence for clonality. *J Pathol* **196** : 97-102, 2002.
  - 17) Gobbi H : Inflammatory myofibroblastic tumor of the breast : report of a case with giant vacuolated cells. *The Breast* **8** : 135-138, 1999.
  - 18) Chetty R, Govender D : Inflammatory pseudotumor of the breast. *Pathology* **29** : 270-271, 1997.
  - 19) Coffin CM, Watterson J, Priest JR, et al : Extrapulmonary inflammatory myofibroblastic tumor (inflammatory pseudotumor). A clinicopathologic and immunohistochemical study of 84 cases. *Am J Surg Pathol* **19** : 859-872, 1995.
  - 20) Pettinato G, Manivel JC, Insabato L, et al : Plasma cell granuloma (inflammatory pseudotumor) of the breast. *Am J Clin Pathol* **90** : 627-632, 1988.
  - 21) Kawashima K, Onuma E, Majima T, et al : Two Cases of Inflammatory Pseudotumor of The Spleen. *Jpn J Gastroenterol Surg* **33** : 357-361, 2000.
  - 22) Cotelingam JD, Jaffe ES : Inflammatory pseudotumor of the spleen. *Am J Surg pathol* **8** : 375-380, 1984.
  - 23) Arber DA, Kamel OW, Rijn M, et al : Frequent presence of the Epstein-Barr virus in inflammatory pseudotumor. *Hum Pathol* **26** : 1093-1098, 1995.
  - 24) Coffin CM, Humphrey PA, Dehner IP, et al : Extrapulmonary inflammatory myofibroblastic tumor : A clinical and pathological survey. *Semin Diagn Pathol* **15** : 85-101, 1998.
  - 25) Maier HC, Sommers SC : Recurrent and metastatic pulmonary fibrous histiocytoma/plasma cell granuloma in a child. *Cancer* **60** : 1073-1076, 1987.
  - 26) Cessna MH, Zhou H, Sanger WG, et al : Expression of ALK1 and p80 in inflammatory myofibroblastic tumor and its mesenchymal mimics : a study of 135 cases. *Mod Pathol* **15** : 931-938, 2002.
  - 27) Freeman A, Geddes N, Munson P, et al : Anaplastic lymphoma kinase (ALK1) staining and molecular analysis in inflammatory myofibroblastic tumours of the bladder : a preliminary clinicopathological study of nine cases and review of the literature. *Mod Pathol* **17** : 765-771, 2004.