

Case Report

Block of the Ganglion Impar for Treatment of a Patient with Non-malignant Chronic Perineal Pain

Shinsuke Hamaguchi, Hirotohi Egawa, Masaru Nagao, Tomohito Ikeda,
Yoshiyuki Kimura, Yasuhisa Okuda and Toshimitsu Kitajima

Department of Anesthesiology, Dokkyo University School of Medicine

SUMMARY

A 62 year-old woman with chronic perineal pain was successfully managed by chemical neurolysis. When she was referred to us, other practitioners had already investigated her. However, the cause of pain was not identified and the pain was refractory to conventional analgesic treatment. She underwent caudal block with 0.25% bupivacaine 5 ml six times to avoid placebo response of the block prior to therapeutic neurolysis. Then, block of the ganglion impar with phenol water under fluoroscopy was performed. Six months later, she still has no pain.

Key Words : block of the ganglion impar, perineal pain, non-malignant disease

INTRODUCTION

The cause of chronic perineal pain is sometimes unidentified and the pain does not respond well to conventional analgesic treatment. Block of the ganglion impar (ganglion of Walther) with neurolytics has recently been used for treatment of cancer patients with intractable perineal pain¹⁾. We herein report that block of the ganglion impar with phenol water was successfully used in a non-malignant patient with chronic perineal pain.

CASE HISTORY

The patient was a 62 year-old woman with the chief complaint of chronic perineal pain. She underwent cholecystectomy 30 years ago and cervicoplasty 7 years ago. She has had persistent pain in the perineal region for the last three years. She felt severe pain due to chafing caused by underwear and when urinating. She was examined in internal medicine, gynecology and urology, but no cause was found. She took several courses of analgesics, antibiotics and urinary antiseptics. These medications did-

n't relieve the pain. She was sent to psychiatry. She was diagnosed as having depression and treated with antidepressants. However, medication did not relieve the pain. She was referred to our clinic for pain management. She presented with severe pain, scoring 80 mm using a visual analogue scale (VAS). She was admitted to the hospital and underwent caudal block with 0.25% bupivacaine 5 ml six times. It relieved the pain for several hours. Since caudal block with a neurolytic was not desirable, we planned to block the ganglion impar with phenol water under fluoroscopy using Wemm and Saberski's technique¹⁾, which is one of sympathetic block for relief of pain.

The block was fully explained to the patient, and informed consent was obtained from her. She was placed in the lateral decubitus position with her knees drawn up to her stomach on the fluoroscopic table. The skin on the buttocks above the anus was sterilized with an antiseptic solution. A skin wheal was made in the midline at the superior aspect of the intergluteal crease. A nerve block needle (22-gauge, 7 cm) was bent approximately 4 cm from the tip of the needle to form a 25° angle. The needle was then inserted through the skin wheal with its concavity oriented posteriorly in a lateral view under fluoroscopic guidance. It was directed anterior to the coccyx, approximating the anterior surface of the bone, until its tip was observed to have reached the sacrococcygeal junction.

Received October 24, 2002 ; accepted November 19, 2002

Reprint requests to : Shinsuke Hamaguchi

Dokkyo University School of Medicine, Mibu,
Tochigi, 321-0293 Japan

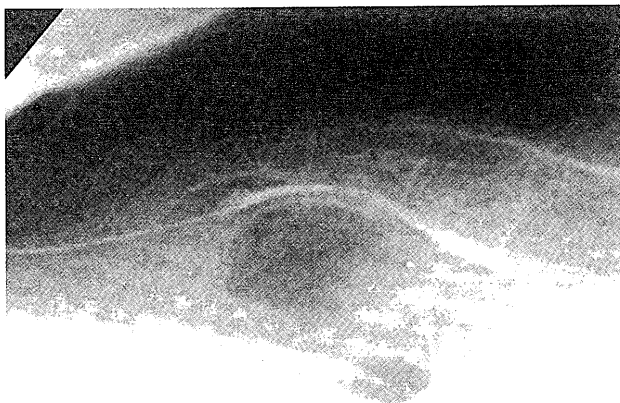


Fig. 1 Lateral radiograph reveals correct placement of a bent needle (22-gauge, 7 cm) and the spread of the contrast medium for block of the ganglion impar.

Two percent of mepivacaine 2 ml with 2 ml of the contrast medium, iohexol 240 mg/ml, was injected through the needle (Fig.1). Retroperitoneal location was verified by observing the spread of the contrast medium. Twenty min after injecting the local anesthetic with the contrast medium, we confirmed pain relief and observed no adverse effects. Then we injected 7% phenol water 4 ml through the needle. Since VAS decreased from 80 to 30 mm on the first day after the block, she left the hospital. After that she underwent caudal block once a week in the outpatient clinic, and VAS turned from 30 to 0 mm on the 30th day after leaving the hospital. She was seen six months later and was still pain free.

DISCUSSION

Chronic pelvic or perineal pain accounts for 2 to 10% of outpatient gynecology consultations, and the pain disturbs patients' quality of life²⁾. The etiologies of chronic pelvic or perineal pain are gynecological diseases or dysfunction, urological diseases, musculo-skeletal diseases, neuropathic origin, painful dermatological diseases, referred pain due to intra-abdominal diseases and psychological diseases³⁻⁹⁾. However, the etiology is sometimes unknown, and the pain is refractory to analgesic treatment such as medicinal treatment, trigger point injection with a local anesthetic and muscle exercise.

These patients are the subject of aggressive investigation, or the labeling of their complaints as totally psychosomatic^{10,11)}. We perform nerve blocks with a local anesthetic on such patients as a diagnostic procedure.

Repeated caudal blocks are usually effective for the pain. However, reversible blocks with a local anesthetic may not induce permanent pain relief. If nerve blocks are not effective for patients with unidentified perineal pain, we investigate psychological causes. With cancer patients, we sometimes use chemical neurolysis such as caudal block with neurolytics, intrathecal phenol block or block of the ganglion impar with neurolytics^{1, 12-14)} after confirming the effectiveness of caudal block with a local anesthetic. However, these somatic nerve blocks induce a high incidence of urinary dysfunction or incontinence. Therefore, caudal block with neurolytics or intrathecal phenol block was not desirable for non-malignant patients. Block of the ganglion impar may be preferable for such patients because it is a sympathetic block. The sacral sympathetic trunk is located on the inside of the anterior sacral foramen. The bilateral trunks are narrow so they send the spinal column, finally forming the ganglion impar when they come together on the anterior surface of the coccyx. The ganglion is concerned with nociception from the perineal region, and block of the ganglion impar has been used for intractable pain¹⁾.

It is well known that sympathetic block is also used in the treatment of non-malignant patients with sympathetically maintained pain such as complex regional pain syndrome (CRPS). However, there have so far been no reports on effectiveness of block of the ganglion impar for non-malignant patients. We used block of the ganglion impar in a patient with chronic perineal pain of unknown etiology as a therapeutic block. Wemm and Saberski's technique can be performed under fluoroscopy. It is recognized that injection of a local anesthetic or neurolytic 4 ml through a needle may interrupt the ganglion impar to the sacral sympathetic nerve by the spread of a contrast medium. Dysuria, incontinence and sensory disturbance of the pudendum occur as complications if a neurolytic spreads to the sacral nerves. Rectal injury also occurs if a needle is inadequately inserted.

Taylor¹⁵⁾ reported that the effect of emotional stress in the pelvis induces a pelvic autonomic syndrome with vascular disturbance and muscular contraction due to an increase of sympathetic flow to the innervated structures. It has also been reported that CRPS rarely occurs in the penis or testicle^{8,9)}. Our patient might have had CRPS because she presented with persistent pain and allodynia.

CONCLUSION

We successfully used the block of ganglion impar, a sympathetic nerve block, using a local anesthetic or neurolytic, for the pain relief in a non-malignant chronic perineal pain patient.

REFERENCES

- 1) Wemm K, Jr, Saberski L : Modified approach to block the ganglion impar (ganglion of Wlther). *Region Anesth*, **20** : 544-545, 1995.
- 2) Mathias SD, Kuppermann M, Liberman RF, et al : Chronic pelvic pain : Prevalence, health-related quality of life, and economic correlates. *Obstetric Gynecolog*, **87** : 321-327, 1996.
- 3) Bonica JJ. : General considerations of abdominal pain. in "The Management of Pain." ed by Bonica JJ, Lea & Febiger, London, pp 1285-1312, 1990.
- 4) Boas RA, Schug SA, Acland RH. : Perineal pain after rectal amputation : 5-year follow up. *Pain*, **52** : 67-70, 1993.
- 5) Liang CC, Tsai CC, Chen TC, et al : Management of perineal endometriosis. *Int J Gynecol Obstet*, **53** : 261-265, 1996.
- 6) Moul JW. : Prostatitis. Sorting out the different causes. *Postgrad Med*, **94** : 191-194, 1993.
- 7) Batta AG, Gundian JC, Myers RP. : Neurofibromatosis presenting as perineal pain and urethral burning. *Urolog*, **33** : 138-140, 1989.
- 8) Chalkley JE, Lander C, Rowlinson JC. : Probable reflex sympathetic dystrophy of the penis. *Pain*, **25** : 223-225, 1986.
- 9) McCleane G. : A case of complex regional pain syndrome affecting the testicle. *The Pain Clinic*, **9** : 89-91, 1996.
- 10) Milano R. : Pelvic pain : problems in diagnosis and treatment. In "Proceedings of the IV th World Congress on Pain" ed by Bond MR, Charlton JE, Woolf CJ, Elsevier Science Publishers BV, Amsterdam, pp 453-458, 1991.
- 11) Bodden-Heidrich R, Kupperts V, Beckmann MW, et al : Psychosomatic aspects of vulvodynia. Comparison with the chronic pelvic syndrome. *J Reprod Med*, **411-416**, 1999.
- 12) Robertson DH. : Transsacral neurolytic nerve block. An alternative approach to intractable perineal pain. *Br J Anaesth*, **55** : 873-875, 1983.
- 13) Ischia S, Luzzani A, Ischia A, Magon F, et al : Subarachnoid neurolytic block (L5-S1) and unilateral percutaneous cervical cordotomy in the treatment of pain secondary to pelvic malignant disease. *Pain*, **20** : 139-149, 1984.
- 14) Rockswold GL, Bradley WE. : The use of sacral nerve blocks in the evaluation and treatment of neurologic bladder disease. *J Urology*, **118** : 415-417, 1977.
- 15) Taylor HC, Jr : Pelvic pain based on a vascular and autonomic nervous system disorder. *Am J Obstet Gynecol*, **67** : 1177-1196, 1953.