

〈Regular Article〉

Assessment of chest movements in tetraplegic patients using a three-dimensional motion analysis system

Takefumi SUGIYAMA¹⁾, Kozo HANAYAMA¹⁾, Hiromichi METANI¹⁾,
Sosuke SEKI¹⁾, Akio TSUBAHARA¹⁾, Kazunari FURUSAWA²⁾,
Masaki HYODO³⁾

1) Department of Rehabilitation Medicine, Kawasaki Medical School

2) Kibikogen Rehabilitation Center for Employment Injuries

3) Department of Rehabilitation Medicine, Isehara Kyodo Hospital

ABSTRACT We used optoelectronic plethysmography (OEP) to evaluate the effects of posture on chest and abdominal movements during respiration in patients with chronic-stage complete spinal cord injuries. The subjects were five cervical injury patients (male, C4-C8 injury, American Spinal Injury Association Impairment Scale grade A) and five healthy people matched to each of the cervical injury patients for age, height, and weight. The chest wall movement each of the subjects was recorded using OEP during six quiet breathing and three deep breathing periods in each of the following positions: supine, with the trunk elevated to 30°, and with the trunk elevated to 60°. Data on the chest wall volume and compartment volumes (upper thorax, lower thorax, abdomen) were then compared among the postures. During quiet breathing in the tetraplegic patients, the change in upper thorax volume was smaller at the end of inhalation than at the end of exhalation, presenting as a paradoxical breathing pattern. During deep breathing in the tetraplegic patients, abdominal volume accounted for a large portion of the change in total chest wall volume. Posture affected the recorded abdominal volume; volume was greatest in the supine position and decreased as the posture became more upright.

doi:10.11482/KMJ-E43(2)95 (Accepted on October 12, 2017)

Key words : Spinal cord injury, Optoelectronic plethysmography, Respiration, Paradoxical breathing, Three-dimensional motion analysis system

INTRODUCTION

In 1963, Stone and Keltz¹⁾ published the first detailed report on the pulmonary functions of patients with cervical and thoracic spinal cord injuries. Since then, there have been reports

on how respiratory dysfunction due to spinal cord injury relates to injury level²⁻⁴⁾ and lung complications⁵⁻⁷⁾. In patients with complete cervical spinal cord injuries, even if the diaphragm is spared, the main respiratory muscles (such as

Corresponding author
Takefumi Sugiyama
Department of Rehabilitation Medicine, Kawasaki
Medical School, 577 Matsushima, Kurashiki, 701-0192,
Japan

Phone : 81 86 462 1111
Fax : 81 86 464 1044
E-mail: t.sugiyama@med.kawasaki-m.ac.jp

the internal intercostals, external intercostals, and abdominals) are paralyzed; this can produce abnormal respiratory movements such as paradoxical breathing, a phenomenon known to occur in the acute stage⁸⁻¹¹. Moreover, paralysis of the abdominal muscles reduces abdominal wall tension, causing the organs in the abdominal cavity to shift anteriorly and the diaphragm to flatten in the sitting position, reducing ventilation efficiency^{12, 13}.

Optoelectronic plethysmography (OEP) has been used to continuously and noninvasively analyze these respiratory movements¹⁴. In this method, multiple markers are placed on the surface of the body and changes in their coordinates are recorded using several cameras simultaneously. The movements of the markers are then reconstructed in three dimensions (3D) on a personal computer (PC) to analyze the chest wall movements¹⁴. This method has been used in many studies on chronic obstructive pulmonary disease and other respiratory organ diseases¹⁵⁻²³, but there have been very few studies on spinal cord injuries. Miccinilli *et al.*²⁴ used OEP to compare the respiratory functions of healthy people, paraplegic patients, and tetraplegic patients. Their results showed that the chest movements of tetraplegic patients were significantly smaller than those of paraplegic patients, and that the abdomen was the primary factor affecting the respiratory movements of the chest wall overall. Their report did not describe the sitting position in detail although tetraplegic patients are unstable in the sitting position in general, and analyzed complete and incomplete spinal cord injuries in the same group.

It is known that in patients with neuromuscular disease causing diaphragm weakness, posture may have a significant impact on vital capacity. If vital capacity is lower when the patient is in the supine position, nocturnal hypoventilation is suspected²⁵. Because patients with spinal cord injury have a different distribution of muscle weakness from

patients with neuromuscular disease, different patterns of respiratory response due to posture are expected. How the chest wall moves according to the patient's posture is important to know for planning exercise, for respiratory management in the recovery and chronic phases, and for maintenance and improvement of respiratory function and chest wall compliance.

The objective of the present study was to use OEP to analyze chest and abdominal movements during respiration in patients with chronic-stage complete spinal cord injuries to clarify how these movements are affected by posture.

MATERIALS AND METHODS

Subjects

We recruited men with traumatic spinal cord injuries sustained at least 6 months prior and who could breathe independently. The inclusion criteria were: (1) stable condition with no acute respiratory diseases or other such complications for the past 4 weeks; and (2) American Spinal Injury Association Impairment Scale (AIS) grade A. The exclusion criteria were: (1) inability to follow instructions for the test due to cognitive dysfunction or other issues, and (2) presence of respiratory complications.

For the control group, we recruited healthy people matched to each spinal injury patient for sex, age, height, and weight.

This study was approved by the ethics committee of the Kibikogen Rehabilitation Center for Employment Injuries in April 2016 (application no. 9-1). Before the study began, consent was obtained from all subjects.

Study protocol

With each subject lying supine on a hard bed, 45 reflective markers were placed on each patient's chest wall in predetermined locations (Fig. 1). To determine a reference plane on the bed, four markers were placed on the backrest in locations where they

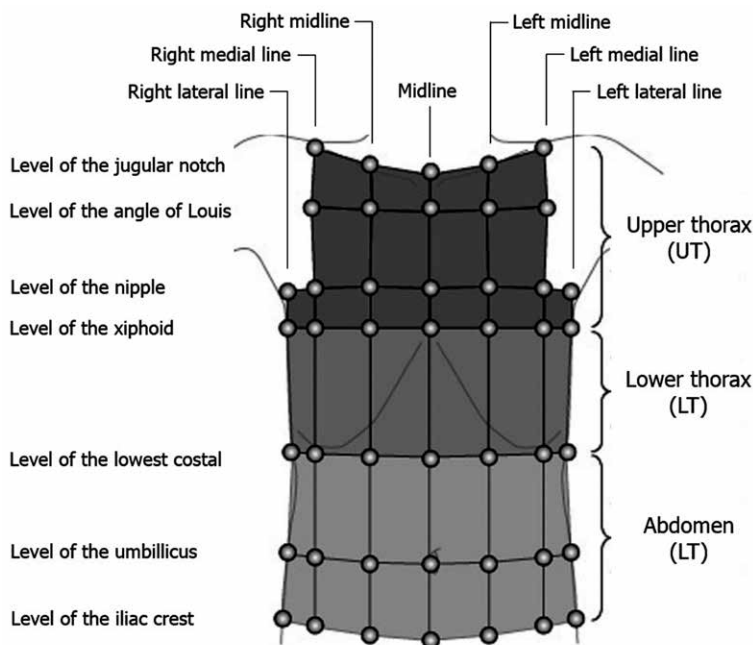


Fig. 1. Positions of the reflective markers on the chest wall.

would not be covered by the subject's body. The subject's shoulders were slightly abducted so the markers on the chest wall could be photographed using the cameras. The respiratory movements were recorded using an optoelectronic motion analysis system (VICON MX, Motion Capture Systems, Oxford, UK), with six infrared cameras placed around the subject. It was confirmed that all the markers could be photographed with the infrared cameras and checked on a PC so that the 3D coordinates would be obtained without loss.

Next, the subjects were given sufficient time to breathe naturally and instructed to perform a period of quiet breathing followed by a period of deep breathing, and to repeat this several times. For deep breathing, the procedure for measuring vital capacity with spirometry was as follows: the subjects were instructed to perform a series of at least three maximum inhalations and maximum exhalations. After data were recorded in the supine position, the trunk was raised to 30°, followed by

60° the same assessment being performed in each posture. The coordinate data were saved at 120-Hz sampling.

The suspension criteria were: (1) subject asked to stop, (2) subject complained of severe fatigue, and (3) an adverse event occurred.

Estimation of chest wall volumes

We placed 45 infrared reflective markers on the anterior and lateral surfaces of the chest and abdominal walls. Next, virtual markers were defined at points where lines dropped perpendicular to the bed from each marker on the chest wall intersected with a reference plane created by the four markers on the bed (Fig. 2). The volume of the total chest wall (V_{CW}) and the volume of each compartment were calculated from the markers' 3D coordinates using the methods of Ferrigno and Carnevali *et al.*²⁶⁾ and Wang *et al.*²⁷⁾. V_{CW} was divided into compartments as follows: volume of the upper thorax (V_{UT}), volume of the lower thorax (V_{LT}), and

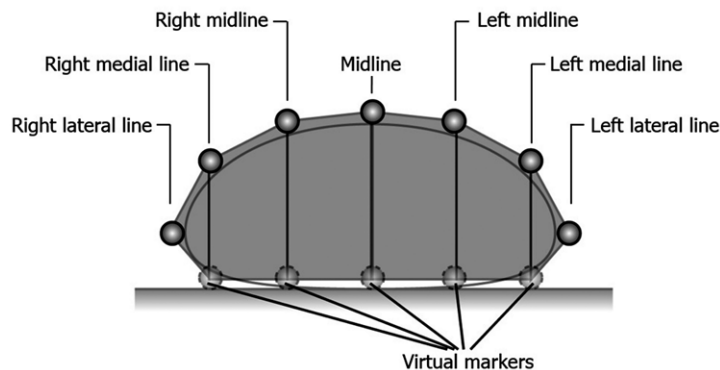


Fig. 2. Positions of virtual markers on the back inferior to the nipple level in a horizontal cross-section.

Virtual markers were defined as the points at which lines dropped perpendicular to the bed from the markers on the anterior and lateral surfaces of the chest wall intersected a reference plane created by four markers placed on the bed.

volume of the abdomen (V_{AB}). V_{UT} was the volume superior to the xiphoid process, V_{LT} was the volume from the xiphoid process to the lowest costal level, and V_{AB} was the volume inferior to the lowest costal level (Fig. 1). In other words, $V_{CW} = V_{UT} + V_{LT} + V_{AB}$.

Estimation of chest wall volume changes

Changes in volume during respiration were calculated from variations in the obtained chest wall volumes. The volume change of the total chest wall during quiet breathing [ΔV_{CW} (QB)] value was a mean of the volume calculated by subtracting end-expiratory from end-inspiratory volume with six consecutive breathing during quiet breaths taken. The volume change of the total chest wall during deep breathing [ΔV_{CW} (DB)] value was calculated by subtracting end-inspiratory volume minus end-expiratory volume during deep breathing with a mean of three deep breathing taken. The ΔV_{CW} (QB) value is equivalent to tidal volume during spirometry, while the ΔV_{CW} (DB) value is equivalent to vital capacity during spirometry. Differences in ΔV_{CW} (QB) and ΔV_{CW} (DB) were evaluated based on changes in posture and the presence or absence of disease.

The volume change corresponding to expiratory reserve volume by spirometry [ΔV_{CW} (ERV)] value

was end-expiratory reserve volume during quiet breathing minus end-expiratory reserve volume during deep breathing with a mean of three breaths taken. The ΔV_{CW} (ERV)/ ΔV_{CW} (DB) value was the ratio of ΔV_{CW} (DB) to ΔV_{CW} (ERV); differences therein were evaluated based on changes in posture and the presence or absence of disease.

Changes in volume for each compartment (V_{UT} , V_{LT} , V_{AB}) and V_{CW} during quiet and deep breathing were evaluated based on changes in posture and the presence or absence of disease, and compared between compartments.

Statistical analysis

Differences due to posture and differences among compartments were examined using one-way analysis of variance. When significant difference was obtained, the difference of average value was further analyzed using the Bonferroni post-hoc comparison. Differences due to the presence or absence of disease were examined using an unpaired t-test. The significance level was set at less than 5%. IBM SPSS® Statistics 21 (IBM Inc., Tokyo, Japan) was used for the analyses.

RESULTS

All the subjects in both the tetraplegic group of

Table 1. Characteristics of the tetraplegic patients and the control group

Study Group	Age (years)	Height (cm)	Weight (kg)	Neurological level
tetraplegics (n = 5)	42.0 ± 14.1	170.8 ± 5.2	61.8 ± 13.6	C4/C4/C5/C5/C8
control (n = 5)	44.0 ± 10.7	167.8 ± 1.9	68.1 ± 11.3	
p-Value	0.807	0.262	0.445	

All the presented values are means ± standard deviation. In the last line, the p-values of the comparison between tetraplegics and controls are shown. All the tetraplegic patients were classified as American Spinal Injury Association Impairment Scale (AIS) A. The sex of all the subjects in both groups was male.

five patients (age, 18–54 years; height, 164–178 cm; body weight, 47.3–81 kg; time from injury, 327–4,364 days) (Table. 1) and the control group of five healthy subjects (age, 29–55 years; height, 165–170 cm; weight, 53–75 kg) completed all the procedures. The final analysis was performed on all these subjects.

Effects of posture on volume changes of the total chest wall during quiet breathing

We compared volume changes of the total chest wall during quiet breathing [ΔV_{CW} (QB)] at each posture between the control and tetraplegic groups (Fig. 3).

The mean ΔV_{CW} (QB) in each posture differed significantly between the control and tetraplegic groups. Additionally, ΔV_{CW} (QB) increased in the control group as the posture became more upright; however, the differences were not significant. In the tetraplegic group, ΔV_{CW} (QB) was significantly greater at 30° than at 60°.

Effects of posture on volume changes of the total chest wall during deep breathing

The mean value of ΔV_{CW} (DB) at each posture differed significantly between the control and tetraplegic groups. Significant changes in ΔV_{CW} (DB) due to posture were not observed in the control group. In the tetraplegic group, however, ΔV_{CW} (DB) tended to decrease as the posture became more upright and was significantly greater at 0° than at 60° (Fig. 4).

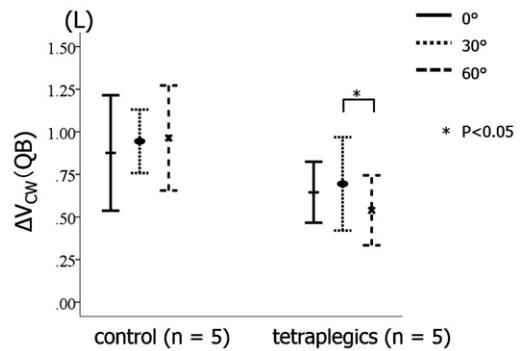


Fig. 3. Comparison of ΔV_{CW} (QB) due to posture between the control and tetraplegic groups.

Each bar indicates the standard deviation, and the center of bar indicates the mean. ΔV_{CW} (QB) expresses the change in chest wall volume during a period of quiet breathing that is equivalent to tidal volume by spirometry. The ΔV_{CW} (QB) value tended to increase in the control group as the trunk was raised, but the differences were not significant. In the tetraplegic group, ΔV_{CW} (QB) was significantly greater at 30° than at 60°. In the same posture, ΔV_{CW} (QB) was significantly lower in the tetraplegic group than in the control group.

Effects of posture on ΔV_{CW} (ERV)/ ΔV_{CW} (DB)

We compared ΔV_{CW} (ERV)/ ΔV_{CW} (DB) at each posture between the control and tetraplegic groups (Fig. 5). At the same postures, ΔV_{CW} (ERV)/ ΔV_{CW} (DB) tended to be lower in the tetraplegic group than in the control group, however no significant differences were observed. ΔV_{CW} (ERV)/ ΔV_{CW} (DB) tended to increase as the trunk was raised in both the control and tetraplegic groups, but the differences were not significant.

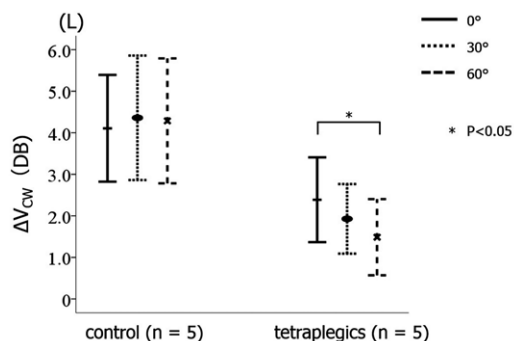


Fig. 4. Comparison of ΔV_{CW} (DB) due to posture between the control and tetraplegic groups.

Changes in ΔV_{CW} (DB) due to posture were not observed in the control group. Each bar indicates the standard deviation, and the center of each bar indicates the mean. In the tetraplegic group, ΔV_{CW} (DB) tended to decrease as the angle of the trunk increased, and it was significantly smaller at 60° than at 0°.

Effects of posture on each compartment volume during quiet breathing

We compared changes in each compartment volume during quiet breathing at each posture between the control and tetraplegic groups. In the control group, a significant difference was observed in volume change of the abdomen during quiet breathing [ΔV_{AB} (QB)] only between 30° and 60°. In the tetraplegic group, ΔV_{AB} (QB) and ΔV_{CW} (QB) decreased significantly as the trunk was raised from 30° to 60°. In both groups, ΔV_{AB} (QB) peaked at 30°. In the tetraplegic group, volume change of the upper thorax during quiet breathing [ΔV_{UT} (QB)] took negative values with all postures and the percentage that ΔV_{UT} (QB) comprised ΔV_{CW} (QB) went from -8.0% to -9.5% to -10.7% (mean \pm SD, $-9.4 \pm 1.4\%$) at 0°, 30°, and 60°, respectively. In the tetraplegic group, ΔV_{AB} (QB) comprised the largest proportion of ΔV_{CW} (QB), ranging from 92% to 106% to 108.9% (mean \pm SD, $102.3 \pm 9.0\%$) at 0°, 30°, and 60°, respectively (Fig. 6).

Effects of posture on each compartment volume during deep breathing

We compared changes in each compartment

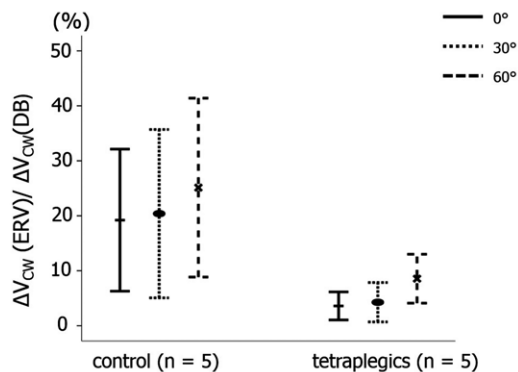


Fig. 5. The ΔV_{CW} (ERV) / ΔV_{CW} (DB) value was compared among postures between the control and tetraplegic groups.

Each bar indicates the standard deviation, and the center of each bar indicates the mean. ΔV_{CW} (ERV) / ΔV_{CW} (DB) is equivalent to expiratory reserve volume by spirometry. ΔV_{CW} (ERV) / ΔV_{CW} (DB) tended to increase as the trunk was raised in the control and tetraplegic groups, but the differences were not significant. At the same posture, ΔV_{CW} (ERV) / ΔV_{CW} (DB) tended to be lower in the tetraplegic group than in the control group, but no significant differences were observed.

volume during deep breaths at each posture in the control and tetraplegics group (Fig. 7). In all positions in the control group, volume change of the upper thorax (ΔV_{UT}) and volume change of the lower thorax (ΔV_{LT}) were greater during deep breathing than during quiet breathing. In the tetraplegic group, however, the paradoxical breathing that was seen during quiet breathing was not observed, although the movements of the chest wall were small. The percentage that volume change of the upper thorax during deep breathing [ΔV_{UT} (DB)] comprised ΔV_{CW} (DB) at 0°, 30°, and 60° in the tetraplegic group was 7%, 1.9%, and 8.4% (mean \pm SD, $5.8 \pm 3.5\%$) respectively, and in the control group was 25.4%, 20.5%, and 23.4% (mean \pm SD, $23.2 \pm 2.5\%$), respectively. In the tetraplegic group, volume change of the abdomen during deep breathing [ΔV_{AB} (DB)] gradually decreased as the inclination angle was increased from the supine position.

The ΔV_{CW} (DB) value, consisting most greatly of ΔV_{AB} (DB), also decreased as the inclination

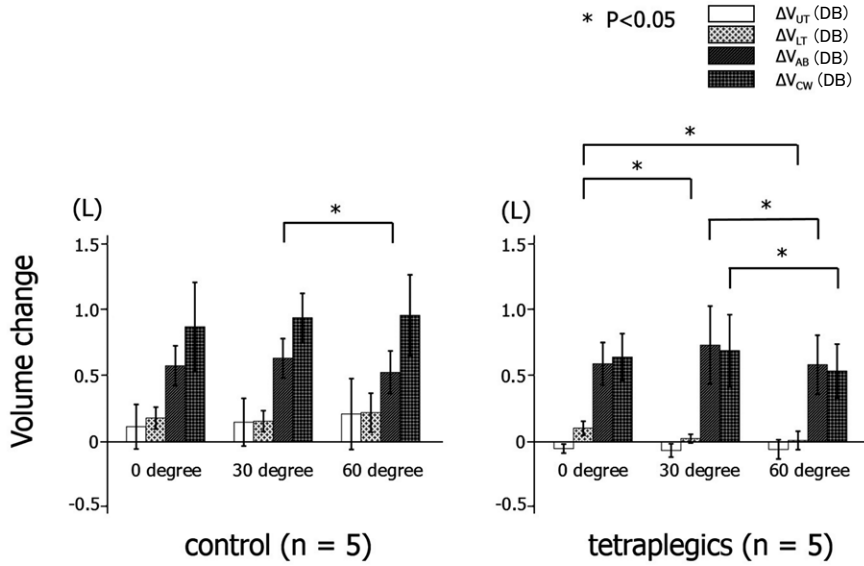


Fig. 6. ΔV_{CW} (QB) and changes in each compartment volume.

Volume change of the upper thorax during quiet breathing [ΔV_{UT} (QB)], volume change of the lower thorax during quiet breathing [ΔV_{LT} (QB)], volume change of the abdomen during quiet breathing [ΔV_{AB} (QB)], volume change of the total chest wall during quiet breathing [ΔV_{CW} (QB)]. In the control group, a significant difference was only observed for ΔV_{AB} (QB) between 30° and 60°. In the tetraplegic group, ΔV_{LT} (QB) at 0° was significantly different than at 30° and 60°, and ΔV_{AB} (QB) and ΔV_{CW} (QB) were significantly greater at 30° than at 60°.

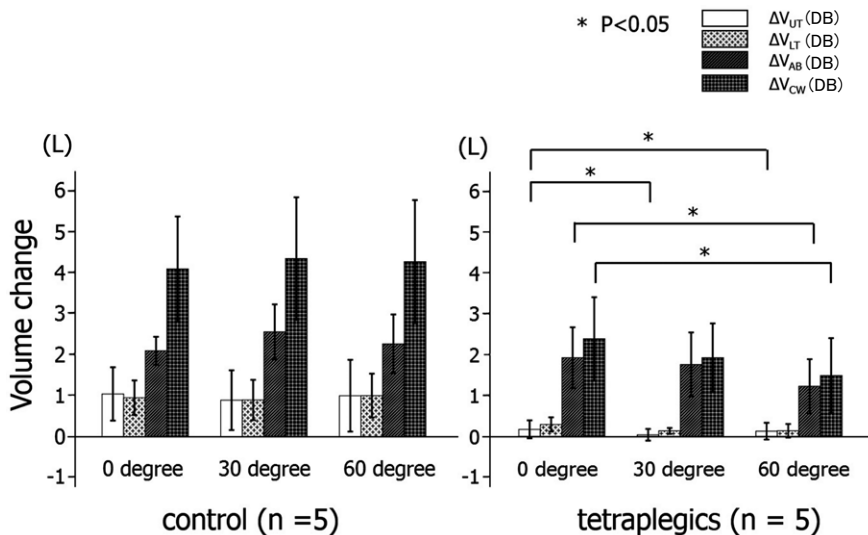


Fig. 7. ΔV_{CW} (DB) and changes in each compartment volume.

Volume change of the upper thorax during deep breathing [ΔV_{UT} (DB)], volume change of the lower thorax during deep breathing [ΔV_{LT} (DB)], volume change of the abdomen during deep breathing [ΔV_{AB} (DB)], volume change of the total chest wall during deep breathing [ΔV_{CW} (DB)]. No significant differences in ΔV_{CW} (DB) due to posture were observed in the control group. In the tetraplegic group, ΔV_{UT} (DB) at 0° was significantly different than at 30° and at 60°; ΔV_{AB} (DB) at 0° was significantly different than at 60°; and ΔV_{CW} (DB) at 0° was significantly different than at 60°. Both ΔV_{AB} (DB) and ΔV_{CW} (DB) decreased as trunk angle increased.

angle was raised. This accompanied the decrease in ΔV_{AB} (DB). The ΔV_{CW} (DB) value at 0°, 30°, and 60° was 2.4 ± 1.1 L, 1.9 ± 0.9 L, and 1.5 ± 1.0 L, respectively. The percentage that ΔV_{AB} (DB) comprised ΔV_{CW} (DB) at 0°, 30°, and 60° was 80.7%, 91.3%, and 82.4% (mean \pm SD, $84.8 \pm 5.7\%$), respectively.

DISCUSSION

Measurement method

In most of previous studies, markers were placed on the subject's chest wall including their back. However, since tetraplegic patients cannot maintain stability in the upright sitting position, we recorded data with the subjects' backs against a backrest. To account for the lack of markers on the subjects' backs, we created virtual markers and then calculated chest wall volume based on the coordinates of each marker. Wang *et al.*²⁷⁾ previously reported an assessment method using virtual markers, although their assessments were made only in the supine position. The advantage of this method is that OEP assessments are possible as long as the back is in contact with the backrest. This method is thought to allow assessments to be made of patients with reduced trunk muscle strength (for instance, patients with motor neuron diseases or muscular diseases such as muscular dystrophy). However, many of these patients exhibit issues (scoliosis, anterior inclination of the trunk, or posterior pelvic tilt) that can create a gap between the bed and the trunk, even when lying supine, and lead to error. Moreover, the lateral markers must be photographed without any loss, which means the shoulders must be maintained in an abducted position. If the subject lacks the strength required to do this, support is needed from armrests or an assistant; however, this may influence the respiratory movements. In the present study, the upper limbs were placed in a position (shoulders abducted about 30°) that allowed the cameras to photograph the lateral markers

without any loss, but raising the arms decreases upper thorax volume and increases lower thorax volume²⁸⁾, which may have affected the results.

Respiratory patterns in tetraplegics

The importance of diaphragm function in tetraplegic patients has been identified. In the present study, we were able to quantitatively assess the degree of diaphragm function using OEP. This showed that changes in rib cage volume composed a smaller proportion of respiration in tetraplegic patients compared to healthy people, a result also observed by Miccinilli *et al.*²⁴⁾ who reported that, in tetraplegic patients, the movements of the chest and abdomen are less synchronized in the supine position, making breathing less efficient in this position. In the present study, the tetraplegic patients exhibited a paradoxical breathing pattern, in which V_{UT} (QB) is lower at the end of inhalation than at the end of exhalation. Stone and Keltz¹⁾ reported that contraction of the diaphragm during inhalation displaced the anterosuperior thorax anteriorly during inhalation (paradoxical breathing) in the case of abdominal muscle paralysis in patients undergoing rehabilitation, which caused inefficient respiration. Because patients with acute-stage spinal cord injuries have flexible chest walls, they often exhibit the paradoxical breathing pattern even in deep breathing. However, later the chest moves only a small amount during respiration, reducing chest compliance, and abdominal muscle paralysis increases abdominal compliance²⁹⁾. In addition, the subject (*or* patient) may have spasticity of the chest wall muscles. Thus, these factors may influence breathing patterns in the chronic disease stage. It is suggested in this study that paradoxical respiration is present in the chronic phase at least during quiet breathing.

Stone and Keltz¹⁾ found that paralysis of the expiratory intercostal muscles and abdominal muscles due to spinal cord injury greatly decreased

expiratory reserve volume (ERV) and increased residual volume (RV) due to lower forced expiratory capacity. $\Delta V_{CW} (ERV) / \Delta V_{CW} (DB)$ served as an indicator of the percentage that expiratory effort occupied among the factors causing decreased vital capacity. In the present study as well, ΔV_{CW} was lower in spinal cord injury patients than in healthy people, and $\Delta V_{CW} (ERV) / \Delta V_{CW} (DB)$ was also lower but not significant. It was expected that $\Delta V_{CW} (ERV) / \Delta V_{CW}$ would decrease because abdominal and intercostal muscle paralysis in tetraplegics makes effort expiration difficult. However, because there is a considerable difference in the average value, it seems possible that the number of cases was insufficient, and further study is necessary.

Effects of posture

The results of the current study show that the volume change was larger both in the chest and abdomen in supine position. It seemed that, considering the possibility that the difference in posture affects the load amount in respiratory muscle strengthening and exercise loading, we should pay attention to exercise posture when we plan exercise protocol in such patients.

A previous study by Miccinilli *et al.*²⁴⁾ assessed subjects in two positions (supine and sitting in a wheelchair), whereas the present study evaluated three trunk angles (0°, 30°, 60°). Another study by Romei *et al.*³⁰⁾ found that when the trunk angle of healthy women was increased from supine to a reclining sitting position, the proportion of the abdomen that comprised the ventilatory volume of a breath decreased significantly, although no significant difference was observed in healthy men. They also found that respiration in the sitting position was influenced by the presence or absence of a backrest. In the present study, all assessments were performed using a backrest.

Past studies found that, in healthy people, chest movements comprise a relatively large percentage

during respiration in the standing and sitting positions compared with the supine position, while the abdomen makes up a relatively small percentage^{15, 16)}.

In tetraplegic patients, volume change of the lower thorax during quiet breathing [$\Delta V_{LT} (QB)$] decreased as the posture became upright, although $\Delta V_{UT} (QB)$ was a negative value consistently and was not influenced by posture. Abdominal content creates pressure on the diaphragm in the supine position; however, in the upright position it does not, making the diaphragm work more efficiently. This phenomenon makes the rib cage be pulled up to the cranial direction, so it is considered that there is little movement in the supine position in tetraplegics.

During deep breathing, the accessory breathing muscles seemed to work because $\Delta V_{UT} (DB)$ no longer had a negative value. In this situation, it seems that movement of the diaphragm directly affected $\Delta V_{CW} (DB)$.

A study by Agostoni *et al.*¹⁹⁾ reported that abdominal compliance increased in the supine position even in healthy people. Goldman *et al.*²⁹⁾ reported that, in the supine position, abdominal wall compliance was 77% higher in spinal cord injury patients than in healthy people. These findings help substantiate the increase in volume change of the abdomen (ΔV_{AB}) that we observed in the supine position.

CONCLUSION

In the present study, we performed a motion analysis using OEP to evaluate the effects of posture on the breathing pattern of patients with complete spinal cord injuries. During quiet breathing, spinal cord injury patients exhibited paradoxical movements of the upper thorax and abdominal movements made up the greatest percentage of respiratory movement. During deep breathing, tetraplegic also exhibited a breathing pattern that

relied on abdominal movements, and the change in chest wall volume during deep breathing was greatest in the supine position.

ACKNOWLEDGMENTS

The authors thank Dr. Akihiro Tokuhiko (Kibikogen Rehabilitation Center for Employment Injuries), Mr. Yasuhiko Rokumyo and Mr. Kuniharu Nanba (rehabilitation engineers, Kibikogen Rehabilitation Center for Employment Injuries), and Mr. Toshihiro Fujii (physical therapist, Kibikogen Rehabilitation Center for Employment Injuries) for their assistance. This work was supported by JSPS KAKENHI Grants Numbers 24500613, 15K01403.

CONFLICTS OF INTEREST

The authors have no conflicts of interest to disclose.

REFERENCES

- 1) Stone DJ, Keltz H: The effect of respiratory muscle dysfunction on pulmonary function. *Studies in patients with spinal cord injuries. Am Rev Respir Dis* 88: 621-629, 1963
- 2) Linn WS, Spungen AM, Gong H Jr, Adkins RH, Bauman WA, Waters RL: Forced vital capacity in two large outpatient populations with chronic spinal cord injury. *Spinal Cord* 39: 263-268, 2001
- 3) Almenoff PL, Spungen AM, Lesser M, Bauman WA: Pulmonary function survey in spinal cord injury: influences of smoking and level and completeness of injury. *Lung* 173: 297-306, 1995
- 4) Linn WS, Adkins RH, Gong H, Waters RL: Pulmonary function in chronic spinal cord injury: a cross-sectional survey of 222 southern California adult outpatients. *Arch Phys Med Rehabil* 81: 757-763, 2000
- 5) Hartkopp A, Hansen HB, Seidenschnur AM, Sørensen FB: Survival and cause of death after traumatic spinal cord injury. A long-term epidemiological survey from Denmark. *Spinal Cord* 35: 76-85, 1997
- 6) McKinley WO, Jackson AB, Cardenas DD, DeVivo MJ: Long-term medical complications after traumatic spinal cord injury: a regional model systems analysis. *Arch Phys Med Rehabil* 80: 1402-1410, 1999
- 7) Frankel HL, Coll JR, Charlifue SW, Whiteneck GG, Gardner BP, Jamous MA, Krishnan KR, Nuseibeh I, Savic G, Sett P: Long-term survival in spinal cord injury: a fifty-year investigation. *Spinal Cord* 36: 266-274, 1998
- 8) Scanlon PD, Loring SH, Pichurko BM, McCool FD, Slutsky AS, Sarkarati M, Brown R: Respiratory mechanics in acute quadriplegia: Lung and chest wall compliance and dimensional changes during respiratory maneuvers. *Am Rev Respir Dis* 139: 615-620, 1989
- 9) Estenne M, De Troyer A: Relationship between respiratory muscle electromyogram and rib cage motion in tetraplegia. *Am Rev Respir* 132: 53-59, 1985
- 10) De Troyer A, Estenne M, Vincken W: Rib cage motion and muscle use in high tetraplegics. *Am Rev Respir* 133: 1115-1119, 1986
- 11) Urmey W, Loring S, Mead J, Slutsky AS, Sarkarati M, Rossier A, Brown R: Upper and lower rib cage deformation during breathing in quadriplegics. *J Appl Physiol* 60: 618-622, 1986
- 12) Mortola JP, Sant' Ambrogio G: Motion of the rib cage and the abdomen in tetraplegic patients. *Clin Sci Mol Med* 54: 25-32, 1978
- 13) Manning H, McCool FD, Scharf SM, Garshick E, Brown R: Oxygen cost of resistive-loaded breathing in quadriplegia. *J Appl Physiol* 73: 825-831, 1992
- 14) Cala SJ, Kenyon CM, Ferrigno G, Carnevali P, Aliverti A, Pedotti A, Macklem PT, Rochester DF: Chest wall and lung volume estimation by optical reflectance motion analysis: *J Appl Physiol* 81: 2680-2689, 1996
- 15) Aliverti A, Stevension N, Dellacà RL, Lo Mauro A, Pedotti A, Calverley PM: Regional chest wall volumes during exercise in chronic obstructive pulmonary disease. *Thorax* 59: 210-216, 2004
- 16) Vogiatzis I, Georgiadou O, Golemati S, *et al.*: Patterns of dynamic hyperinflation during exercise and recovery in patients with severe chronic obstructive pulmonary disease. *Thorax* 60: 723-729, 2005
- 17) Sharp JT, Goldberg NB, Druz WS, Danon J: Relative contributions of rib cage and abdomen to breathing in normal subjects. *J Appl Physiol* 39: 608-618, 1975
- 18) Verschakelen JA, Demedts MG: Normal thoracoabdominal motion, influence of sex, age, posture, and breath size. *Am J Respir Crit Care Med* 151: 399-405, 1995
- 19) Agostoni E, Rahn H: Abdominal and thoracic pressures at different lung volumes. *J Appl Physiol* 15: 1087-1092, 1960
- 20) Romagnoli I, Gigliotti F, Galarducci A, Lanini B, Bianchi R, Cammelli D, Scano G: Chest wall kinematics and respiratory muscle action in ankylosing spondylitis

- patients. *Eur Respir J* 24: 453-460, 2004
- 21) Filippelli M, Duranti R, Gigliotti F, Bianchi R, Grazzini M, Stendardi L, Scano G: Overall contribution of chest wall hyperinflation to breathlessness in asthma. *Chest* 124: 2164-2170, 2003
 - 22) Lanini B, Bianchi R, Romagnoli I, Coli C, Binazzi B, Gigliotti F, Pizzi A, Grippo A, Scano G: Chest wall kinematics in patients with hemiplegia. *Am J Respir Crit Care Med* 168: 109-113, 2003
 - 23) Redlinger RE Jr, Kelly RE, Nuss D, Goretsky M, Kuhn MA, Sullivan K, Wootton AE, Ebel A, Obermeyer RJ: Regional chest wall motion dysfunction in patients with pectus excavatum demonstrated via optoelectronic plethysmography. *J Pediatr Surg* 46: 1172-1176, 2011
 - 24) Miccinilli S, Morrone M, Bastianini F, Molinari M, Scivoletto G, Silvestri S, Ranieri F, Sterzi S: Optoelectronic plethysmography to evaluate the effect of posture on breathing kinematics in spinal cord injury: a cross sectional study. *Eur J Phys Rehabil Med* 52: 36-47, 2016
 - 25) Bach JR, Mehta AD: Respiratory muscle aids to avert respiratory failure and tracheostomy: a new patient management paradigm. *Journal of Neurorestoratology* 2: 25-35, 2014
 - 26) Ferrigno G, Carnevali P: Principal component analysis of chest wall movement in selected pathologies. *Med Biol Eng Comput* 36: 445-451, 1998
 - 27) Wang HK, Lu TW, Liing RJ, Shih TTF, Chen SC, Lin KH: Relationship between chest wall motion and diaphragmatic excursion in healthy adults in supine position. *J Formos Med Assoc* 108: 577-586, 2009
 - 28) Romagnoli I, Gigliotti F, Lanini B, Bruni GI, Coli C, Binazzi B, Stendardi L, Scano G: Chest wall kinematics and breathlessness during unsupported arm exercise in COPD patients. *Respir Physiol Neurobiol* 178: 242-249, 2011
 - 29) Goldman JM, Rose LS, Morgan MD, Denison DM: Measurement of abdominal wall compliance in normal subjects and tetraplegic patients. *Thorax* 41: 513-518, 1986
 - 30) Romei M, Mauro A, Angelo MG, Turconi AC, Bresolin N, Pedotti A, Aliverti A: Effects of gender and posture on thoraco-abdominal kinematics during quiet breathing in healthy adults. *Respir Physiol Neurobiol* 172: 184-191, 2010

