

〈Regular Article〉

## Changes in sagittal spino-pelvic alignment after total hip arthroplasty using the Roussouly classification

Shuro FURUICHI<sup>1)</sup>, Takayuki KURODA<sup>2)</sup>, Shigeru MITANI<sup>1)</sup>,  
Yoshifumi NANBA<sup>1)</sup>, Toyohiro KAWAMOTO<sup>1)</sup>, Norifumi UMEHARA<sup>1)</sup>

1) Department of Bone and Joint Surgery, Kawasaki Medical School,  
577 Matsushima, Kurashiki, 701-0192, Japan

2) Department of Orthopedic Surgery, Okayama Medical Center,  
1711-1 Tamasu, Kita-ku, Okayama, 701-1192, Japan

**ABSTRACT** Pelvic inclination changes after total hip arthroplasty; we determined how sagittal spino-pelvic alignment changed after total hip arthroplasty. We investigated the change in Roussouly classification type and sagittal spino-pelvic alignment after total hip arthroplasty. Sagittal spino-pelvic alignment was investigated in 135 patients who underwent total hip arthroplasty. Prior to surgery, there were 50 cases (37%) of Type 1 and 2, 53 cases (39.3%) of Type 3, and 32 cases (23.7%) of Type 4. Since none of the Type 1 and 2 cases showed postoperative changes, we divided the Type 3 and Type 4 cases into 3 groups. Cases with pelvic retroversion and reduced lumbar lordosis before total hip arthroplasty showed no change. Half of the cases with satisfactory preoperative sagittal spino-pelvic alignment (SSPA) remained Type 3 with lumbar lordosis even after surgery. However, even in satisfactory Type 3 cases, if there was pelvic retroversion after total hip arthroplasty (THA) surgery, they were reclassified as Type 1 or 2 due to reduced lumbar lordosis and changes in SSPA. Cases of Type 4 with preoperative pelvic anteversion were reclassified as Type 3 after surgery due to a major reduction in the sacral slope angle and changes in SSPA.

doi:10.11482/KMJ-E42(2)57 (Accepted on October 19, 2016)

Key words : Hip-spine syndrome, Total hip arthroplasty, Osteoarthritis of hip, Roussouly classification, Spino-pelvic alignment

### INTRODUCTION

Patients with hip osteoarthritis (hip OA) often complain of lumbar pain along with hip pain, and spinal disease may also be present<sup>1, 2)</sup>. Palvizi *et al.* reported that 49.4% of hip OA patients present with lumbar pain were existed<sup>1)</sup>, whereas Provan

*et al.* reported a high frequency of lumbar pain and sciatica as complications in hip OA patients<sup>2)</sup>. Offierski and MacNab proposed a relationship between the hip and spine in such conditions, which was termed as hip-spine syndrome<sup>3)</sup>. Hip OA and spinal disease are now widely recognized to be very

Corresponding author  
Shuro Furuichi  
Department of Bone and Joint Surgery, Kawasaki  
Medical School, 577 Matsushima, Kurashiki, 701-0192,  
Japan

Phone : 81 86 462 1111  
Fax : 81 86 464 1184  
E-mail: [rwjnf672@yahoo.co.jp](mailto:rwjnf672@yahoo.co.jp)

closely related.

Hip-spine syndrome is broadly divided into two types, including one type wherein hip OA induces contracture of the hip joint, anteversion of the pelvis, and an increase in lordosis, as well as another type wherein retroversion of the pelvis and a decrease in lordosis due to lumbar degeneration reduces the anterior covering of the hip, and causes progression of hip OA<sup>3)</sup>. Moreover, the sagittal alignment differs between these two hip OA Types. Lumbar pain reportedly improves following total hip arthroplasty (THA) for end-stage hip OA<sup>1, 4)</sup>. Hence, it is likely that THA alters pelvic alignment and thereby alters the sagittal alignment of the spine.

The recent increase in the use of sagittal spino-pelvic alignment (SSPA) evaluation has resulted in increased interest in ascertaining the pathologies underlying spinal deformities and degenerative diseases and in assessing the treatment results<sup>5)</sup>. SSPA evaluation is considered to be useful for assessing sagittal alignment before and after THA. The widely used parameters for assessing SSPA include pelvic incidence (PI) and sacral slope (SS). PI is not dependent on posture and is an individual-specific angle that remains constant<sup>5, 6)</sup>. SS represents the anteversion/retroversion of the pelvis, through an angle formed by S1 (first sacral vertebra) and the horizontal plane<sup>7)</sup> (Fig. 1).

Roussouly *et al.* measured the SSPA of volunteers, classified them into four Types based on their PI and SS values, and examined the association between these types and spinal disease. The Type 1 and Type 2 groups, which had a low PI and an SS of  $<35^\circ$ , exhibited a higher risk of intervertebral disc disease. Type 3, which had a high PI and an SS of  $>35^\circ$  but  $<45^\circ$ , was considered as normal. The Type 4 group, which had an even higher PI and an SS of  $>45^\circ$ , exhibited a higher risk of lumbar spondylolisthesis<sup>8)</sup> (Fig. 2).

Pelvic inclination reportedly changes after

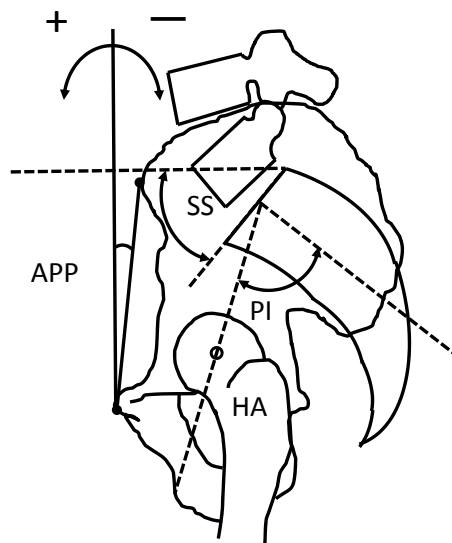


Fig. 1. Measurement of the anterior pelvic plane (APP). The APP is the angle formed by a vertical line from the pubic symphysis and the mid-point between the two anterior superior iliac spines. Pelvic incidence is regarded as the angle between the line connecting the hip axis and the midpoint of the superior endplate of S1. The sacral slope (SS) is regarded as the angle between the superior endplate of S1 and the horizontal plane.

THA<sup>9-11)</sup>. The pelvis is coupled with the sacrum at the sacroiliac joints, and hence, when pelvic inclination changes after THA, it is expected that the sacral inclination would also change, along with the SS. Moreover, if pelvic anteversion is noted after THA, the SS would increase. In contrast, if retroversion is noted after THA, the SS would decrease (Fig. 3). Thus, it is possible to hypothesize that the Roussouly classification types may differ or change before and after THA, thus also resulting in a change in the SSPA. In the present study, we aimed to investigate the manner in which SSPA changes before and after THA in hip OA patients using the Roussouly classification, and to clarify the manner in which SSPA is affected after THA.

## SUBJECTS AND METHODS

This study was a retrospective case-control study. In total, 135 patients with hip OA underwent THA

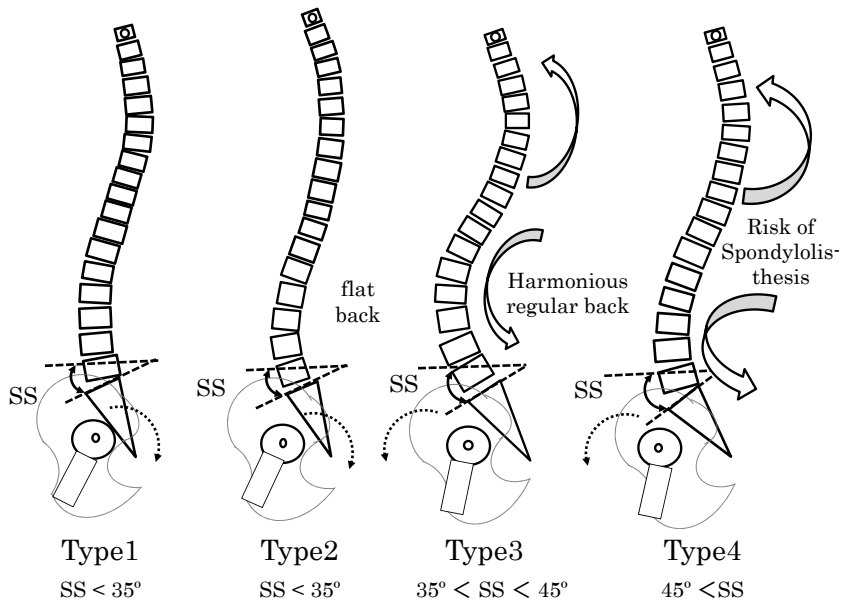


Fig. 2. Roussouly classification. A four-part classification of morphology was used to classify each patient.

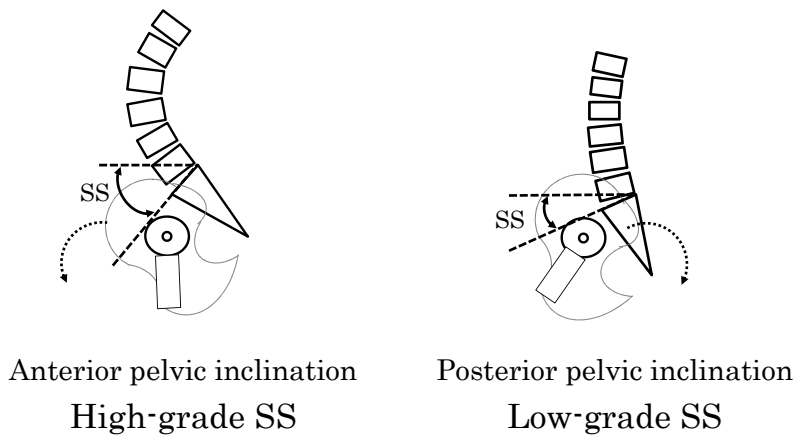


Fig. 3. Relationship between sacral slope (SS) and pelvic inclination. Patients with a high SS are assumed to have anterior pelvic inclination, whereas those with a low SS are assumed to have posterior pelvic inclination.

at Kawasaki Medical School Hospital, including 13 males and 122 females with a mean age at the time of surgery of  $66 \pm 9.4$  years (mean  $\pm$  standard deviation). Only cases with an extent of dislocation classified as groups I and II, according to the Crowe classification, were included<sup>12)</sup>. Cases with greater dislocation (groups III and IV according to the Crowe classification<sup>12)</sup>), as well as cases of trauma and those with a history of osteotomy were excluded. The affected side was unilateral in 106 cases and bilateral in 29 cases. In general, primary THA is more commonly performed in women than in men, except in cases with avascular necrosis of the femoral head; the fact that there were more women than men in the present study appears promising as it represents this trend.

Total spine lateral and pelvic lateral radiographs were obtained in the standing position using plain radiography before surgery and 12 months after surgery. While imaging was performed, the patient was asked to gently hold onto a bar in the front, so that the natural standing position could be highly reproducible. Cases with bilateral disease underwent imaging on both sides before surgery and at 12 months after bilateral THA.

The measurement parameters included standing anterior pelvic plane (APP),  $SS^7)$ , lumbar-lordosis (LL)<sup>13)</sup>. APP represented the angle formed by a vertical line and a line connecting the pubic symphysis and the bilateral anterior superior iliac spine midpoint<sup>14)</sup>; it was considered to be positive and to represent pelvic anteversion when the anterior superior iliac spine was located anteriorly to the pubic symphysis, and considered to be negative and to represent retroversion when it was located posteriorly to the pubic symphysis (Fig. 1). For the APP, we investigated the amount of change between the APP before THA and that at 1 year after THA, described as  $\Delta APP$ . LL represents lordosis, and was measured as the angle formed by the superior endpoint of L1 (first lumbar vertebra) and the

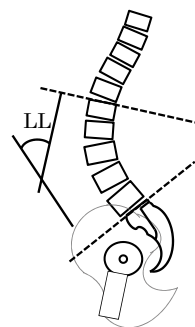


Fig. 4. Sagittal spino-pelvic alignment: Lumbar lordosis (LL) represents lordosis.

superior endpoint of S1<sup>13)</sup> (Fig.4). Since none of the Type 1 and 2 cases showed postoperative changes, we divided the Type 3 and Type 4 cases into three groups. Next, we examined whether the Roussouly classification changed at 1 year after THA, and compared the preoperative measurement parameters between those with or without altered Roussouly classifications among each group described above.

Statistical analysis was performed using Stat Mate III (ATMS, Tokyo, Japan). All data were expressed as mean  $\pm$  standard deviation. Student's t-test was used to compare each parameter among the four groups. Moreover, 95% exact confidence intervals were calculated, and a statistically significant difference was defined as a p value of  $<0.05$ .

## RESULTS

All the measurement parameters were presented as mean  $\pm$  SD. The mean preoperative APP in all the cases was  $2.4 \pm 10.2^\circ$ , whereas the mean  $\Delta APP$  was  $-5.3 \pm 9.4^\circ$ . Among the cases that underwent preoperative Roussouly classification, 25 were classified as Type 1 and 25 cases were classified as Type 2 (total, 50 cases; 37%), 53 cases (39.3%) were classified as Type 3, and 32 cases (23.7%) were classified as Type 4. Since the difference of Type 1 and Type 2 is only presence of flat back in Type 2 and SS in both types are the same as less than  $35^\circ$ , Type 1 and 2 were mixed as Type 1/2

for further analyses, In Types 1/2, 3, and 4, the SS values were  $28.6 \pm 5.1^\circ$ ,  $38.9 \pm 4.8^\circ$ , and  $49.8 \pm 6.3^\circ$ , respectively. Moreover, in Types 1/2, 3, and 4, the mean age was  $67.4 \pm 9.9$  years,  $65.3 \pm 8.8$  years, and  $66.2 \pm 9.3$  years, respectively; no significant difference in any of the above-mentioned parameters was noted among the three types.

With regard to the preoperative measurement parameters, the APP in Types 1/2, 3, and 4 were  $-1.0 \pm 9.3^\circ$ ,  $3.6 \pm 9.9^\circ$ , and  $5.5 \pm 10.8^\circ$ , respectively. In particular, Types 1/2 showed significant pelvic retroversion as compared to Types 3 and 4.

In Types 1/2, 3, and 4, the LL was found to be  $38.8 \pm 13.3^\circ$ ,  $52.2 \pm 9.3^\circ$ , and  $58.5 \pm 8.9^\circ$ , respectively; Types 1/2 exhibited significantly lesser lordosis of the lumbar spine as compared to Types 3 and 4. In particular, Type 4 exhibited a significantly greater lordosis of the lumbar spine, as compared to Type 3 (Table 1).

With regard to the change in Roussouly classification before and after THA, patients in the Type 1/2 did not show any change (Fig. 5). In this type, the mean postoperative APP was  $-6.3 \pm 11.3^\circ$ , and the  $\Delta$ APP was  $-5.3 \pm 8.2^\circ$ , which indicates retroversion of the pelvis compared to that before surgery.

Furthermore, in Type 3, 29 patients did not show any change in the Roussouly classification before and after THA; these patients were included in group A. However, 16 patients classified as Type 3 preoperatively showed a change to Type 1 or 2, and were assigned to group B, whereas 8 patients classified as Type 3 preoperatively showed a change

to Type 4, and were assigned to group C (Fig. 5). In groups A, B, and C, the mean APP value was  $3.9 \pm 11.7^\circ$ ,  $4.2 \pm 7.9^\circ$ , and  $1.4 \pm 6.3^\circ$ , whereas the  $\Delta$ APP was  $-4.4 \pm 9.3^\circ$ ,  $-7.6 \pm 1.4^\circ$ , and  $-0.5 \pm 2.9^\circ$ , respectively. Group B exhibited significantly greater retroversion than group C. In groups A, B, and C, the mean SS values were  $39.2 \pm 3.2^\circ$ ,  $37.3 \pm 7.2^\circ$ , and  $40.9 \pm 2.9^\circ$ , respectively; no significant difference was noted among the groups. Moreover, the mean LL value was  $53.3 \pm 8.1^\circ$ ,  $46.8 \pm 7.7^\circ$ , and  $58.4 \pm 11.9^\circ$  in groups A, B, and C, respectively; the LL in group B was significantly greater than that in groups A and C, where the lordosis was reduced (Table 2). Among the patients classified as Type 4 preoperatively, 13 did not show any change in the classification at 1 year after THA, and were assigned to group D; 6 patients showed a change in the classification to Type 1 or 2, and were assigned to group E, whereas 13 patients showed a change in the classification to Type 3 and were assigned to group F (Fig. 5). The APP value was 9.1

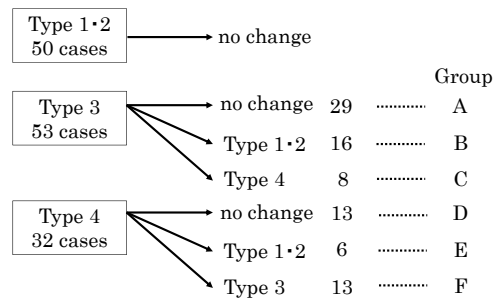


Fig. 5. Proportion of each Roussouly classification type before surgery and at 1 year after total hip arthroplasty.

Table 1. Pre-operative results for all radiographic measurements according to the Roussouly classification.

Type	1/2 n = 50	p value 1/2 vs 3	3 n = 53	p value 3 vs 4	4 n = 32	p value 4 vs 1/2
APP	$-1.0 \pm 9.3$	*0.015	$3.6 \pm 9.9$		$5.5 \pm 10.8$	*0.006
SS	$28.6 \pm 5.1$	*0.0001	$38.9 \pm 4.8$	*0.0001	$49.8 \pm 6.3$	*0.0001
LL	$38.8 \pm 13.3$	*0.0001	$52.2 \pm 9.3$	*0.0003	$58.5 \pm 8.9$	*0.0001

All data are presented as mean  $\pm$  standard deviation  
\*P < 0.05, Student's t-test

Table 2. Pre-operative results of groups A, B, and C for all radiographic measurements in patients classified as Type 3 according to the Roussouly classification.

Group	group A n = 29	p value A vs B	group B n = 16	p value B vs C	group C n = 8	p value C vs A
APP	3.9 ± 11.7		4.2 ± 7.9		1.4 ± 6.3	
∠APP	-4.4 ± 9.3		-7.6 ± 1.4	*0.009	-0.5 ± 2.9	
SS	39.2 ± 3.2		37.3 ± 7.2		40.4 ± 2.9	
LL	53.3 ± 8.1	*0.012	46.8 ± 7.7	*0.009	58.4 ± 11.9	

All data are presented as mean ± standard deviation

\*P < 0.05, Student's t-test

Table 3. Pre-operative results of groups D, E, and F for all radiographic measurements in patients classified as Type 4 according to the Roussouly classification.

Group	group D n = 13	p value D vs E	group E n = 6	p value E vs F	group F n = 13	p value F vs D
APP	9.1 ± 3.6		3.6 ± 13.2		2.8 ± 10.0	
∠APP	-0.5 ± 3.6		-10.4 ± 11.9		-9.9 ± 10.8	
SS	50.2 ± 7.9		48.2 ± 4.4		50.1 ± 5.4	
LL	58.6 ± 11.1		54.2 ± 6.2		60.3 ± 7.4	

All data are presented as mean ± standard deviation

\*P < 0.05, Student's t-test

± 3.6°, 3.6 ± 13.2°, and 2.8 ± 10.0° in groups D, E, and F, respectively; group D had significantly more anteversion than groups E and F, although the difference was not significant. Moreover, the ∠APP value was -0.5 ± 3.6°, -10.4 ± 11.9°, and -9.9 ± 10.8° in groups D, E, and F, respectively; group F showed a significantly greater amount of change than group D. In groups D, E, and F, respectively, the SS value was 50.3 ± 7.9°, 48.2 ± 4.4°, and 50.1 ± 5.4°; the LL value was 58.6 ± 11.1°, 54.2 ± 6.2°, and 60.3 ± 7.4° (Table 3).

## DISCUSSION

In the present study, we assessed whether the Roussouly classification types changed after THA in patients with hip OA. THA surgery reportedly results in a change in pelvic inclination, along with retroversion at 1 year after THA<sup>9-11)</sup>. In the present study, we also observed retroversion at 1 year after THA, consistent with past reports. Hip OA often involves pelvic anteversion, because of increased coverage of the femoral head or flexion contracture of the hip joint. THA improves the flexion

contracture, and thus results in pelvic retroversion. Ishida *et al.* reported that a greater amount of preoperative anteversion indicated a greater amount of postoperative retroversion; however, if the cases had retroversion preoperatively, no significant change would be noted. The patients who were classified as Roussouly Type 4 before THA had considerable SS and had pelvic anteversion, and therefore, major pelvic retroversion after THA may be expected to reduce the SS values and improve the SSPA.

Few reports have described the changes in SSPA before and after THA surgery. Kristen *et al.* compared the SS values before surgery and at 9 months after surgery in 12 cases of THA, and reported that no significant change occurred<sup>15)</sup>. Ben-Galim *et al.* compared the sacral inclination before surgery and at 2 years after THA in 25 cases of THA, and reported that no significant change was noted<sup>4)</sup>. However, both these studies had a small sample size, and no studies with a large sample size have been reported. Hip OA may include conditions of preoperative pelvic anteversion and conditions of

retroversion, and there may also have been variance in the SS values. In these reports, possible reasons for the lack of change in SSPA may be the small sample size and the fact that cases with high and low preoperative SS were considered together. In the present study, the Roussouly classification was used to indicate the preoperative SSPA status. We examined patients separately depending on whether they had pelvic anteversion or retroversion.

With regard to SS in hip OA, Ben-Galim *et al.* reported a value of  $39^\circ$  in 25 cases<sup>4)</sup>, whereas Okuda *et al.* reported a value of  $42.3^\circ$  in 26 cases<sup>16)</sup>. Okuda *et al.* reported that the SS value was  $32.6^\circ$  among healthy volunteers with matched ages, and that patients with hip OA had a significantly greater SS<sup>17)</sup>. The SS in hip OA may be greater than that in healthy volunteers because pelvic anteversion is commonly noted. Araújo *et al.* classified 489 volunteers without spinal disorders according to the Roussouly classification, and reported incidences of 36.2%, 42.3%, and 21.5% for Types 1/2, 3, and 4, respectively<sup>18)</sup>, whereas Chaléat-Valayer *et al.* reported incidences of 27.8%, 47.7%, and 24.5%, respectively, in a similar analysis of 709 patients<sup>18)</sup>. In the present study, the incidence of Types 1/2, 3, and 4 preoperatively were 37.0%, 39.3%, and 23.7%, respectively. Based on previous reports, it was expected that a greater proportion of patients would be grouped as Type 3 or 4 with a high SS; however, the proportions were similar to those in healthy volunteers. In 149 cases before THA, Ishida *et al.* reported that 56% had pelvic anteversion and 44% had pelvic retroversion<sup>9)</sup>. In hip OA, several cases of pelvic anteversion are noted, whereas cases with pelvic retroversion due to aging (and other such causes) comprise approximately 40% of patients. In cases of pelvic retroversion, a Roussouly classification Type 1 or 2 is more often observed, and therefore, in the present study, the number of patients with Type 1 and 2 were higher than expected (37%).

#### *Roussouly classification changes in patients preoperatively classified as Type 1 and 2*

Fifty patients classified as Type 1 or 2 before THA did not show any change in the classification type after THA. In cases with pelvic retroversion, no significant anteversion was noted after THA, and only a minimal change in pelvic inclination was noted<sup>9)</sup>. We believe that this is a reason for the lack of change in classification Type. The Type 1 and 2 had a significantly lower APP and LL than the Type 3 and 4; moreover, the patients in Type 1 and 2 had retroversion of the pelvis and reduced lumbar lordosis. Cases with preoperative pelvic retroversion and reduced lumbar lordosis did not exhibit any change in SSPA despite undergoing THA.

#### *Roussouly classification changes in patients preoperatively classified as Type 3*

Among the 53 cases preoperatively classified as Type 3, the proportion of patients in group A (no change in type after surgery) was highest (55%) and showed favourable SSPA; the other 45% had a change in SSPA. In contrast to the  $\Delta$  APP of group A ( $-4.4^\circ$ ), the pelvic retroversion in group B was greater ( $-7.6^\circ$ ), and these patients showed a change in classification type. Moreover, group B had a significantly lower LL value and reduced lordosis as compared to group A. Taki *et al.* also reported on the pelvic inclination after THA, and indicated a mean retroversion of  $3.9^\circ$  at 1 year and  $6.5^\circ$  at 4 years; they stated that retroversion continued to progress beyond 1 year after THA<sup>10)</sup>. Although the classification type changed to Type 4 at 1 year after surgery, an improvement in flexion contracture may have occurred over time, which may have reduced the pelvic anteversion and revised the SSPA to Type 3.

#### *Roussouly classification changes in patients preoperatively classified as Type 4*

Among 32 cases preoperatively classified as

Type 4, 13 patients (41%) showed a change in classification to Type 3 with SSPA. The present study indicated that pelvic retroversion following THA caused a change from Type 4 to Type 3, which had a well-harmonized SSPA. Group D (no change in classification Type from Type 4) did not show any significant difference, but showed a large preoperative APP and considerable anteversion, as well as minimal  $\Delta$ APP. Group E (wherein the classification Type changed to Type 1 and 2), however, had a large  $\Delta$ APP ( $-10.4^\circ$ ), and large postoperative retroversion. Among the groups D, E, and F, no significant difference was observed in the radiographic parameters, and hence, the differences were thought to be related to preoperative anteversion and postoperative retroversion.

In conclusion, the SSPA changes after THA, and improves in certain cases. Cases with pelvic retroversion and reduced lumbar lordosis before THA did not show any change in SSPA after THA. Half of the cases with a favourable SSPA before THA maintained this favourable condition after THA as well. However, in cases where the lordosis was reduced despite the presence of a favourable SSPA, postoperative pelvic retroversion and worsening of SSPA were noted. In cases with preoperative pelvic anteversion, high SS, 41% of cases had improved SSPA after THA.

## REFERENCES

- 1) Parvizi J, Pour AE, Hillibrand A, Goldberg G, Sharkey PF, Rothman RH: Back pain and total hip arthroplasty: a prospective natural history study. *Clin Orthop Relat Res* 468: 1325-1330, 2010
- 2) Provan JL, Moreau P, MacNab I: Pitfalls in the diagnosis of leg pain. *Can Med Assoc J* 121: 167-171, 1979
- 3) Offierski CM, MacNab I: Hip-spine syndrome. *Spine (Phila Pa 1976)* 8: 316-321, 1983
- 4) Ben-Galim P, Ben-Galim T, Rand N, Haim A, Hipp J, Dekel S, Floman Y: Hip-spine syndrome: the effect of total hip replacement surgery on low back pain in severe osteoarthritis of the hip. *Spine (Phila Pa 1976)* 32: 2099-2102, 2007
- 5) Jackson RP, Peterson MD, McManus AC, Hales C: Compensatory spinopelvic balance over the hip axis and better reliability in measuring lordosis to the pelvic radius on standing lateral radiographs of adult volunteers and patients. *Spine (Phila Pa 1976)* 23: 1750-1767, 1998
- 6) Legaye J, Duval-Beaupère G, Hecquet J, Marty C: Pelvic incidence: a fundamental pelvic parameter for three-dimensional regulation of spinal sagittal curves. *Eur Spine J* 7: 99-103, 1998
- 7) Ferguson AB: The Clinical and Roentgenographic Interpretation of Lumbosacral Anomalies. *Radiology* 22: 548-558, 1934
- 8) Roussouly P, Gollogly S, Berthonnaud E, Dimnet J: Classification of the normal variation in the sagittal alignment of the human lumbar spine and pelvis in the standing position. *Spine (Phila Pa 1976)* 30: 346-353, 2005
- 9) Ishida T, Inaba Y, Kobayashi N, Iwamoto N, Yukizawa Y, Choe H, Saito T: Changes in pelvic tilt following total hip arthroplasty. *J Orthop Sci* 16: 682-688, 2011
- 10) Taki N, Mitsugi N, Mochida Y, Akamatsu Y, Saito T: Change in pelvic tilt angle 2 to 4 years after total hip arthroplasty. *J Arthroplasty* 27: 940-944, 2012
- 11) Kyo T, Nakahara I, Miki H: Factors predicting change in pelvic posterior tilt after THA. *Orthopedics* 36: e753-759, 2013
- 12) Crowe JF, Mani VJ, Ranawat CS: Total hip replacement in congenital dislocation and dysplasia of the hip. *J Bone Joint Surg Am* 61: 15-23, 1979
- 13) Wiltse LL, Winter RB: Terminology and measurement of spondylolisthesis. *J Bone Joint Surg Am* 65: 768-772, 1983
- 14) DiGioia AM, Hafez MA, Jaramaz B, Levison TJ, Moody JE: Functional pelvic orientation measured from lateral standing and sitting radiographs. *Clin Orthop Relat Res* 453: 272-276, 2006
- 15) Radcliff KE, Orozco F, Molby N, Delasotta L, Chen E, Post Z, Ong A: Change in spinal alignment after total hip arthroplasty. *Orthop Surg* 5: 261-265, 2013
- 16) Okuda T, Fujita T, Kaneuji A, Miaki K, Yasuda Y, Matsumoto T: Stage-specific sagittal spinopelvic alignment changes in osteoarthritis of the hip secondary to developmental hip dysplasia. *Spine (Phila Pa 1976)* 32: E816-819, 2007
- 17) Araújo F, Lucas R, Alegrete N, Azevedo A, Barros H:



- Individual and contextual characteristics as determinants of sagittal standing posture: a population-based study of adults. *Spine J* 14: 2373-2383, 2014
- 18) Chaléat-Valayer E, Mac-Thiong JM, Paquet J, Berthonnaud E, Siani F, Roussouly P: Sagittal spinopelvic alignment in chronic low back pain. *Eur Spine J* 20: 634-640, 2011

