

## Gastric function preserving esophagectomy for esophageal cancer

Kaori SHIGEMITSU<sup>1)</sup>, Yoko HIRABAYASHI<sup>1)</sup>, Munenori TAKAOKA<sup>1)</sup>,  
Takuya FUKAZAWA<sup>1)</sup>, Jiro HAYASHI<sup>1)</sup>, Kazuhiro YOSHIDA<sup>1)</sup>,  
Atsushi URAKAMI<sup>1)</sup>, Yasuhiro SHIRAKAWA<sup>2)</sup>, Toshiyoshi FUJIWARA<sup>2)</sup>,  
Tomoki YAMATSUJI<sup>1)</sup>, Kazutaka NAKASHIMA<sup>1)</sup>, Ichiro MORITA<sup>1)</sup>,  
Yoshio NAOMOTO<sup>1)</sup>

*1) Department of General Surgery, Kawasaki Hospital, Kawasaki Medical School  
2-1-80 Nakasange, Kita-ku, Okayama 700-8505, Japan*

*2) Department of Gastroenterological Surgery, Transplant and Surgical Oncology,  
Graduate School of Medicine and Dentistry, Okayama University  
2-5-1 Shikata-Cho, Kita-ku, Okayama 700-0914, Japan*

**ABSTRACT** Although, the gastric roll is widely used for reconstruction after an esophagectomy for esophageal cancer, adverse effects such as the post operative disturbance of oral intake and the reflux of gastric juice have been reported. A function preserving surgical procedure, which is similar to that for stomach and colon cancer, has been developed for esophageal cancer. Gastric function can be preserved by using the intestine as the reconstructive organ after an esophagectomy.

In this report, we described the procedure for an esophagectomy with pedunculated jejunal or right colonic interposition, collectively termed as a gastric function preserving esophagectomy (GPE). We believe that this procedure is minimally invasive with a low risk of postoperative digestive symptoms and weight loss.

*(Accepted on March 25, 2013)*

Key words : **esophageal cancer, gastric function, esophageal reconstruction**

### INTRODUCTION

Reconstruction with the gastric roll after an esophagectomy for esophageal cancer has become an established surgical procedure because it is easier than almost any other organ for reconstructive surgery. However, this procedure is associated with poor long-term quality of life (QOL) with respect to

digestion and absorption.

Since 2000, our surgical team has performed reconstruction with the preservation with the vagus nerve, a transhiatal lower esophagectomy, and a pedunculated jejunal or right colonic interposition for tumors of the superficial lower thoracic esophagus and abdominal esophagus with no

---

Corresponding author  
Kaori Shigemitsu  
Department of General Surgery, Kawasaki Hospital,  
Kawasaki Medical School 2-1-80 Nakasange, Kita-ku,  
Okayama 700-8505, Japan

Phone : 81 86 225 2111  
Fax : 81 86 232 8343  
E-mail : [namaste@med.kawasaki-m.ac.jp](mailto:namaste@med.kawasaki-m.ac.jp)

Fig. 1a

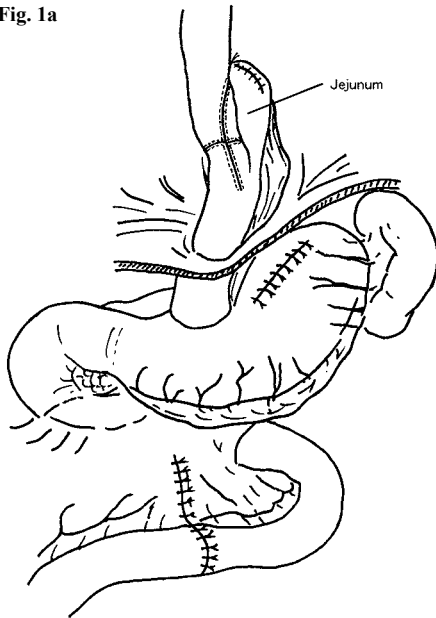


Fig. 1b

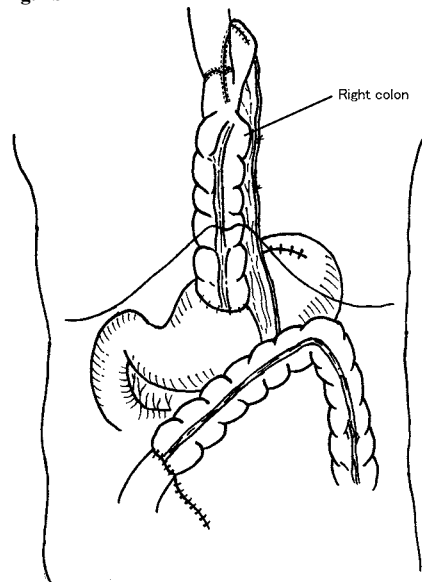


Fig. 1. Schema of reconstruction after a gastric function-preserving esophagectomy

a) Reconstruction with jejunal interposition

b) Reconstruction with colonic interposition

obvious lymph node metastasis including Barrett's esophagus<sup>1)</sup>. We have obtained good results with respect to the postoperative body weight of patients. Considering the positive results obtained with the abovementioned procedures, we hypothesized that gastric function could be preserved without the preservation of the vagus nerve. We therefore began to perform gastric function-preserving esophagectomies (GPE; Fig. 1) with radical lymph node dissection not only for early esophageal cancer but also for advanced cases and have described below the procedure and techniques used by our surgical team.

## INDICATION

GPE is indicated for esophageal tumors located below the level of the tracheal bifurcation. The indications for GPE with respect to age, depth of invasion and lymph node metastasis are identical to that for conventional surgery for esophageal cancer.

## ANESTHESIA AND POSITIONING

The procedure is performed under general anesthesia with one-lung ventilation, with the patient on his/her left side in a lying position with the head tilted at 45° on a Magic Bed. The abdominal procedure is switched over to the thoracic procedure by one turn of the bed without changing the patient's position. The patient's right arm was kept free in a clean field and was elevated and fixed during the thoracic procedure. This flexibility in positioning enables us to simultaneously perform the abdominal and thoracic procedures, thereby decreasing the surgical duration. In addition, the Magic Bed is useful for elevating the intestine from the abdominal cavity to the thoracic cavity during reconstruction.

## SURGICAL PROCEDURE

The section below describes the procedure for jejunal or right colonic reconstruction after a lower thoracic esophagectomy.

An upper median laparotomy was done followed by the removal of the xiphoid process, and adequate exposure was achieved using retractors. The left lateral lobe of the liver was mobilized by division of the left triangular and coronary ligaments. The uppermost portion of the gastrohepatic ligament was isolated, an incision was made in the peritoneum over the esophagus between the fundus and diaphragmatic base, and the abdominal esophagus was retracted with polyester tape.

The left gastric artery and left gastric vein were ligated during dissection of the first, second, third, seventh, eighth, and ninth lymph nodes. The anal side (gastric side) (including the esophagogastric junction or the fundic portion) was cut with a GIA linear stapler. Seromuscular layer sutures were placed on the anal stump and three silk traction sutures were placed on the oral stump.

The left subphrenic vein was ligated after transfixing the sutures, following which a limited incision was made in the midline between the esophageal hiatus and the central tendon to expose the lower mediastinal space. A clear view was secured by compressing the pericardium and parietal pleura with a bowel retractor. The abdominal

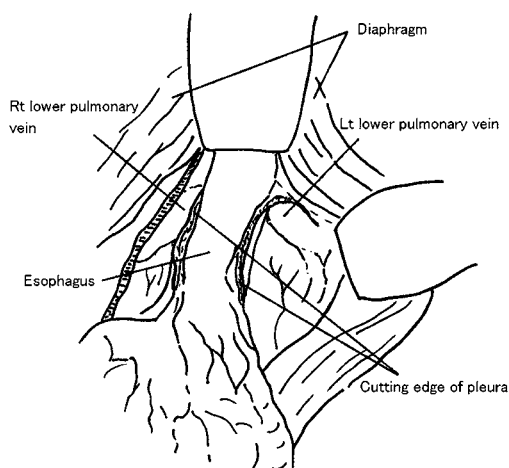


Fig. 2. Transhiatal surgery  
The esophagus is exfoliated and the lymph nodes are dissected towards the oral side (usually up to the level of the lower pulmonary vein).

esophagus was exfoliated from the hiatus, and the lymph nodes were dissected as far towards the oral side as possible, which is usually up to the level of the lower pulmonary vein (Fig. 2). All of these procedures were performed using an electro-surgical unit (an ultrasonic-activated device). During this procedure, care must be taken to stop bleeding from the esophageal arteries; in cases with uncontrolled bleeding, hemostasis can be achieved by ligating the arteries with hemoclips. In cases where the oral side of the esophagus, which is clipped before the transhiatal surgery, can be easily identified, the surgery can be made minimally invasive by the isolation of the esophagus and the establishment of an anastomosis without a thoracotomy. Moreover, the abdominal manipulation and cervical lymph node dissection can be synchronized, thereby decreasing the surgical duration.

After the transhiatal surgery, the bed was turned, the patient was shifted into the left lateral decubitus position, and the thoracic procedure (anterior axillary thoracotomy) was initiated with a fourth intercostal incision of 8-10 cm. During the cervical and transhiatal manipulation, the dissection of the thoracic esophagus was completed in stages. The transhiatal incision line in the pleura was extended upwards and the silk traction sutures were placed at the esophageal stump through the hiatus. The esophageal and lymph node dissection was performed towards the oral side.

Reconstruction manipulation with jejunal or colonic interposition was performed in the supine position. Reconstruction of the jejunum is the first choice of procedure in cases that can be operated via a transhiatal approach and in which the jejunum can be adequately elevated. Before ligating the mesenteric vessels of the jejunum, the ileocecal portion was mobilized and the mesentery was exfoliated from the retroperitoneum (Fig. 3). At this time, exfoliating the superior mesenteric artery and superior mesenteric vein sufficiently to the back

of the pancreas can help to elevate the jejunum by approximately 6-8 cm. Usually either the secondary or the tertiary jejunal arteries and veins are ligated, but elevation is easier if both are ligated. After isolation of the vessels, the jejunum was cut to approximately 15-20 cm beyond the ligament of Treitz, where it can be easily mobilized with a linear stapler, and was pulled via a retrocolic-retrogastric route through the esophageal hiatus using the left hand (which was inserted through the thoracotomy wound).

In cases where elevation of the small intestine is problematic, reconstruction can be performed with the colon, which is usually supplied by a middle colic blood vessel and a colonic branch of an ileocolic blood vessel. The terminal ileum and right colon are elevated in orthodromic peristalsis. First, we mobilize the ileocecum and exfoliated ascending colon from the duodenum and pancreas. Adequate mobilization of the mesentery to the region near the ligament of Treitz is important.

Regarding the intestinal isolation, the area from

between the root of the middle colic artery to the esophageal anastomosis was covered with cotton tape, which was placed along the marginal artery that branched towards the oral side from the root of the middle colic artery, and the oral side of the ileum, where the anastomosis was planned, was cut. With regard to the isolation of the anus and colon, after the elevation of the ileum and the establishment of the esophagoileal anastomosis, the colon was cut at the closest part which was to be anastomosed with the stomach. In this method, adequate blood flow plays an important role; therefore, it is preferable to confirm the blood flow by transillumination and a clump test of the artery which is to be cut.

In cases with poor blood flow in the bowel or in which bending or elevation of the bowel is evident, the colic branch of the ileocolic blood vessel is ligated and pulled through the subcutaneous route, and an anastomosis between the cervical or internal thoracic vessels and the iliac branch of the ileocolic vessels is established. Alternatively, reconstruction with the stomach can be performed in cases with

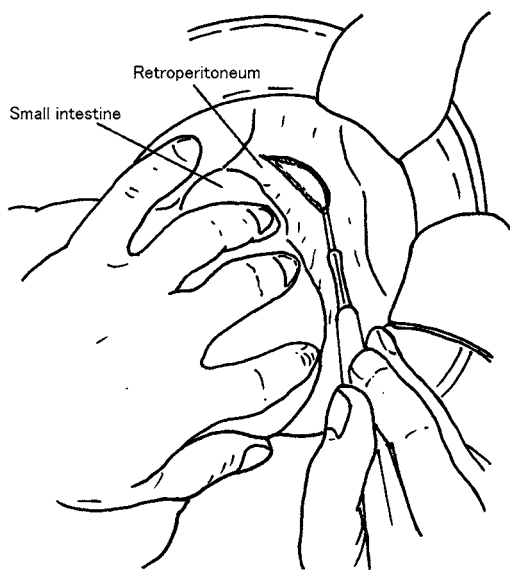


Fig. 3. Exfoliation and mobilization of the ileocecal portion. The ileocecal portion is mobilized and the mesentery is exfoliated from the retroperitoneum.

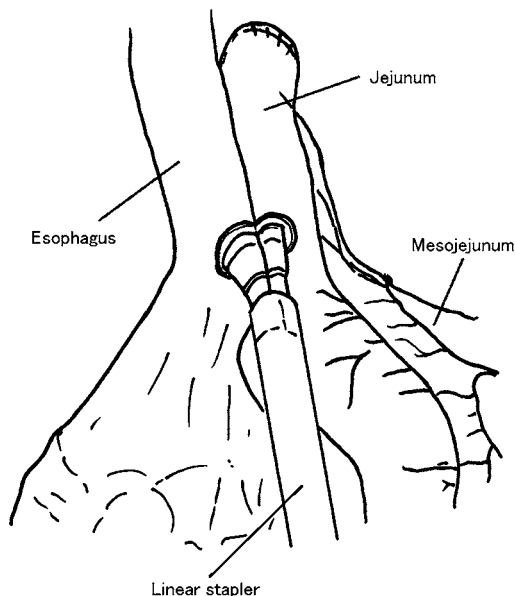


Fig. 4. Esophagoenterostomy. An esophagoenterostomy with overlap anastomosis is performed using a linear stapler.

limited blood flow in the bowel or in which bowel elevation is difficult.

We also performed an esophagoenterostomy with overlap anastomosis using a linear stapler. We opened a small pore approximately 8 cm from the tip of the elevated intestine, and inserted one end of the linear stapler through this opening and the other through the actinal side of the esophagus, following which a side-to-side anastomosis (Fig. 4) was established. The entry points for the insertion of the linear stapler was closed with another linear stapler, thus completing the esophagoenterostomy.

## DISCUSSION

Gastric function-preserving reconstruction after an esophagectomy was reported on by Akiyama *et al.*<sup>2)</sup>, who performed an esophagectomy with vagal preservation followed by esophageal reconstruction without a thoracotomy in 1993. But this technique is adapted to early cancer which does not require lymph node excision. On the other hand, our procedure is applied in esophagectomies with radical lymph node dissection not only for early esophageal cancer but also for advanced cases.

Ando *et al.*<sup>3)</sup> reviewed the QOL of patients who underwent a colonic interposition after an esophagectomy and vagotomy, and reported that the stomach could be preserved with this procedure; in addition, the body weight of the patient could be normalized after surgery. In addition, Kasai and Nishihira<sup>4)</sup> reported on intestinal reconstruction in the 1980s and clarified the significance of this procedure.

The surgical method described in this paper has certain advantages. First, there are few reflexes involved. Second, very little bowel needs to be resected compared to a conventional jejunal reconstruction. Third, the thoracic procedure and

cervical/abdominal procedure can be completed in the same operative field. Fourth, it is simple to achieve an anastomosis using a linear stapler with thoracoscopic assistance. Fifth, there is little risk of anastomotic strictures due to the overlap anastomosis. Lastly, the chances of the occurrence of gastric cancer, which can sometimes occur after gastric reconstruction, are minimized.

In our department, we have adopted and performed this surgical procedure since October 2006.

We have already reported that jejunal interposition with a stomach preserving esophagectomy improves postoperative quality of life, mainly due to the long-term elimination of reflux esophagitis<sup>5)</sup>.

So in this report, we described the details of this procedure.

## REFERENCES

- 1) Haisa M, Naomoto Y, Shirakawa Y, Shigemitsu K, Yamatsuji T, Kataoka M, Tanaka T: Gastric function preserving esophagectomy for esophageal cancer. *Surgical therapy* 87 : 70-78, 2002
- 2) Akiyama H, Tsurumaru M, Ono Y, Udagawa H, Kajiyama Y: Esophagectomy without thoracotomy with vagal preservation and esophageal reconstruction. *Jpn Bronchoesophagol Soc* 44 : 96-98, 1993
- 3) Ando N: Postoperative nutrition status in patients with esophageal carcinoma. *Disease of the esophagus, Japan*, Furuta Publishing Co Inc, 1988, pp261-269
- 4) Kasai M, Nishihira T: Reconstruction using pedicled jejunal segments after resection for carcinoma of the cervical esophagus. *Surg Gynecol Obstet* 163 : 145-152, 1986
- 5) Yamada E, Shirakawa Y, Yamatsuji T, *et al.*: Jejunal interposition reconstruction with a stomach preserving esophagectomy improves postoperative weight loss and reflux symptoms for esophageal cancer patients. *J Surg Res* 178 : 700-707, 2012