

Interstitial lung disease after re-administration of gefitinib in a responder with no adverse effects during the first administration: a case report

Katsuhiko SHIMIZU, Yuji HIRAMI, Shinsuke SAISHO, Takuro YUKAWA, Ai MAEDA
Koichiro YASUDA, Masao NAKATA

Department of General Thoracic Surgery, Kawasaki Medical School, 577 Matsushima, Kurashiki, 701-0192, Japan

ABSTRACT Gefitinib-related interstitial lung disease (ILD) has been reported as a serious adverse effect, associated with a high mortality. Recently, it was reported that gefitinib may be effective again following re-administration in cases with a previous history of response to gefitinib. However, there have been no reports on the safety of re-administration of gefitinib. We report the case of a patient who developed ILD after being restarted on gefitinib, having shown complete response, with no serious adverse effects, during/after the first administration. Re-administration of gefitinib should be considered cautiously, even if the previous administration was associated with no side effects.

(Accepted on June 23, 2011)

Key words : **Interstitial lung disease(ILD), Gefitinib**

INTRODUCTION

Gefitinib is an orally active inhibitor of EGFR tyrosine kinase and is one of the leading EGFR-targeted agents used in cancer therapy¹⁾. However interstitial lung disease (ILD) -type events, associated with a high mortality, have been reported as serious adverse effects of this agent²⁾. Recently, it was reported that gefitinib may be effective again following re-administration in cases with a previous history of response to gefitinib³⁾. However, there have been no reports on the safety of re-administration of gefitinib. In this report, we describe the case of a patient who developed ILD after being restarted on gefitinib, having shown

a good response, without serious adverse effects, during/after the first administration.

CASE REPORT

A 79-year-old man was admitted our hospital because of an abnormal shadow in the right lung detected on chest computed tomography (CT). He gave a history of smoking one pack of cigarettes daily from the age of 30 to 65 years. Transbronchial lung biopsy showed adenocarcinoma of the lung. Right middle lobectomy was performed, with systematic lymph node dissection. Pathological examination revealed adenocarcinoma of the mixed subtype, and the pathological stage was stage IIIA

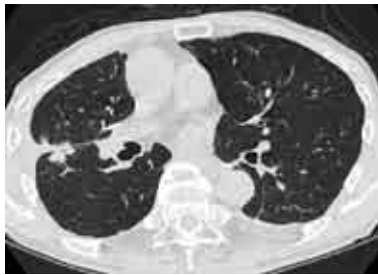Corresponding author
Katsuhiko Shimizu
Department of General Thoracic Surgery, Kawasaki
Medical School, 577 Matsushima, Kurashiki, 701-0192,
Japan

Phone : 81 86 462 1111
Fax : 81 86 462 1199
E-mail : kshimizu@med.kawasaki-m.ac.jp

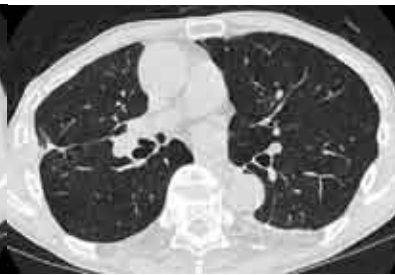(T3N2M0). Oral administration of UFT (300 mg/day) was initiated as adjuvant chemotherapy. About 15 months later, the patient presented with hemoptysis, and sputum cytology revealed adenocarcinoma. CT revealed local recurrence and pleural dissemination on the right side (Fig.1A). On examination of the surgical specimen, epidermal growth factor receptor (EGFR) gene mutation was detected. Oral administration of gefitinib (250

mg/day) was initiated, which led to remarkable resolution of the disease. Six months later, no abnormal finding was detected on positron emission tomography (PET) /CT, and the patient was labeled as showing complete response (CR) (Fig.1B). About 15 months later, CR, as assessed by PET/CT, was maintained, however, the patients wished to discontinue gefitinib because of generalized fatigue and appetite loss. Nine months after

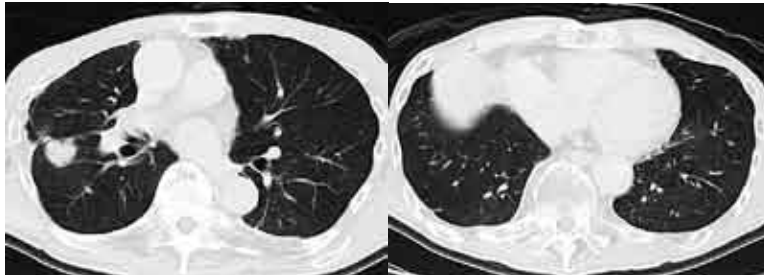
A: before first gefitinib



B: after first gefitinib



C: before reinstatement of gefitinib



D: after reinstatement of gefitinib

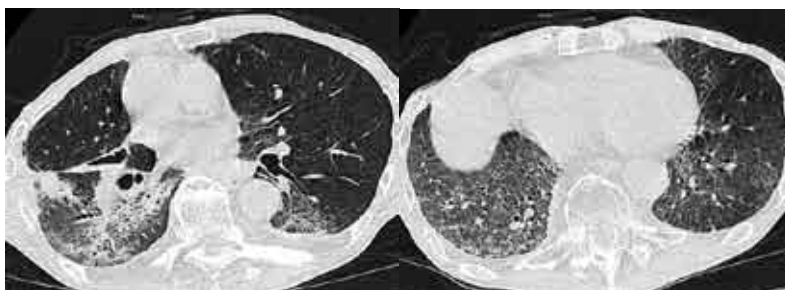


Fig. 1. Chest computed tomography (CT) scans obtained before (A) and 6 months after initiation of treatment with gefitinib (B).

Chest CT scans before reinstatement of gefitinib (C) and after 10 days' treatment with gefitinib (D). CT revealed multiple ground-glass opacities and intralobular septal thickening, distributed mainly in the lower and dorsal lung fields bilaterally.

discontinuation of gefitinib, brain metastasis was detected, which was treated by cyber-knife surgery. Chest CT revealed relapse of local recurrence in the right lung. (Fig.1C) As the patient wished to be restarted on gefitinib treatment, oral administration of gefitinib (250 mg/day) was initiated. On day 10 of gefitinib treatment, hypoxia and high fever appeared. Thin-slice CT revealed diffuse ground-glass opacities and intralobular septal thickening, distributed mainly in the lower and dorsal lung fields bilaterally, and the diagnosis of gefitinib-related ILD was made. (Fig.1D) Therefore, gefitinib was discontinued, and intravenous steroid pulse treatment (methylprednisolone 1g/day, 3days) was administered. The symptoms and radiological findings resolved promptly in response to the steroid pulse treatment.

DISCUSSION

Gefitinib-related ILD has been reported as a serious adverse effect of gefitinib therapy. In a previous study performed by the West Japan Thoracic Oncology Group (WJTOG), the incidence of gefitinib-induced ILD in Japan was 4% and the mortality associated with ILD was 31.6%⁴⁾. If this adverse effect is excluded, gefitinib has low toxicity.

Recently, several cases with re-administration of gefitinib have been reported⁵⁻⁸⁾. It has been reported that patients responding to first administration may still respond, with survival prolongation, to re-administration of the drug. To the best of our knowledge, ILD after re-administration has occurred in two cases until date. Inoue *et al.* described one case of ILD developing after treatment was restarted. This patient was given gefitinib for 83 days with no serious adverse effects; the drug had been discontinued for 1month before it was restarted, and the patient developed ILD 14 days after it was restarted²⁾. Suzuki *et al.* described a patient with recurrent gefitinib-related ILD. This patient developed ILD 23 days after the

start of gefitinib treatment, and the ILD recurred after gefitinib was restarted⁹⁾. Until date, however, no information has been collected on the safety of re-administration of gefitinib after it is discontinued once. In the present case, we thought this patient to be gefitinib-induced ILD because he did not take other drugs induced ILD. We speculated that immunological activation rather than drug cytotoxicity might be involved in pathogenesis of ILD.

CONCLUSION

In this report, we describe the case of a patient who developed ILD after being restarted on gefitinib, having shown complete response, without serious adverse effects, during/after the first administration. Thus, re-administration of gefitinib should be considered cautiously even if the previous administration was associated with no side effects.

REFERENCES

- 1) Ciardiello F, Caputo R, Bianco R, Damiano V, Fontanini G, Cuccato S, DePlacido S, Bianco AR, Tortora G : Inhibition of growth factor production and angiogenesis in human cancer cells by ZD1839 (Iressa), a selective epidermal growth factor receptor tyrosine kinase inhibitor. *Clin Cancer Res* 7 : 1459-1465, 2001
- 2) Inoue A, Saijo Y, Maemondo M, Gomi K, Tokue Y, Kimura Y, Ebina M, Kikuchi T, Moriya T, Nukiwa T : Severe acute interstitial pneumonia and gefitinib. *Lancet* 361 : 137-139, 2003
- 3) Riely GJ, Kris MG, Zhao B, *et al* : Prospective assessment of discontinuation and reinitiation of erlotinib or gefitinib in patients with acquired resistance to erlotinib or gefitinib followed by the addition of everolimus. *Clin Cancer Res* 13 : 5150-5155, 2007
- 4) Kudoh S, Kato H, Nishiwaki Y, *et al* : Interstitial lung disease in Japanese patients with lung cancer: a cohort and nested case-control study. *Am J Respir Crit Care Med* 177 : 1348-1357, 2008
- 5) Yano S, Nakataki E, Ohtsuka S, Inayama M, Tomimoto H, Edakuni N, Kakiuchi S, Nishikubo N, Muguruma H, Sone S : Retreatment of lung adenocarcinoma patients

- with gefitinib who had experienced favorable results from their initial treatment with this selective epidermal growth factor receptor inhibitor: a report of three cases. *Oncol Res* 15 : 107-11, 2005
- 6) Yokouchi H, Yamazaki K, Kinoshita I, *et al* : Clinical benefit of readministration of gefitinib for initial gefitinib-responders with non-small cell lung cancer. *BMC Cancer* 7 : 51, 2007
- 7) Yoshimoto A, Inuzuka K, Kita T, Kawashima A, Kasahara K : Remarkable effect of gefitinib retreatment in a patient with nonsmall cell lung cancer who had a complete response to initial gefitinib. *Am J Med Sci* 333 : 221-225, 2007
- 8) Takamochi K, Suzuki K, Bashar AH, Yajima K, Mochizuki T, Itaya T, Funai K : Readministration of gefitinib in a responder after treatment discontinuation due to gefitinib-related interstitial lung disease: a case report. *J Med Case Reports* 1 : 138, 2007
- 9) Suzuki M, Asahina H, Konishi J, Yamazaki K, Nishimura M : Recurrent gefitinib-induced interstitial lung disease. *Intern Med* 47 : 533-536, 2008