

Secondarily–developed gingival cyst of the adult : A case report

Tsuyoshi HATA¹⁾, Isao IREI²⁾, Masaru HOSODA¹⁾, Toshiko MANDAI¹⁾
Kosei ISHIDA¹⁾, Satoshi ITO¹⁾, Hiroyo DEGUCHI¹⁾

1) Department of Oral Surgery, 2) Department of Pathology, Kawasaki Medical School, 577 Matsushima, Kurashiki 701-0192, Japan

ABSTRACT Gingival cyst of the adult (GCA) is a relatively uncommon developmental cyst. Recurrence is not expected following simple excision with minimal margins. A hitherto unreported observation of a case of GCA developing secondarily at the same site of the first excision, and an additional discussion of the etiologic factors and differential diagnosis are presented.

(Accepted on September 30, 2009)

Key words : **Gingival cyst, Developmental cyst, Mandible, Jaw, Adult**

CASE REPORT

A 49-year-old Japanese woman presented with a history of a painless mass on the left anterior mandibular gingiva of about one year's duration. The lesion had been asymptomatic with no enlargement. A gray-white, 3mm diameter lesion was found between the mandibular left lateral incisor and the

canine. The lesion was removed surgically and was submitted for histopathologic evaluation. The recovery was uneventful.

About seven years postoperatively, the patient revisited because of a small mass that had developed at the site of the previous excision of the gingival mass. The secondarily-developed lesion had been present for six months. During a routine oral examination, a 3mm in diameter, slight bluish mass was found on attached gingiva of the mandible between the left lateral incisor and the canine (Fig.1). The adjacent teeth were normal except for attrition. A panoramic radiograph showed no abnormal finding in this region (Fig.2).

The lesion was excised with covering gingiva and periosteum under local anesthesia. A small cup-shaped pressure resorption of underlying cortical bone was present. The excised region was covered with a small mucoperiosteal flap. The surgical site healed uneventfully with no recurrence at an eight-

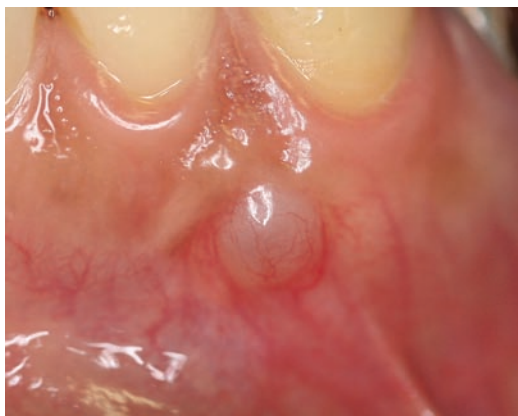

Fig. 1. Secondarily-developed mass in the left mandible.

Corresponding author
Tsuyoshi Hata
Department of Oral Surgery, Kawasaki Medical School,
577 Matsushima, Kurashiki, 701-0192, Japan

Phone : 81 86 462 1111
Fax : 81 86 462 1199
E-mail : denthata@med.kawasaki-m.ac.jp

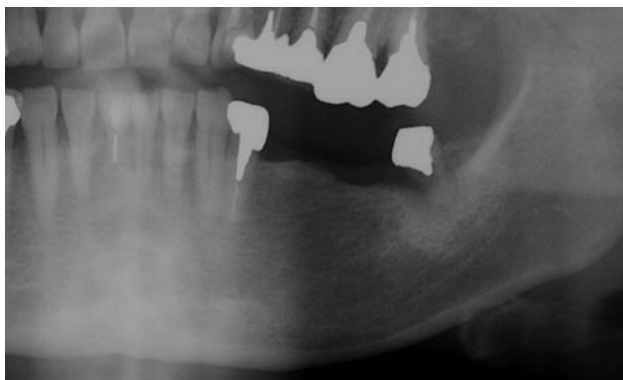

Fig. 2. Panoramic views of the left mandible.

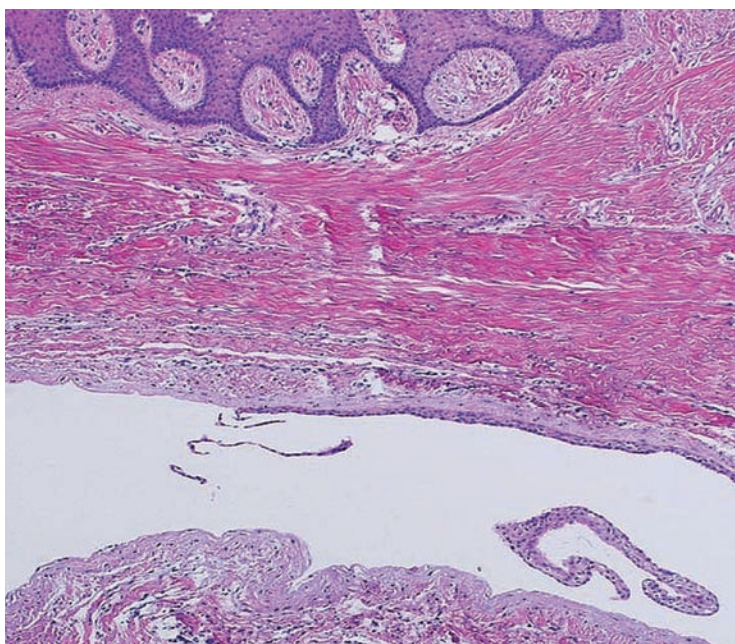


Fig. 3. Photomicrograph of the secondarily-developed mass (H.E. stain, $\times 100$).

month follow-up.

Both the first specimen and the secondarily-developed specimen of the lesions had almost the same histopathologic findings (Fig.3). The specimen was covered with normal stratified squamous epithelium. The cyst was lined with several thin layers of non-keratinized squamous epithelium. The epithelial lining was detached from the underlying connective tissue. There were no histiocytes or inflammatory cells in the surrounding fibrous

connective tissue. No blue staining mucin-like material or minor salivary glands were present in the specimens. Alcian-blue stain failed to reveal even traces of mucous substance in the specimens. Both diagnoses of the specimens were gingival cyst of the adult (GCA).

DISCUSSION

GCA most probably originates from odontogenic rests of the dental lamina, with cystification of

elongated surface epithelium as the alternative etiology^{1,2)}. In the present case, the possibilities of odontogenic rests or cystification of elongated surface epithelium were slight since there were no odontogenic rests in the surrounding connective tissue and no contact between the surface epithelium and epithelial lining of the cyst was identified.

A gingival "surgical" cyst (GST) developing secondarily to a subepithelial connective tissue graft³⁾ may suggest inadvertent traumatic implantation of surface epithelium as the other etiology of the lesion. The cyst wall of GST demonstrates a stratified squamous epithelial lining with mild chronic inflammatory foci and acanthosis. Such pathological findings differed from those of the present case.

Heterotopic glandular elements in the head and neck region could give rise to various benign or malignant tumors⁴⁾. Heterotopic glandular elements of the gingiva are very rare, but could give rise to gingival mucocele^{5,6)} or gingival salivary gland choristoma⁷⁾. The clinical features of GCA resemble those of gingival mucocele. There are glandular elements and mucous substance in the gingival mucocele. Negative Alcian-blue staining, which is indicative of no mucous substance, could be a diagnostic point for distinguishing between the GCA of the present case and gingival mucocele.

Both clinical and histological similarities between GCA and lateral periodontal cyst may indicate that GCA represents the extraosseous counterpart of an intraosseous lateral periodontal cyst⁸⁾. In the present case, the cyst was located within the gingiva.

GCA is a relatively uncommon developmental cyst as either a unilateral⁹⁾ or multiple phenomenon¹⁰⁾. Recurrence is not expected following simple excision with minimal margins^{2,9)}. Many of these

cysts may not be recognized clinically because of their small size, and others are probably resolved by the tissues during the early stage⁹⁾. Whether the second lesion was a new cyst or not is still unknown, but, to the best of our knowledge, the present case is the first known case of GCA developing secondarily at the same site after excision of the first lesion.

REFERENCES

- 1) Breault LG, Billman MA, Lewis DM: Report of a gingival "surgical cyst" developing secondarily to a subepithelial connective tissue graft. *J Periodontol* 68: 392-395, 1997
- 2) Hata T, Iga H, Imai S, Hirokawa M: Heterotopic salivary gland adenocarcinoma in the cervical region. *Int J Oral Maxillofac Surg* 26: 290-292, 1997
- 3) Izumi H, Oikawa T, Yoshida T, Inoue Y, Komiyama K, Ryu T, Miyake K: A consideration of a case of gingival cyst with glandular epithelium. *Nihon Univ J Oral Sci* 2: 242-246, 1976
- 4) Ledesma-Montes C, Fernandez-Lopez R, Garcés-Ortiz M, Portilla-Robertson J, Hernandez-Guerrero JC: Gingival salivary gland choristoma. A case report. *J Periodontol* 69:1164-1166, 1998
- 5) Reeve CM, Levy BP: Gingival cysts: a review of the literature and report of four cases. *Periodontics* 6:115-117, 1968
- 6) Ritchey B, Orban B: Cysts of the gingiva. *Oral Surg Oral Med Oral Pathol* 6: 765-771, 1953.
- 7) Sciubba JJ, Fantasia JE, Kahn LB: Tumors and cysts of the jaws. *In Atlas of tumor pathology*. 3rd series; fasc. 29, Washington DC, USA, Armed Forces Institute of Pathology. 2001, pp47-49
- 8) Shade NL, Carpenter WM, Delzer DD: Gingival cyst of the adult. Case report of a bilateral presentation. *J Periodontol* 58: 796-799, 1987
- 9) Traeger KA: Cyst of the gingiva (mucocele). *Oral Surg Oral Med Oral Pathol* 14: 243-245, 1961
- 10) Wescott WB, Correll RW, Craig RM: Two fluid-filled gingival lesions in the mandibular canine-first premolar area. *J Am Dent Assoc* 108: 653-654, 1984

