

Extrapulmonary Small Cell Carcinoma of the Hypopharynx : A Case Report

Kenji YOSHIDA, Junichi HIRATSUKA, Daigo TANIMOTO*,
Masayuki GYOTEN*, Yoshiro SADAHIRA** and Yoshinari IMAJO

*Department of Radiation Oncology, Kawasaki Medical School,
Kurashiki 701-0192, Japan*

**Department of Diagnostic Radiology, Kawasaki Medical School,
Kurashiki 701-0192, Japan*

***Department of Pathology, Kawasaki Medical School,
Kurashiki 701-0192, Japan*

Accepted for publication on December 22, 2005

ABSTRACT. We report a case of extrapulmonary small cell carcinoma of the hypopharynx. A 78-year-old man was referred for radiation therapy of a hypopharyngeal tumor. The pathological diagnosis was malignant, but inconclusive. Laryngeal fiberoptic examination revealed a tumor filling the right pyriform sinus. Palpation and MR imaging showed no lymph node metastasis. Further examination showed no distant metastasis. After admission, we again investigated the pathology of the tumor in detail and diagnosed small cell carcinoma. He received concurrent radiotherapy of a total dose of 54 Gy, and chemotherapy consisting of docetaxel, carboplatin and 5-FU, with a complete remission. He has been free from the disease for three years.

Key words : extrapulmonary small cell carcinoma—
hypopharyngeal carcinoma — radiotherapy — chemotherapy

CASE REPORT

A 78-year-old man was referred to Kawasaki Medical School Hospital from an otolaryngologist on July 17, 2002. He had been suffering discomfort and pain of the throat for a month. He consulted the referring otolaryngologist and a left hypopharyngeal tumor was suspected. The pathological diagnosis was malignant, but inconclusive, although small cell carcinoma or malignant lymphoma was suspected. His height was 167.5 cm, and body weight was 62.4 kg. His past medical history included pulmonary tuberculosis about 60 years earlier and appendicitis 55 years earlier. He had a 50-year history of smoking, and he was a moderate user of alcohol. Physical examination revealed no abnormalities. Laboratory data only showed a slight decrease in platelets. Several tumor markers (SCC antigen, SLX antigen, and NSE) were within normal limits. Laryngeal fiberoptic examination revealed a tumor filling the right pyriform sinus and infiltrating into the right aryepiglottic fold. The hemivocal cord was not fixed (Fig 1). Bilateral neck lymph nodes were not palpated. MR imaging disclosed a tumor extending to the right pyriform sinus with no apparent lymphadenopathy (Fig 2). Further examination

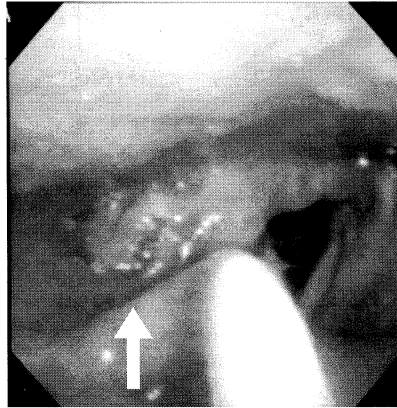


Fig 1. Laryngeal fiberscopy reveals a tumor filling the right pyriform sinus (arrow head).

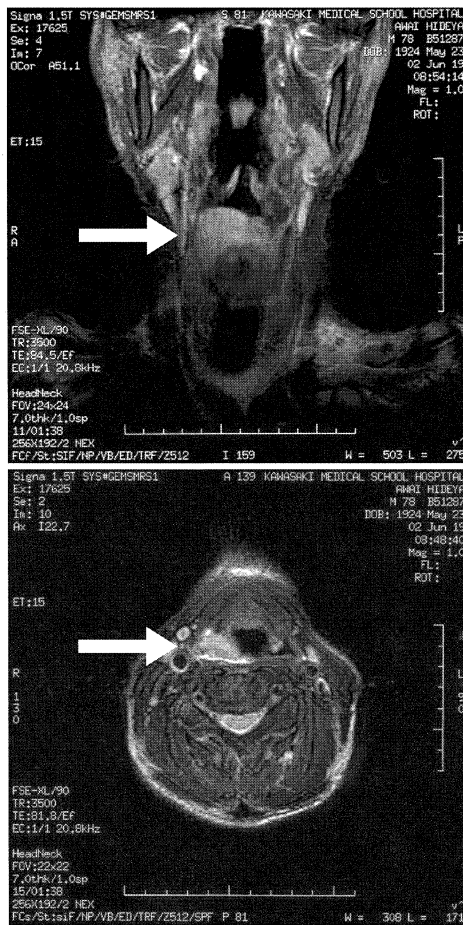

Fig 2. Magnetic resonance imagings disclose a hypopharyngeal mass extending to the right pyriform sinus (arrow head).

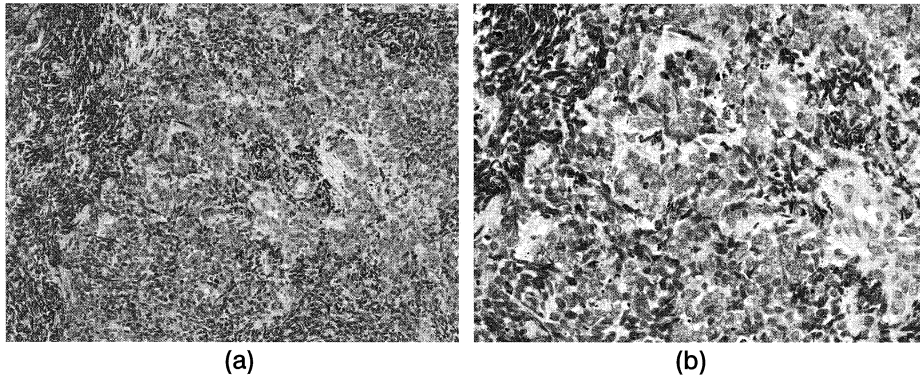


Fig 3. An H-E stained biopsy specimen of shows nests of small neoplastic cells with dense nuclei, granular nuclear chromatin and inconspicuous nucleoli. (a) low-grade focus. (b) high-grade focus.

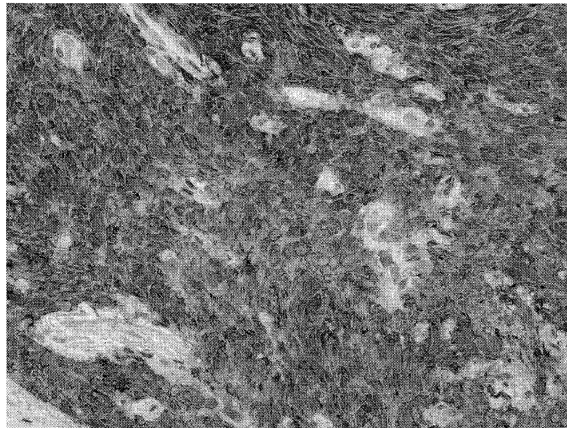


Fig 4. A biopsy specimen with high-grade focus shows that the tumor cells are positive for CD56.

showed no apparent distant metastasis. The tumor was staged as T2N0M0 (TNM classification, UICC, 1997).

After admission, we again carried out a biopsy to define the pathological diagnosis. The specimen revealed nests of small neoplastic cells with dense nuclei, granular nuclear chromatin and inconspicuous nucleoli (Fig 3-a, b). Immunohistochemical staining for a neuroendocrine marker (CD56) was positive (Fig 4). These findings suggested that the pathologic diagnosis of the tumor was compatible with small cell carcinoma.

He received whole neck irradiation. The fraction size was 2 Gy per day, five days a week. He also received one course of concomitant chemotherapy, consisting of docetaxel (50 mg/body, day 1, intraarterial infusion), cisplatin (50 mg/body, day 2, intravenous infusion), and continuous 5-FU (500 mg/body, days 2 to 5, intravenous infusion). Radiotherapy was finished on July 23 with a total dose of 54 Gy/27 fractions. At the end of the therapy, the tumor went into complete remission.

He was admitted to our hospital again for the purpose of prophylactic radiotherapy and consolidation chemotherapy on October 28, 2002. He received whole brain irradiation and bilateral supraclavicular node irradiation. The fraction size was 2 Gy per day, five days a week each. He also received one course of consolidation chemotherapy, consisting of carboplatin (400 mg/body, day 1) and etoposide (50 mg/body, day 1 to 3). Radiotherapy was finished with a total dose of 24 Gy/12 fractions each.

Since the first chemoradiotherapy, he has been free from the disease for three years and there has been no evidence of late complications of radiotherapy.

DISCUSSION

Small cell carcinoma most commonly occurs in the lung and it compromises about 20% of all lung cancers. Extrapulmonary small cell carcinoma (EPSCC) only compromises about 2 to 4% of all small cell carcinomas, but it occurs in a wide variety of sites, such as the female reproductive system (particularly the cervix), the gastrointestinal tract (particularly the esophagus and the colon), the genitourinary region (particularly the prostate) and the head and neck region.¹⁾

Duguid and Kennedy were the first to report on EPSCC in the mediastinal glands without pathologic evidence of primary pulmonary involvement.²⁾ Several years later, McKeown reported the first two cases of EPSCC of the esophagus.³⁾ In the head and neck region, Olofsson and van Nostrand first described EPSCC of the larynx in 1972.⁴⁾ In 1980, Ferlito and Polidoro reported the first case of EPSCC of the hypopharynx.⁵⁾ The minor salivary gland is the most common site of EPSCC of the head and neck. The nasal cavity and paranasal sinus including the nasopharynx are the second most common sites. The major salivary glands are less commonly the site of EPSCC.^{1,6)}

Smoking appears to be closely related to the development of EPSCC of the head and neck. This relationship appears the strongest for laryngeal and hypopharyngeal sites. The incidence of EPSCC of the head and neck is greater in men than women and this may be a reflection of greater smoking among men.⁷⁾ In this case, the patient had been smoking for fifty years.

In the larynx and hypopharynx, EPSCC is an aggressive and lethal malignancy. Metastases to the cervical lymph nodes coincident with the discovery of the primary tumor occur in nearly 50% of these patients. The prognosis is very poor with an average survival of 9.8 months. The two-year and five-year survival rates are 16% and 5%, respectively.⁸⁾

EPSCC is defined by a histological diagnosis of small cell carcinoma, a normal chest radiograph and CT scan, and normal sputum cytology or negative bronchoscopy. The histological criteria are the same as those for pulmonary neoplasms, namely uniform small cells with dense nuclei, inconspicuous nucleoli and sparse cytoplasm.⁹⁾ Immunohistochemical stainings for neuroendocrine markers, including chromogranin A, synaptophysin, and CD56 are usually positive, indicating that EPSCC is a part of the spectrum of neuroendocrine tumors.¹⁰⁾ In this case, immunohistochemical staining of

CD56 was positive.

The clinical staging of EPSCC is the same as that of small cell lung cancer. Limited disease (LD) is defined as a localized tumor with or without regional lymph node involvement and extensive disease (ED) as disease spread beyond regional regional boundaries. In this case, the clinical stage of the patient was LD and T2N0M0 according to the TNM classification.

The extent of disease is the most important factor for the treatment of and survival from EPSCC. Sengoz *et al.* reported that the median survival for patients with LD was 25 months compared to 12 months for patients with ED ($P=0.05$). The overall survival rates were 41% and 11% at two and five years.¹¹ Evanthia *et al.* reported that patients with locoregional tumor extension had significantly better survival ($P=0.0004$) than those with ED and significantly worse than those with disease confined to the organ of origin ($P<0.0001$). They divided patients with LD into patients with local disease (confined to the organ of origin) and those with locoregional disease (direct extension to the adjacent structures or metastasis to the regional lymph nodes). The overall survival was 38% and 13% at three and five years, respectively. They also reported that all patients who remained alive and disease free for at least three years after surgery had disease confined to the organ of origin.¹² According to their criteria, this case was defined to the local disease. There were three treatment options, surgery alone, surgery combined with adjuvant treatment, and concurrent chemoradiotherapy. We chose concurrent chemoradiotherapy because of the patient's advanced age and his rejection of surgery.

The chemotherapy regimen for EPSCC is similar to that for small cell lung cancer (SCLC). Platinum-based chemotherapy, such as PE (cisplatin-etoposide), is recognized as the most standard regimen for EPSCC. In this case, because the clinical stage was LD with no regional lymph node metastasis, we used intraarterial infusion of docetaxel for better local control, combined with systemic administration of platinum-based regimen.

Radiation therapy should not be used as a single modality for the treatment of LD, because of its limited effectiveness comparing with surgery or chemoradiotherapy. However it does appear to be a good method for achieving symptom control for patients with ED or recurrent disease.^{12,13}

Prophylactic cranial irradiation (PCI) is a quite controversial area in the treatment of SCLC. Auperin *et al.* performed a meta-analysis to determine whether PCI prolongs survival among patients with SCLC and they concluded that PCI improves both overall survival and disease-free survival among those in complete remission.¹⁴ Based on their finding, we think that PCI for this case seems to be appropriate. On the other hand, it is unclear whether prophylactic irradiation for a supraclavicular node is appropriate.

We experienced a case of EPSCC of the hypopharynx. EPSCC is usually a fatal and extremely rare disease, but if the correct pathological diagnosis and clinical staging are established, a combination of chemotherapy and radiation therapy can often achieve long term remission and cure in most patients with LD.

REFERENCES

- 1) Remick S, Hafez GR, Carbone PP: Extrapulmonary small cell carcinoma: A review of the literature with emphasis on therapy and outcome. *Medicine* **66**: 457-471, 1987
- 2) Duguid J, Kennedy AM: Oat-cell tumors of mediastinal glands. *J Pathol Bacteriol* **33**: 93-99, 1930
- 3) McKeown F: Oat-cell carcinoma of the esophagus. *J Pathol Bacteriol* **64**: 889-891, 1952
- 4) Olofsson J, van Nostrand AWP: Anaplastic small cell carcinoma of the larynx: Case report. *Ann Otol Rhinol Laryngol* **89**: 284-287, 1972
- 5) Ferlito A, Caruso G, Nicolai P, Recher G, Silvestri F: Primary small cell ('Oat cell') carcinoma of the larynx and hypopharynx. *ORL* **42**: 146-157, 1980
- 6) Vrouvas J, Ash DV: Extrapulmonary small cell cancer. *Clinical Oncology* **7**: 377-381, 1995
- 7) Baugh RF, Wolf GT, McClatchey KD: Small cell carcinoma of the head and neck. *Head & Neck Surgery* **8**: 343-354, 1986
- 8) Batsakis JG, El-Naggar AK, Luna M: Pathology consultation: Neuroendocrine tumors of larynx. *Ann Otol Rhinol Laryngol* **101**: 710-714, 1992
- 9) WHO: The World Health Organization histological typing of lung tumors. *Am J Clin Pathol* **77**: 123-6, 1982
- 10) Brenner B, Tang LH, Klimstra DS, Kelsen KD: Small cell carcinoma of the gastrointestinal tract: A Review. *J Clin Oncol* **22**: 2730-2739, 2004
- 11) Sengoz M, Abacioglu U, Salepci T, Eren F, Yumuk F, Turhal S: Extrapulmonary small cell carcinoma: Multimodality treatment results. *Tumori* **89**: 274-277, 2003
- 12) Galanis E, Frytak S, Lloyd RV.: Extrapulmonary small cell carcinoma. *Cancer* **79**: 1729-1736, 1997
- 13) Shamelian SOA, Nortier JWR: Extrapulmonary small-cell carcinoma: Report of three cases and update of therapy and prognosis. *The Netherlands J Med* **56**: 51-55, 2000
- 14) Auperin A, Arriagada R, Pignon JP, Le Pechoux C, Gregor A, Stephens RJ, Kristjansen PE, Johnson BE, Ueoka H, Wagner H, Aisner J: Prophylactic cranial irradiation for patients with small-cell lung cancer in complete remission. Prophylactic Cranial Irradiation Overview Collaborative Group. *N Engl J Med* **341**: 476-484, 1999