

## A Case of Multiple Myeloma with Hepatocellular Carcinoma

Ryosuke YAMAMOTO, Kazunari HINO, Masakiyo SHIMABARA, Seiji IDEGUCHI, Yasuhiro MITSUI, Yoshinori KONDO, Tsuneyo OHUMI, Keiko TAKATORI, Shinichiro YAMAMOTO, Yutaka HIRANO, Takashi SUGIHARA\* and Yoshihito YAWATA\*

*Division of Gastroenterology I, \*Division of Hematology, Department of Medicine, Kawasaki Medical School, Kurashiki 701-01, Japan*

*Accepted for publication on January 26, 1993*

**ABSTRACT.** We report here a 74-year-old man with multiple myeloma (MM) in combination with hepatocellular carcinoma (HCC). Recently, the incidence of MM in combination with another type of cancer has been increasing in Japan. It doubled from 590 in 1978-79 to 1090 between 1985-1989. Among such double cancers, the number of cases of MM combined with HCC has also increased. Although, loss of immunity due to the existence of MM or to anti-cancer drug therapy might cause such a combination, the relationship between immunity and the hepatitis virus as an important cause of HCC is unclear. Attention should be paid to MM as the possible cause of double cancers including HCC.

**Key words:** multiple myeloma — hepatocellular carcinoma — double cancer

Although, hepatocellular carcinoma (HCC) is said to be a sporadic complication of multiple myeloma (MM), its incidence has been increasing recently. We report a case of MM with HCC and discuss the incidence of double cancers and the reasons for their occurrence.

### CASE REPORT

A 74-year-old man with MM was admitted to the cardiology ward of Kawasaki Medical School Hospital in November 1991, with complaints of chest discomfort and general fatigue. One week later, after having fallen into a hepatic coma, he was transferred to the gastroenterology ward. Although he had experienced chronic liver damage 12 years earlier, there was no history of blood transfusion, excessive alcohol intake or drug ingestion, or only family history of liver disease. Physical examination showed the patient to be in a drowsy state, with flapping tremor, jaundice and hepatomegaly. Serum biochemistry findings were as follows; bilirubin 1.4 mg/dl, alkaline phosphatase 131 IU/l, cholesterol 119 mg/dl, albumin 2.1 g/dl, cholinesterase 95 IU/dl, GOT 74 IU/l, HPT 46%, NH<sub>3</sub> 138 μmol/l and platelets 10.8 × 10<sup>4</sup>/μl. HBsAg was negative, but HCV-RNA was positive (Table 1). Ultrasonography

TABLE 1. Laboratory data on the last admission

T-Bil	1.4 mg/dl	HBs-Ag	(-)
D-Bil	0.7 mg/dl	HCV-RNA	(+)
AIP	131 IU/l		
Cho	119 mg/dl	HPT	46%
$\gamma$ -GTP	33 IU/l	NH <sub>3</sub>	138 $\mu$ mol/l
LDH	178 IU/l		
Alb	2.1 g/dl	AFP	$7 \times 10^4$ ng/ml
M-Pro	3.69 g/dl	PIVKA-2	157.1 AU/ml
ChE	95 IU/dl		
GPT	17 IU/l	WBC	3100/ $\mu$ l
GOT	74 IU/l	RBC	$276 \times 10^4$ / $\mu$ l
Crn	1.1 mg/dl	Hb	10.4 g/dl
BUN	18 mg/dl	Ht	31.8 %
Amy	232 IU/l	Platelet	$10.8 \times 10^4$ / $\mu$ l

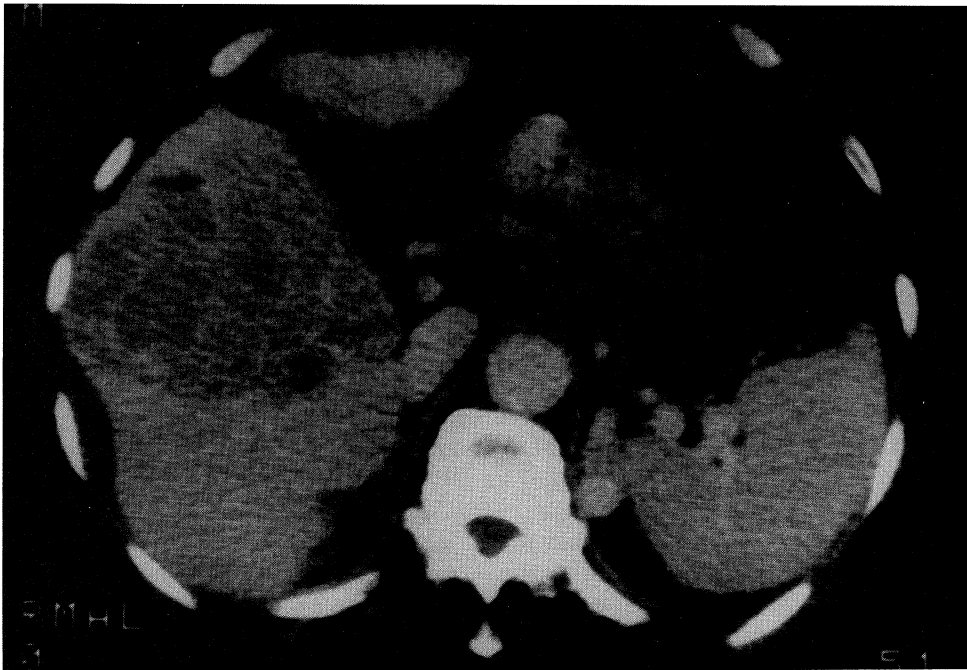

Fig. 1. X ray-CT shows liver cancer and liver cirrhosis

and CT (Fig. 1) disclosed a large liver cancer (10 cm) in an atrophic and granular right lobe and splenomegaly. Tumor markers were elevated; AFP  $7 \times 10^4$  ng/ml and PIVKA-2 157.1 AU/ml (Table 1). These findings indicated the patient was in a hepatic coma state due to liver cirrhosis with the HCC being caused by hepatitis C virus. Anti-hepatic coma treatment was begun, but the

coma deepened and he died 38 days after admission. A necropsy of the liver tumor showed HCC (Fig. 2). With regard to MM, he was first admitted to the hematology ward with hyperglobulinemia in June 1985. His serum biochemistry revealed IgG 2663 mg/dl and IgG-K type. However, although a bone marrow biopsy showed plasmocytosis, there was poor atypism and no nodular proliferation. Based on these findings, a diagnosis of benign M proteinemia was made and he was followed up in the patient out clinic. In 1986, he began to complain of left shoulder joint pain and lumbago due to an as yet undiagnosed a bone lesion of MM. In addition, the amount of M protein increased (IgG 3674 mg/dl). These new findings led to a new diagnosis of MM combined chemotherapy consisting of vindesine, prednisolone and ranimustine was begun. However, the response was poor, and his IgG continued to increase, reaching 4790 mg/dl at the time of death.

#### DISCUSSION

Recently, the number of the double cancers has been increasing in Japan. Warren and Gate<sup>1)</sup> suggested the following criteria for double cancers: 1) Each tumor must present a definite picture of malignancy. 2) Each tumor must be distinct. 3) The probability of one tumor being a metastasis of the other must be excluded. The present case was consistent with these criteria. Among the double cancers, the incidence of MM with another cancer is also increasing. Hashimura *et al.*<sup>2)</sup> indicated that out of 379 MM patients listed in the 19 (5%) were double cancers. Stomach cancer, lung cancer and thyroid cancer were the most common combined cancers, followed by liver cancer and kidney cancer, which were beginning to increase. As shown in Table 2, our investigation of 1798 MM patients listed in the Annual of the Pathological Autopsy Cases in Japan 1985-1989 revealed that 195 cases (10%) had double cancers. Thus the

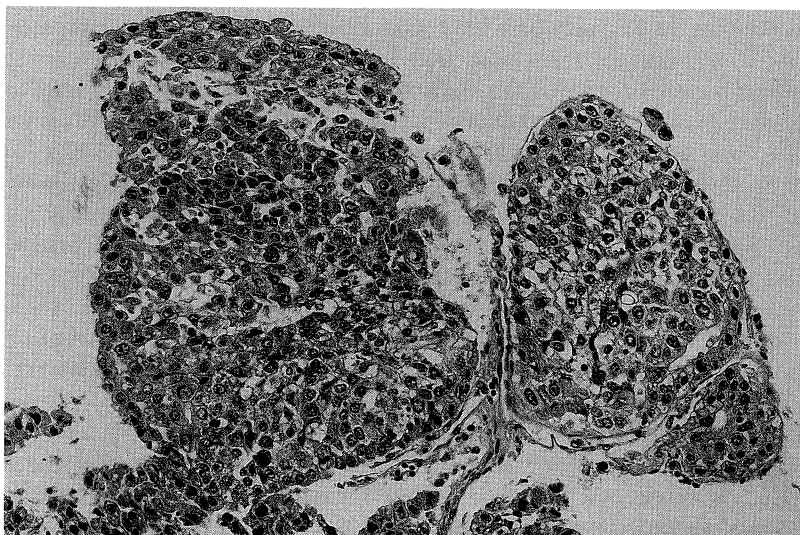


Fig. 2. The histologic findings of necropsy showed hepatocellular carcinoma ( $\times 25$ ).

TABLE 2. Cancers combined with autopsy cases of multiple myeloma according to the Annual of Pathological Autopsy Cases in Japan (1985-1989)

All Autopsy Case Number of Multiple Myeloma 1798			
Order	Site of Cancer	No	Ratio (%)
1	Stomach	46	2.6
2	Colon	25	1.4
3	Lung	24	1.3
4	Thyroid Gland	17	0.9
5	Prostate	16	0.9
6	Kidney	15	0.8
7	Esophagus	11	0.6
8	Liver	11	0.6
9	Blood	8	0.4
10	Pancreas	6	0.3
11	Uterus	6	0.3
12	Breast	4	0.2
13	Bladder	3	0.2
14	Ovary	1	0.06
15	Thymus	1	0.06
16	Gall Bladder	1	0.06
Total		195	10.8

incidence has doubled since Hashimura's report was made. Although, stomach cancer, lung cancer and thyroid cancer were the most common combinations as in Hashimura's report, the incidence of colon cancer was 1.4%, only second to that of stomach cancer (2.6%). The number of liver cancer was eleven (0.6%), ranking eighth. Including the present case, there were seven cases of MM with HCC reported in Japan between 1983 and 1992<sup>3-8)</sup> (Table 3). Comparison of these seven cases with patients who had liver cancer alone showed the age of the combined cases to be higher than that of patients with a single cancer. Generally, the average age of patients with liver cancer as a double cancer was 62.6 years, whereas that for cases with a single cancer was 59.1 years.<sup>9)</sup> Therefore it shows a similar tendency. With the exception of age, we could find no other differences in past reports, since almost all of those reports were very brief. Regarding the reasons for the development of double cancers with MM, Yasuma *et al.*<sup>10)</sup> suggested the following four factors. 1: This form of cancer is easily complicated by monoclonal gammopathy. 2: Secondary immune insufficiency due to MM might cause another cancer. 3: Anti-cancer therapy suppresses immunity and might cause cancer. 4: The existence of a common carcinogen. As far as HCC, it is well known that hepatitis virus types B and C are concerned the main carcinogens of HCC, and the present case showed HCV-RNA. However, at present, the relationships between the age at which HCC develops, the cause of double cancers and the existence of the hepatitis virus are poorly understood.

TABLE 3. Characteristics of multiple myeloma patients with hepatocellular carcinoma in Japan between 1983 and 1992

Case No	Year	Age	Sex	Reference No	M-protein	Hepatitis Virus
1	1983	73	M	3	IgG-K	B
2	1985	68	M	4	IgG-K	N.D.
3	1985	53	M	5	IgA-K	N.D.
4	1985	70	F	6	IgA-K	NON-B
5	1989	67	F	7	IgG-K	N.D.
6	1990	62	F	8	IgG-G	NON-B, NON-C
7	1992	74	M	This Case	IgG-K	C

N.D. : Not described

In conclusion, in cases of MM, examinations should be carried out to determine if a combined or second cancer, such as HCC exists, because the incidence of MM with another cancer is beginning to increase.

## REFERENCES

- 1) Warren, S. and Gates, O. : Multiple primary malignant tumors. *Am. J. Cancer* **16** : 1358-1414, 1932
- 2) Hashimura, S., Hashimoto, K. and Iwanaga, T. : An autopsy case of IgG-L type myeloma complicated with Grawitz's tumor. *Jpn. J. Clin. Hematol.* **20** : 1662-1667, 1979 (in Japanese)
- 3) Matsuura, K., Sakamoto, Y. and Yoshioka, A. : A case of double cancer complicated with HBsAg positive liver cirrhosis. *Jpn. J. Gastroenterol.* **80** : 152, 1983 (in Japanese)
- 4) Hino, N., Yokomichi, H. and Tsuchikawa, K. : A case of multiple myeloma which have lobulated nucleus myeloma cells with hepatocellular carcinoma. *Jpn. J. Intern. Med.* **74** : 139-140, 1985 (in Japanese)
- 5) Ida, K., Ichida, T. and Aoyama, K. : An autopsy case of hepatocellular carcinoma with malignant myeloma and paraneoplastic syndrome. *Jpn. J. Int. Med.* **74** : 85, 1985 (in Japanese)
- 6) Inoue, J., Nakanishi, S. and Nomura, M. : A case of multiple myeloma with hepatocellular carcinoma. *Jpn. J. Int. Med.* **75** : 143-144, 1986 (in Japanese)
- 7) Masui, H., Kajiwara, Y. and Tsuchiyama, H. : A case of Hepatocellular carcinoma with multiple myeloma. *Jpn. J. Gastroenterol.* **86** : 172, 1989 (in Japanese)
- 8) Shibata, A. : A case of hepatocellular carcinoma and MDS developing after the treatment of multiple myeloma. *Shindan to Chiryō* **78** : 2899-2907, 1990 (in Japanese)
- 9) Nakajima, T., Kojiro, M. and Sugihara, S. : Pathological study of primary liver cancer. *Kurume Med. J.* **47** : 548-560, 1984 (in Japanese)
- 10) Yasuma, A., Nakashima, I. and Muramatsu, M. : A case of multiple myeloma associated with operated stomach cancer. *Jpn. J. Clin. Hematol.* **14** : 714-720, 1973 (in Japanese)