

KAWASAKI MED. J. VOL. 13 : NO. 1, 39-41 (1987)

## Measurement of Ionized Calcium as Supplementary Marker of Bone Metastasis in Breast Cancer

Masao FUKUNAGA, Nobuaki OTSUKA, Shimato ONO,  
Kiyohisa NAGAI, Takako FURUKAWA, Toshihiro OHAMA,\*  
Hiroshi SONOO,\* Tsuneaki SENOO\* and Rikushi MORITA

*Department of Nuclear Medicine and \*Endocrine Surgery,  
Kawasaki Medical School, Kurashiki 701-01, Japan*

*Accepted for Publication on January 29, 1987*

**ABSTRACT.** The serum concentrations of ionized calcium (iCa), corrected automatically for serum pH, were measured in 67 cases with breast cancer (16 positive cases and 51 negative cases for bone metastasis). The serum concentration of iCa in the cases of positive bone metastasis was significantly higher than that in the negative cases ( $p < 0.005$ ). As osteoclastic bone metastasis occurred frequently in breast cancer, the measurements of serum concentrations of iCa might be of help as a supplementary marker of the diagnosis of bone metastasis.

**Key words :** ionized calcium — bone metastasis — breast cancer

It is well known that bone metastasis is often found in breast cancer. According to postmortem findings, bone metastasis was reported in 85% of the cases.<sup>1)</sup> On plain X-ray of the bone, it is impossible to recognize the existence of metastasis unless more than 30-50% of bone mineral has been changed. On the other hand, bone scintigraphy using <sup>99m</sup>Tc-labeled phosphate compound is the most sensitive technique for the assessment of bone metastasis in malignant tumors.<sup>2)</sup> However, this method produces some false positive results. Therefore, some procedures have been attempted to get higher reliability.<sup>3)</sup> In this study, iCa concentrations in patients with breast cancer were measured and the usefulness in the diagnosis of bone metastasis was evaluated.

### MATERIALS AND METHODS

Sixty-seven cases with breast cancer were studied. Bone scintigraphy using <sup>99m</sup>Tc-methylene diphosphonate 20 mCi was performed, and 3 hrs later, in addition to the whole body image, spot images were obtained by a gamma camera (Hitachi Gamma View T). Diagnosis of bone metastasis was done on the basis of the findings on X-ray tomography and CT scanning as well as bone scintigraphy. With the above methods the breast cancer patients were classified to 2 groups; 16 cases with positive bone metastasis (age,  $53.7 \pm 10.7$  yrs. mean  $\pm$  S.D.), and 51 cases with negative bone metastasis ( $56.7 \pm 12.1$  yrs.). The number of the involved bone in the positive group was  $5.4 \pm 3.3$ .

Blood was collected anaerobically, and centrifuged. The iCa concentration in the separated serum was measured by a Calcium Ion Analyzer (ANALYTE +2, Baker Instruments Corp.). The reproducibility in this system was extremely

福永仁夫, 大塚信昭, 小野志磨人, 永井清久, 古川高子, 大浜寿博, 園尾博司, 妹尾亘明, 森田陸司

good ; 0.8% of C.V. for intra-assay (N=5) and 1.5% for inter-assay (N=3). The serum iCa concentrations of the 2 groups (positive and negative bone metastasis) were compared. Statistical evaluation was done by Student' t test.

### RESULTS AND DISCUSSION

The serum iCa concentrations in the patients with breast cancer are shown in Fig. 1. The serum iCa concentration in the cases of positive bone metastasis was  $1.219 \pm 0.080$  mmol/L, while that of the negative group was  $1.151 \pm 0.051$  mmol/L. The concentration in the positive group was significantly higher than that in the negative group ( $p < 0.005$ ). Also, the overlap between 2 groups was observed.

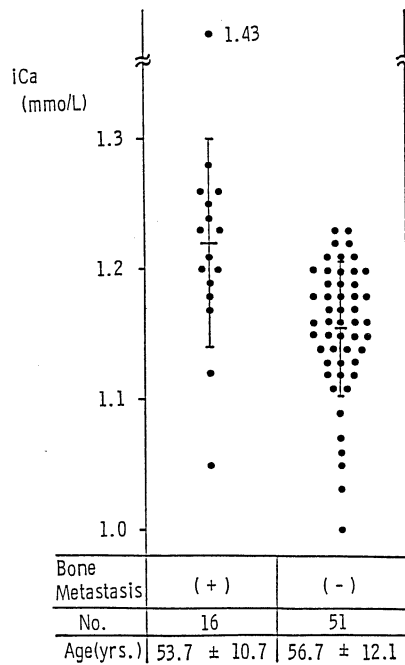


Fig. 1. Serum iCa concentrations in breast cancer. Significant difference between positive bone metastasis group and negative group was recognized ( $p < 0.005$ ).

Of the various methods of diagnosing bone metastasis in breast cancer, bone scintigraphy is the most sensitive to detect the bone lesion. However, it is sometimes difficult to differentiate metastasis from benign bone lesions, such as compression fracture of vertebrae due to osteoporosis, microfracture of ribs, senile bone degeneration, etc. It is also expensive to repeat frequently the examinations. Therefore, efforts has been devoted to get more reliable marker. For example, measurement of the various physiological parameters of the blood, such as alkaline phosphatase,<sup>4)</sup> acid phosphatase<sup>5)</sup> or bone  $\gamma$ -carboxyglutamic acid.<sup>6)</sup> However, most parameters can not discriminate between bone metastasis and other pathological states, and were not diagnostic.

Total serum calcium was comprised with ionized, protein binding and diffusible complexed calcium. Among them the critical value is the level of iCa. The level of iCa determines the physiologic and pathologic consequences more accurately than total calcium measurement. Level of iCa was varied with the change of serum pH. The calcium ion analyzer used in this study was equipped to display iCa concentration corrected by pH, and the reproducibility of the measured value of iCa was shown to be excellent from the fundamental study. Increased serum Ca level results from acceleration in the rate of bone resorption with mobilization of Ca from the bone into the serum. Therefore, osteolytic lesions are more prone to be associated with hypercalcemia. In breast cancer, both osteoblastic bone metastasis, and combination of osteoblastic and osteoclastic metastasis can be occurred. However, the incidence of osteoclastic bone metastasis is by far the highest.<sup>7)</sup> Also, hypercalcemia resulting from the osteoclastic bone metastasis has been often experienced in breast cancer. Therefore, to monitor whether osteoclastic bone metastasis exists or not, the measurements of the iCa concentration is reasonable. In this study, it was shown that the iCa concentrations in positive bone metastasis group was significantly higher than the negative group. Although, like the other marker, the measurements of serum iCa concentrations lack the specificity, it was considered to be of help as a supplementary marker of the diagnosis of bone metastasis.

#### REFERENCES

- 1) Jaffe, H.L.: Tumours and tumourous conditions of the bones and joints. London, Kimpton. 1958
- 2) Cambell, D.J., Banks, A.J. and Davies, G.D.: The value of preliminary bone scanning in staging and assessing the prognosis of breast cancer. *Br. J. Surg.* **63** : 811-816, 1976
- 3) McNeil, B.J.: Rationale for the use of bone scans in skeletal metastatic and primary bone tumours. *Semin. Nucl. Med.* **8** : 336-345, 1978
- 4) Cowan, R.J. and Young, K.A.: Evaluation of serum alkaline phosphatase determination in patients with positive bone scans. *Cancer* **32** : 887-889, 1973
- 5) Tavassoli, M., Rizo, M. and Yam, L.T.: Elevation of serum acid phosphatase in cases with bone metastasis. *Cancer* **45** : 2400-2403, 1980
- 6) Price, P.A., Parthemore, J.G., Deftos, L.J. and Nishimoto, S.K.: New biochemical markers for bone metabolism. *J. Clin. Invest.* **66** : 873-883, 1980
- 7) Adams, J.E. and Isherwood, I.: Conventional and new techniques in radiological diagnosis. *In* Bone metastasis: monitoring and treatment, ed. by Stoll, B.A. and Parbholl, S. New York, Raven Press. 1983, pp. 107-148