

KAWASAKI MED. J. VOL. 11 : NO. 4, 241-244 (1985)

**Brief Note****Histopathological Studies on Contact Dermatitis. IV.  
The Epidermal Distribution of IgG and Ia Antigen  
in Experimental Contact Dermatitis***Accepted for Publication on September 2, 1985***Key words : DNCB — Contact dermatitis — IgG — Ia antigen**

Ia antigens are detectable only on Langerhans cells in the normal epidermis. Recently the expression of Ia antigens on the keratinocyte surface has been reported in several skin diseases, i. e., graft-versus-host disease, lichen planus, mycosis fungoides, psoriasis, pityriasis rosea and contact dermatitis. Experimental demonstration of Ia antigens on the keratinocytes was reported in graft-versus-host disease<sup>1-4)</sup> and contact sensitivity<sup>5,6)</sup> of rats and mice. However, we still have little information as to the exact mode of the Ia antigen expression on the keratinocyte surface in contact sensitivity especially in guinea pigs. The objective of experiments in this report is to demonstrate the Ia antigen expression on the keratinocytes in various kinds of contact dermatitis to 2,4-dinitrochlorobenzene (DNCB) of guinea pigs. The indirect immunofluorescent (IF) procedure was carried out using strain-2anti-strain 13 alloantisera (anti-Ia) and FITC-labeled anti-guinea pig IgG antisera (FITC-anti-IgG).

Male inbred strain 13 guinea pigs were painted with 0.01 ml of 5% DNCB-ethanol solution. The other groups of guinea pigs were sensitized to DNCB by an application of 0.025 ml of 5% DNCB-ethanol solution and tested for contact sensitivity by application of 0.01 ml of 0.2% DNCB-ethanol solution 7 days later. An animal group of them was retested by epicutaneous application of 0.01 ml of 0.2% DNCB at the sites of prior contact reaction 7 days after skin testing. Biopsy specimens from these DNCB application sites were obtained 3, 6 and 9 hours and 1, 3, 6 and 10 days after painting and unfixed frozen sections were prepared from the specimens. Anti-Ia was prepared as described previously.<sup>7)</sup> Ia antigen expression on the keratinocytes was investi-

TABLE. The epidermal distribution of IgG and Ia antigen in various kinds of contact dermatitis to DNCB in JY-1 strain guinea pigs.

Contact dermatitis*	Distribution of	Time after DNCB application						
		3 h	6 h	9 h	1 d	3 d	6 d	10 d
Primary irritant	IgG	+--	+--	+--	+--	+++	+++	+--
	Ia	?--	?--	?--	?--	???	???	?-?
Allergic	IgG	---	---	---	+--	+--	---	-
	Ia	---	---	+--	?--	?--	---	-
Retest reaction	IgG	---	+--	+--	---	---	---	---
	Ia	---	?--	?--	---	---	---	---

\*Three animals were used in each experiment.

中川昌次郎, 長田浩行, 武井洋二, 岡 大介, 植木宏明

gated by the conventional indirect IF method using anti-Ia and FITC-anti-IgG. For control, the deposition of guinea pig IgG in the skin of the contact dermatitis was observed by the direct IF technique using FITC-anti-IgG.

Keratinocytes were successfully observed to express Ia antigen on their cell surface only in one specimen which was obtained from the lesion of allergic contact dermatitis 9 hours after challenge with DNCB (Fig. 1, Table). Aiba *et al.*<sup>6)</sup> recognized the expression of Ia antigen on the keratinocyte surface in all of 40 specimens from 3 to 9 days after application of 2, 4, 6 trinitrochlorobenzene to the skin of sensitized mice. It is suggested that expression of Ia antigen on the keratinocytes occurs in amounts too low to be detected by our method.

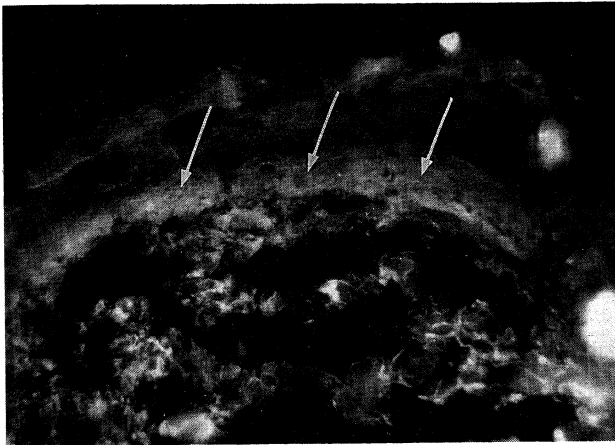


Fig. 1. Nine hour-lesion of allergic contact dermatitis. Ia antigen expression on the keratinocytes in unfixed frozen section, recognized as epidermal intercellular fluorescent staining with anti-Ia antibody (arrows,  $\times 200$ ).

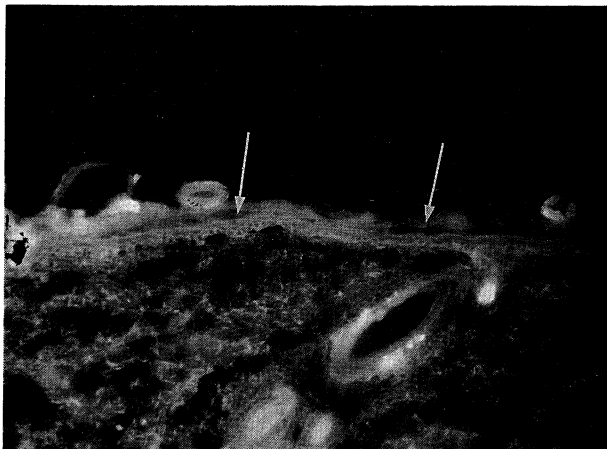


Fig. 2. Three hour-lesion of primary irritant contact dermatitis. IgG deposition in epidermis, recognized as epidermal intercellular fluorescent staining with anti-IgG antibody (arrows,  $\times 100$ ).

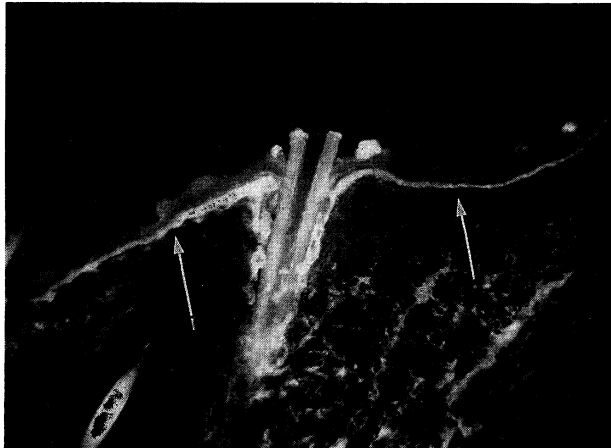


Fig. 3. Three day-lesion of primary irritant contact dermatitis. IgG deposition is confined to the upper rete (arrows,  $\times 100$ ).

On the other hand, deposition of IgG in epidermis was seen in the greater part of specimens taken from primary irritant contact dermatitis (Figs. 2, 3, Table). The deposition became confined to the upper rete 3 days after painting with DNCB or later (Fig. 3). Demonstration of Ia on the keratinocytes by the indirect IF procedure was disturbed by the deposition of IgG. So it is not clear whether the expression of Ia antigen on the keratinocytes in primary irritant contact dermatitis actually occurs or not by the IF method. Suitters and Lampert<sup>5)</sup> noted the Ia antigen expression on the keratinocytes surface only in contact sensitivity to 2,4-dinitrofluorobenzene, but not in croton oil irritant dermatitis. Further studies must be done using the adequate technique to detect Ia antigen expression on keratinocytes.

#### Acknowledgment

This work was supported by a Kawasaki Medical School grant (No. 60-203) for project research.

**Shojiro NAKAGAWA, Hiroyuki NAGATA,  
Yoji TAKEI, Daisuke OKA and Hiroaki UEKI**

*Department of Dermatology,  
Kawasaki Medical School,  
Kurashiki 701-01, Japan*

#### REFERENCES

- 1) Lampert, I.A., Suittses, A.J. and Chisholm, P.M. : Ia antigen expression epidermal keratinocytes in graft-versus-host disease. *Nature* **293** : 149-150, 1981
- 2) Mason, D.W., Dallman, M. and Barclay, A.M. : Graft-versus-host disease induces expression of Ia antigen in rat epidermal cells and gut epithelium. *Nature* **293** : 150-151, 1981

- 3) Daynes, R.A., Emam, M., Krueger, G.G. and Roberts, L.K. : Expression of Ia antigen on epidermal keratinocytes after the grafting of normal skin to nude mice. *J. Immunol.* **130** : 1536-1539, 1983
- 4) Breathnach, S.M. and Katz, S.I. : Keratinocytes synthesize Ia antigen in acute cutaneous graft-vs-host disease. *J. Immunol.* **131** : 2741-2745, 1983
- 5) Suitters, A.J. and Lampert, I.A. : Expression of Ia antigen on epidermal keratinocytes is a consequence of cellular immunity. *Br. J. Exp. Pathol.* **63** : 207-213, 1982
- 6) Aiba, S., Aizawa, H., Obata, M. and Tagami, H. : Dynamic changes in epidermal Ia-positive cells in allergic contact sensitivity reactions in mice. *Br. J. Dermatol.* **111** : 507-516, 1984
- 7) Oka, D., Nakagawa, S. and Ueki, H. : The suppressive effect of tape-stripping treatment of guinea-pig skin on the induction of contact sensitivity by intradermal injection of haptened epidermal cells. *Arch. Dermatol. Res.* (in press)