

## Glandular Inclusion in the Periprostatic Nerve Ganglion

Toshiaki MANABE, Takashi FUKUYA, Takuya MORIYA  
and Keiko TASAKA

*Department of Pathology, Kawasaki Medical School,  
Kurashiki 701-01, Japan*

*Accepted for Publication on May 29, 1985*

**ABSTRACT.** The presence of epithelial cells in the nerve tissue is generally regarded as indicative of malignant neoplasia in the prostate, although it may be encountered in the benign breast lesions. Recently, however, we have observed a normal-looking prostatic gland epithelium in the nerve ganglion near hyperplastic prostate. This case, therefore, indicates that benign epithelial-nerve intermingling may occur in the prostatic tissue and that the identification of epithelial cells within nerves as malignant should be more careful in the prostatic gland as is in the breast tissue.

**Key words :** Glandular inclusion — Nerve ganglion —  
Epithelial-nerve intermingling — Prostate

Perineural invasion by epithelial cells is generally used as a criterion of the malignancy and/or its extension. Several reports, however, have indicated that such a finding may be associated with non-malignant breast lesions.<sup>1-4)</sup> These features have been variously designated. Gould *et al.*<sup>1)</sup> coined a descriptive term of epithelial-nerve intermingling. To our knowledge, a similar phenomenon has been observed only in a few other organs. This brief communication describes a case with glandular inclusion in the periprostatic nerve ganglion which was found incidentally by the postmortem examination. We like to emphasize that the epithelial-nerve intermingling may be seen in non-breast tissue, as well, and that even in proved cases of carcinoma, the identification of these cells as malignant should be cautious unless they show convincingly atypical histological feature.

### REPORT OF A CASE

A 59-year-old man with repeated episodes of pneumonia had been followed by a local doctor during nine months before the admission. Because of increasing pulmonary shadows on chest x-ray, the patient was transferred to our hospital on May 25, 1984. Physical examination on admission was all negative except for mild rhonchi in the posterior lung field. The white cell count was 7,600 with 12% band, and 66% segmented neutrophils. The blood glucose was 150 mg/dl, serum protein 6.2 g (the albumin 3.9 g, the globulin 2.3 g) per 100 ml, LDH 117 IU/L, and CEA 3.4 ng/ml. Blood gas showed pH 7.46, pO<sub>2</sub> 49.8 mmHg, and pCO<sub>2</sub> 31.5 mmHg. Chest x-ray revealed a diffuse consolidation in the right lower lobe and the sputum cytology adenocarcinoma cells. In the mean time, high fever developed and persisted. The

---

真鍋俊明, 福屋 崇, 森谷卓也, 田坂佳子

patient was emaciated and chemotherapy could not be instituted. On July 2, urinary incontinence and disorientation was noted and the brain CT showed a mass lesion measuring  $3 \times 3$  cm in diameter in the right frontal lobe. Radiation was given to the metastatic tumor in the brain. The patient's condition deteriorated further with respiratory failure. He died about two months after admission.

#### AUTOPSY FINDINGS

Postmortem examination confirmed the presence of bronchiolo-alveolar carcinoma involving the right lower lobe with pleuritis carcinomatosa. Metastatic lesions were present in vertebrae (Th 5-9 and Th 10 as well as L 1-4), adrenal glands, kidneys and liver. Pulmonary hilar, and para-aortic lymph nodes also contained metastatic tumors. The prostate was hypertrophic with glandular and stromal proliferation. Glands were markedly dilated. It was completely free of cancer metastasis or primary prostatic carcinoma. At the edge of the prostatic tissue, there were several nerve bundles and nerve ganglia. One of

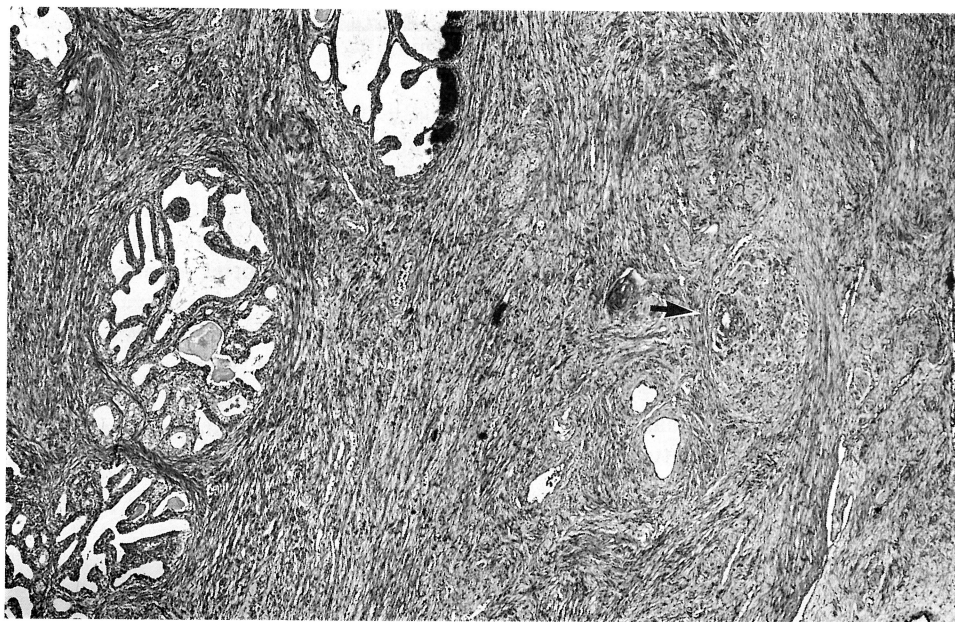


Fig. 1. Low power view of the prostatic capsule, showing nerve ganglia with a glandular inclusion (arrow). (H-E,  $\times 40$ )

the ganglia contained a small gland (Fig. 1, arrow). This glandular structure located at the periphery of the ganglion and was surrounded directly by ganglionic tissue. No apparent lymphatic or vascular endothelium was noted in between. The epithelial cells were low columnar in shape with fluffy luminal border and gave some resemblance to the prostatic epithelium. These cells possessed small, slightly vesicular nuclei and did not display any atypical features (Fig. 2). No morphological similarities to the cells of bronchiolo-alveolar carcinoma in the lung were recognized.

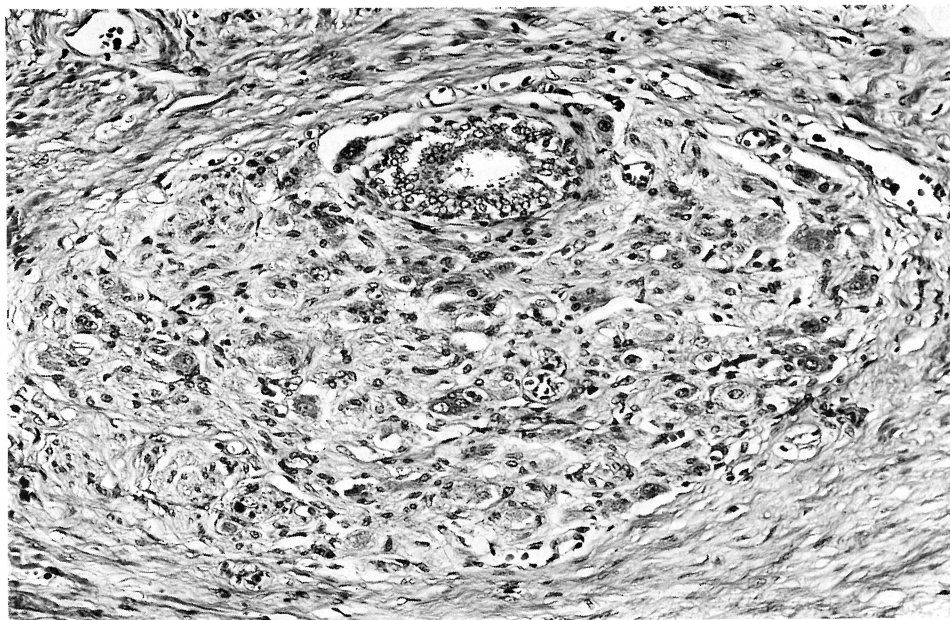


Fig. 2. Higher magnification of the nerve ganglion seen in Fig. 1. Note that a glandular structure is directly surrounded by ganglionic tissue. (H-E,  $\times 200$ )

#### DISCUSSION

The presence of non-malignant or non-metastatic epithelial cells is known in apparently normal tissue or benign lesions. For example, benign glandular inclusions may occur in pelvic,<sup>5,7)</sup> para-aortic,<sup>5,7)</sup> inguinal,<sup>5)</sup> iliac,<sup>7)</sup> axillary<sup>8)</sup> and bronchopulmonary<sup>9)</sup> lymph nodes, exclusively in females. The exact nature of these inclusion remain uncertain. Various theories have been entertained; (1) lymphatic transported endometrial tissue, (2) müllerian metaplasia of coelomic epithelium and (3) congenital rest.

Intermingling of epithelial cells and nerve tissue has been generally called "perineural lymphatic invasion" and regarded as indicative of malignancy. However, several investigators<sup>1-4)</sup> have reported such an intermingling in the non-malignant breast lesions. Ackerman<sup>1)</sup> made such an observation for the first time in 1957 and this was confirmed by Taylor and Norris who reported the incidence of 2% in 1,000 consecutive breast specimens of sclerosing adenosis. Lutman<sup>10)</sup> described histologically benign epithelial cells abutting on the nerve bundles simulating perineural invasion in patients with oral carcinoma. These changes have been variously designated; namely benign nerve-sheath invasion, epithelial invasion of the nerve in benign disease of the breast and epithelial-nerve intermingling in benign breast lesion. To merely describe the presence of a single glandular structure within a ganglion, we chose a more non-specific term of glandular inclusion but we regard it as essentially the same as the phenomenon mentioned earlier.

In contrast to the breast lesions, the intermingling of glandular epithelium and nerve tissue is often regarded as a criterion of malignancy in prostatic tissue when cellular anaplasia is equivocal or absent. Mostofi and Price,<sup>11)</sup>

however, drew an attention to the intimate relationship between nerve bundle and prostatic acini within the prostate where the two structures are separated only by the acinar basement membrane. On the other hand, they stated that invasion of the prostatic capsule, periprostatic soft tissues, and the bladder wall is obviously indicative of an aggressive, malignant tumor. Contrary to these statements, our case clearly demonstrated that benign intermingling may occur even in the prostatic capsule.

The term perineural invasion is misnomer. Investigations with the light and electron microscopy<sup>11-13)</sup> have not substantiated the presence of perineural lymphatics. Instead, it is suggested that perineural connective tissue is loose enough to provide the path of lessened resistance of the growth of neoplastic cells. Likewise, Gould *et al.*<sup>4)</sup> speculated that epithelial cells may be displaced, become intimately related to nerves during synchronous, active epithelial proliferation and fibrogenesis, and subsequently continue to grow in that location. Therefore, similar mechanism may be operative in benign proliferative prostatic lesions such as glandular and stromal hyperplasia.

At any rate, this case alerts the pathologist to realize that benign epithelial-nerve intermingling may occur in the prostatic tissue and that such finding should be cautiously evaluated even in proved cases of carcinoma.

#### REFERENCES

- 1) Ackerman, L.V. : Seminar on lesions of the breast (case 20). *In* Proceedings of the 22nd Seminar of the American Society of Clinical Pathologists. Chicago. 1957, pp. 65-70
- 2) Taylor, H.B. and Norris, H.J. : Epithelial invasion of nerves in benign diseases of the breast. *Cancer* 20 : 2245-2249, 1967
- 3) Haagensen, C.D. : Diseases of the breast. Philadelphia, W.B. Saunders, Co. 1971, pp. 179, 183
- 4) Gould, V.E., Rogers, D.R. and Sommers, S.C. : Epithelial-nerve intermingling in benign breast lesions. *Arch. Pathol.* 99 : 596-598, 1975
- 5) Karp, L.A. and Czernobilsky, B. : Glandular inclusions in pelvic and abdominal para-aortic lymph nodes. *Am. J. Clin. Pathol.* 52 : 212-218, 1969
- 6) Kempson, R.L. : Benign glandular inclusions in iliac lymph nodes. *Am. J. Surg. Pathol.* 2 : 321-325, 1978
- 7) Kheir, S.M., Mann, W.J. and Wilkerson, J.A. : Glandular inclusions in lymph nodes. The problem of extensive involvement and relationship to salpingitis. *Am. J. Surg. Pathol.* 5 : 353-359, 1981
- 8) Siltan, R.M. : More glandular inclusions. *Am. J. Surg. Pathol.* 3 : 285-286, 1979
- 9) Lin, C.S. : Benign glandular inclusions. *Am. J. Surg. Pathol.* 4 : 413, 1980
- 10) Lutman, G.B. : Epithelial nests in intraoral sensory nerve endings simulating perineural invasion in a patients with oral carcinoma. *Am. J. Clin. Pathol.* 61 : 275-284, 1974
- 11) Mostofi, F.K. and Price, E.B., Jr. : Tumor of the male genital system. Atlas of tumor pathology, Second series, Fascicle 8. Washington, D.C., Armed Forces Institute of Pathology. 1973, pp. 209-216
- 12) Larson, D.L., Rodin, A.E., Roberts, D.K., O'Steen, W.K., Rapperport, A.S. and Lewis, S.R. : Perineural lymphatics—myth or fact. *Am. J. Surg.* 112 : 488-492, 1966
- 13) Rodin, A.E., Larson, D.L. and Roberts, D.K. : Nature of the perineural space invaded by prostatic carcinoma. *Cancer* 20 : 1772-1779, 1969
- 14) Hassan, M.D. and Maksem, J. : The prostatic perineural space and its relation to tumor spread. An ultrastructural study. *Am. J. Surg. Pathol.* 4 : 143-148, 1980