

Rev. Fac. Med. vet. Zootec. Univ. S. Paulo
14(1):77-78, 1977

DOUBLE ESOPHAGEAL DIVERTICULUM IN DOG

Masao IWASAKI *
Benedicto Wladimir DE MARTIN *
José ALVARENGA ***
Mitika HAGIWARA ****

RFMV-A/9

IWASAKI, M.; ALVARENGA, J.; DE MARTIN, B.W.; HAGIWARA, M. *Double esophageal diverticulum in dog.* Rev. Fac. Med. vet. Zootec. Univ. S.Paulo, 14(1): 77-78, 1977.

SUMMARY: *A case of double esophageal diverticulum in a female Pinscher 4 years old is described. Radiographic examination associated to necrological aspects and clinic symptoms are presented.*

UNITERMS: *Radiography *; Esophageal diverticulum *; Surgery dogs *.*

INTRODUCTION

Esophageal diverticuli, classified according to its type like diverticuli of pulsation traction or congenital^{2,5}, occur rarely in little animals; this can be verified through the consulted literature^{2,4}, and it was not found citation about case of double diverticulum.

CASE REPORT

It is a case of a female 4 years old Pinscher with bad general conditions presenting symptoms of mediate and sporadic vomitings, even after ingestion of liquid food, inspiratory dyspnoea, posture determining kyphosis of dorsal and lombar portions of spinal cord, rigid posterior

members and tottering walking. These symptoms were more evident after ingestion of food.

The owner informed about antecedents that suggested complications of respiratory and digestive system, involving to cure, through symptomatic medication.

Preliminary radiographic examinations showed at left lateral-lateral position, by difference of density spherical shape formations, overlaid at anterior-diaphragmatic region containing gases and solid particles.

At ventral-dorsal radiographies these formations were isolated, occupying opposed positions regarding last portion of toracic esophagus.

By means of radiographic

* Professor Assistente.

** Professor Assistente Doutor.

*** Professor Livre-Docente.

Departamento de Cirurgia e Obstetrícia da Faculdade de Medicina Veterinária e Zootecnia da Universidade de São Paulo.

**** Professor Assistente.

Departamento de Patologia e Clínica Médica da FMVZ.

examinations of contrasted esophagus by barium sulphate solution, it was verified that these formations were parts of this organ because they communicated with its lumen, what permitted to conclude it was a double esophageal diverticulum.

Surgical correction of diverticuli^{1,5}, was proposed, but the animal did not resist to first help because of its precarious general conditions.

Owing necroscopy it was observed that diverticuli were adhered to the diaphragmatic lobes of lungs, pericardium and diaphragm.

Histopathological examination of diverticuli showed esophageal structure, with chronic inflammatory of the mucosa.

DISCUSSION

The report about esophageal diverticulum does not mention its origin⁵, and other literatures describe 3 types of formations of these processes^{3,5}, and this present report it can be suggested the matter be a traction diverticulum, resulted by adhesive esophageal surroundings⁶.

Passed clinic history with respiratory and digestive complications corroborates this hypothesis.

At this service we found 439 cases with cats and dogs, where they were studied esophageal pathologies, through help of radiographic techniques⁴, it was found only this case of diverticulum.

It must be emphasized, still, the importance of radiographic examination at the elucidation of different etiologies of esophageal processes.

RFMV-A/9

IWASAKI, M.; ALVARENGA, J.; DE MARTIN, B.W.; HAGIWARA, M. *Duplo divertículo esofágico em cão*, Rev. Fac. Med. vet. Zootec. Univ. S.Paulo, 14(1): 77-78, 1977.

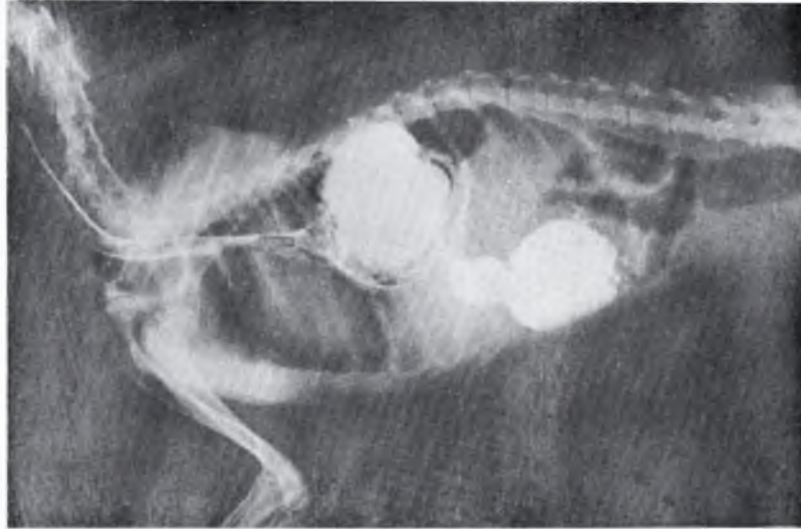RESUMO: *É descrito um caso de duplo divertículo esofágico em uma cadela Pinscher, de 4 anos de idade, apresentando o quadro radiográfico associado ao exame necroscópico e sintomas clínicos.*

UNITERMOS: *Radiografia *; Cirurgia, cães *; Esofago divertículo *.*

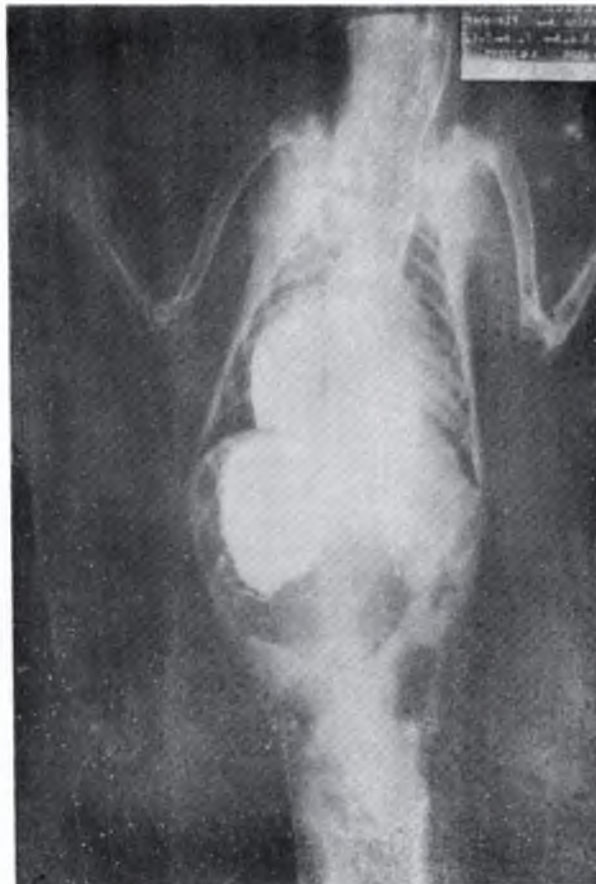REFERÊNCIAS BIBLIOGRÁFICAS

- 1 - ALLAN, M.V. & MARTIN, J.E. Thoracic invasion of the esophages for the repair of diverticula or removal of foreign bodies. Proc. Bk. Amer. vet. med. Ass., (262/4): 262-64, Aug., 1954.
- 2 - ARCHIBALD, J. Canine surgery. California, American Veterinary Publications, 1965. p.458-460.
- 3 - CARLSON, W.D. Veterinary radiology. Philadelphia, Lea & Febiger, 1967. p.251-63.
- 4 - DE MARTIN, B.W. Interpretação radiológica nas alterações do aparelho digestivo nas espécies canina e felina. Rev. Fac. Med. vet. Zootec. Univ. S.Paulo, 8: 337-57, 1969.
- 5 - REED, J.H. & COBB, L.M. The diagnosis radiographic study and surgical relief of a case of oesophageal diverticulum. Canad. Vet. J., 1(7): 323-5, 1960.
- 6 - ROBBINS, S.L. Patologia com aplicação médica. Rio de Janeiro, Guanabara Koo gan 1965. p.679-80.

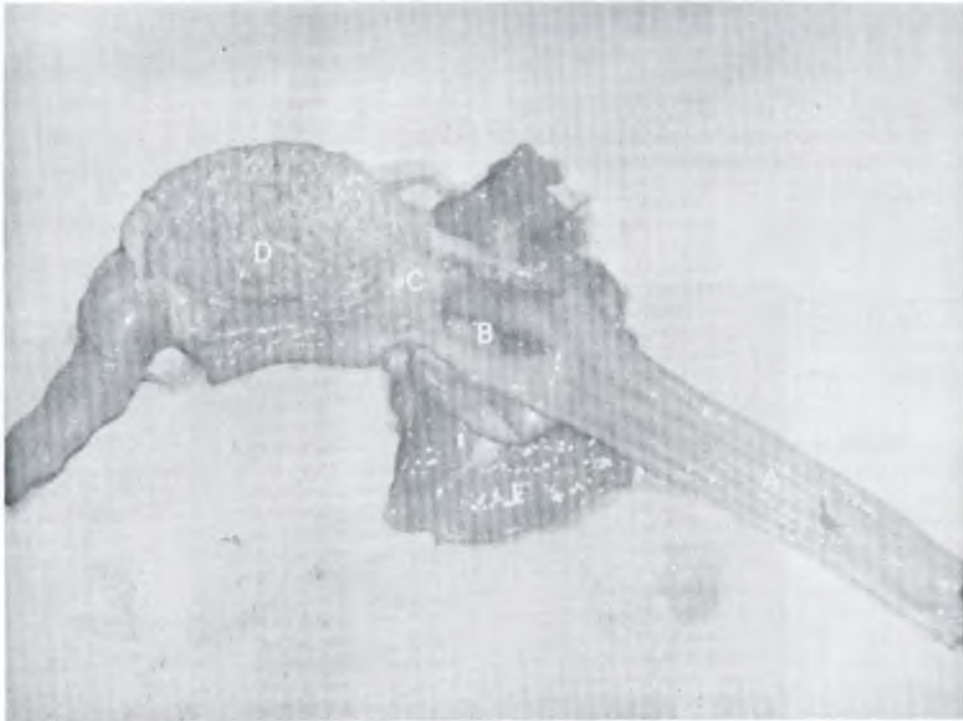
Recebido para publicação em 10-3-77
Aprovado para publicação em 3-8-77



Lateral lateral contrasted radiographic aspects, evidencing formations coated by radiological contrast, relating to esophagus.



Ventral dorsal radiographic aspects, showing formations projecting laterally to the esophagus.



Photographic aspects of gastric esophageal segment, showing: A – esophagus – B – opening of diverticuli – C – cardia – D – stomach – E – diaphragm.