

Artifact induction by endodontic materials: a CBCT analysis

• **Fernanda C. S. Salineiro** PhD, Department of Stomatology, School of Dentistry, University of São Paulo, São Paulo, SP, Brazil • **Igor P. Talamoni** DDS, Department of Stomatology, School of Dentistry, University of São Paulo, São Paulo, SP, Brazil • **Solange Kobayashi-Velasco** MS Student, Department of Stomatology, School of Dentistry, University of São Paulo, São Paulo, SP, Brazil • **Fabiana M. Barros** PhD, Department of Stomatology, School of Dentistry, University of São Paulo, São Paulo, SP, Brazil • **Marcelo G. P. Cavalcanti** PhD, Professor, Department of Stomatology, School of Dentistry, University of São Paulo, São Paulo, SP, Brazil

ABSTRACT | Metallic objects, such as intracanal posts and restorations, may produce severe interference, thus diminishing the quality of CBCT imaging. Objective: The purpose of this study was to analyze the influence of conventional and bioceramic gutta-percha points on the production of artifacts in CBCT images. Methods: Extracted single-rooted premolar teeth (n=20) were instrumented and scanned with a CBCT device to create three groups: the Control group, the Gutta-Percha group and the Bioceramic Gutta-Percha group. Two types of analysis were executed: an objective one, using the Region of Interest (ROI) to measure the pixel density of each tooth, and a subjective one, to compare the groups' images. For the statistical analysis, Student's t-test, descriptive statistics and the frequency distribution analysis were used for both objective and subjective analyses. Results: The agreement between the observers ranged from moderate to excellent. Similar grayscale values were obtained in both the GP and BCGP groups. These results were endorsed by the p-values obtained with Student's t test. For the subjective analysis, the observers indicated the BCGP group as the one that developed the highest number of artifacts. Conclusions: Both materials produced artifacts in the CBCT images. However, in the subjective analysis, the BCGP group showed higher levels of artifact production than the GP group, which could result in the misdiagnosis of root fracture and in a worse prognosis for that tooth.

DESCRIPTORS | Tomography; X-ray Computed; Gutta Percha; Root Canal Obturation; Artifacts.

RESUMO | **Indução de artefato por materiais endodônticos: uma análise de TCFC** • Objetos metálicos, tais como retentores intrarradiculares e restaurações, podem produzir interferência grave, assim, diminuindo a qualidade de imagem TCFC (Tomografia Computadorizada de Feixe Cônico). Objetivo: o propósito deste estudo foi analisar a influência de cones de gutta-percha convencionais e de biocerâmica na produção de artefatos nas imagens TCFC. Métodos: um dente pré-molar unirradicular extraído (n=20) foi instrumentalizado e escaneado com aparelho TCFC criando três grupos: o grupo Controle (C), o grupo Gutta-Percha (GP) e o grupo Gutta-Percha de Biocerâmica (GPB). Foram executados dois tipos de análises: uma objetiva, usando a Região de Interesse (ROI) para medir a densidade de pixels de cada dente; e uma subjetiva, para comparar as imagens dos grupos. Para a análise estatística, o teste t de Student, estatística descritiva e a análise de distribuição de frequência foram usadas tanto para a análise objetiva quanto para a subjetiva. Resultados: a concordância entre os observadores se deu entre moderado e excelente. Foram obtidos valores de escalas de cinza semelhantes no grupo GP e no grupo GPB. Tais resultados foram reforçados pelos valores-p obtidos pelo teste t de Student. Para a análise subjetiva, os observadores indicaram o grupo GPB como o que desenvolveu o maior número de artefatos. Conclusões: ambos os materiais produziram artefatos nas imagens TCFC. Entretanto, na análise subjetiva, o grupo GPB mostrou níveis maiores de produção de artefatos do que o grupo GP, o qual poderia resultar em um diagnóstico incorreto de fratura da raiz e em um prognóstico pior para aquele dente.

DESCRITORES | Tomografia; Raio-X Computadorizado; Guta-Percha; Obturação do Canal Radicular; Artefatos.

CORRESPONDING AUTHOR | • **Marcelo Gusmão Paraiso Cavalcanti** PhD, Professor, Department of Stomatology, School of Dentistry, University of São Paulo • **Av. Professor Lineu Prestes, 2227** São Paulo, SP, Brazil • **05508-000** E-mail: mgpcaval@usp.br

• Received Mar 13, 2019 • Accepted Mar 18, 2019
• DOI <http://dx.doi.org/10.11606/issn.2357-8041.cldr.2019.155624>

INTRODUCTION

The success and longevity of endodontic treatment concerns many factors, including the quality of endodontic treatment, the remaining tooth structure, the portion of coronal restoration¹ and the choice of the material used to fill the root canal. Bioceramic materials were developed to improve some aspects of the endodontic filling material such as biocompatibility, radiopacity and good working properties. Furthermore, they maintain good dimensional stability, resulting in a reduced interface between the bioceramic endodontic filling materials and radicular dentin.²⁻⁴

Metallic objects, such as intracanal posts and restorations, may produce severe interference, thus decreasing the cone-beam computed tomography's (CBCT) imaging quality.⁵ The interference on the imaging quality is caused by the production of artifacts. Artifact is defined as any distortion in the image that is not related to the subject studied.⁶ In CBCT, artifacts may be caused by the effect of the x-ray beam on high-density objects. This interference is named beam hardening, and may occur in two forms: cupping artifacts and white streaks associated with dark bands that may appear near dense objects. Dark bands can mimic root fractures in CBCT images,⁷ thus reducing the accuracy of this modality for detection of root fractures.⁸

Many studies have been conducted to investigate the influence of artifacts produced by metallic objects.⁷⁻⁹ In a recent study⁸, the authors described that some white streaks and dark bands also appear in the images of endodontically-treated teeth that had not received metallic posts.

Conventional gutta-percha (GP) is a dense material that may produce artifacts in CBCT images.⁸ However, we did not find studies reporting artifact production in CBCT images caused by GP or bioceramic gutta-percha (BCGP) in the literature. GP is widely employed as an endodontic filling material while BCGP is a more recent material described

as biocompatible, nontoxic, non-shrinking and chemically stable in the biological environment, thus being a good choice for use in a clinical setting.¹⁰⁻¹¹ According to Brasseler (manufacturers of Endosequence BC Sealer, Brasseler USA, Savannah, Georgia, USA), BC Sealer is a bioceramic endodontic filling composed by zirconium oxide, calcium silicates, calcium phosphate monobasic and calcium hydroxide. As a result, it has fundamental clinical attributes, such as alkaline pH, antibacterial activity, adequate radiopacity and biocompatibility.

Since GP is the main material for endodontic filling, the purpose of this study was to assess the influence of artifacts caused by conventional and bioceramic gutta-percha points on CBCT images.

METHODS

Preparation of the samples

The Ethics Committee of our institution approved the present study under protocol No. 1.121.863.

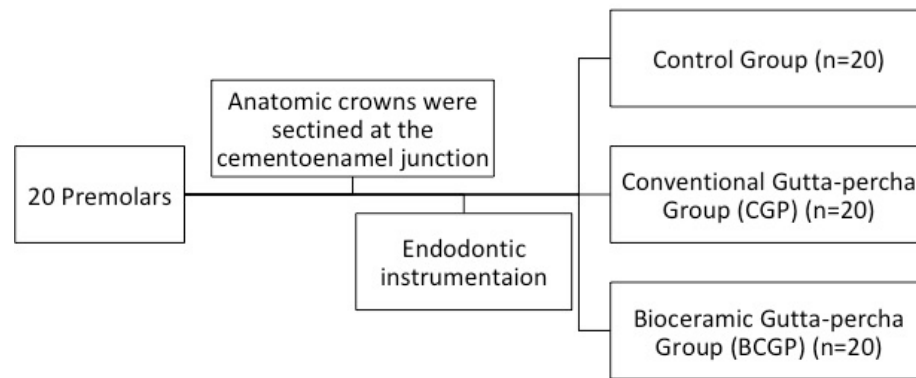
Extracted single-rooted human premolar teeth ($n = 20$) were selected for the study. The teeth were scanned using CBCT to exclude samples with root resorption, larger restorations (beyond the cemento-enamel junction), cracks, fractures, more than one root canal or dilacerations. One operator prepared all teeth for the study and executed the CBCT imaging exams. The anatomic crowns of all the selected teeth were sectioned perpendicularly to the long axis of the teeth, at the cemento-enamel junction, using a carborundum disc propelled by an air turbine (KaVo Dental, Biberach, Baden-Württemberg, Germany).

A #10 K-file (Dentsply Maillefer, Ballaigues, Jura-Nord Vaudois, Switzerland) was introduced into the canal until it was visible at the apical foramen, to determine the working length. The same operator performed endodontic instrumentation by using Easy ProDesign (Easy equipment, Belo Horizonte, MG, Brazil) rotary instruments up to size #.25/06

and #.25/08. During preparation, each canal was irrigated with 5.25% NaOCl after each instrument had been used. The teeth were kept immersed in water during the entire process.

The same 20 teeth were used three times to create three different groups (Figure 1):

A single gutta-percha point was inserted in each root canal.



Control group: Instrumented root without gutta-percha point; Conventional gutta-percha group (GP): a single conventional gutta-percha point (Dentsply-Maillefer, Ballaigues, Jura-Nord Vaudois, Switzerland) in the root; Bioceramic Gutta-percha group (BCGP): a single bioceramic gutta-percha point (BC Sealer, Brasseler USA, Savannah, Georgia, USA) in the root.

Figure 1 | Methodology flow chart.

Image acquisition

A cavity was produced in the posterior region of a mandible model made from dental stone (Durone, Dentsply, York, Pennsylvania, EUA), in which each tooth was inserted for the CBCT scan.¹²

CBCT (ProMax 3D Max, Planmeca, Helsinki, Uusimaa, Finland) scans were performed for each tooth individually placed in the mandible stone model. The field of view (FOV) consisted of a 10 x 5 cm (height x diameter) cylinder with 0.15 mm voxel, 80 kVp and 8 mA – HD Protocol. This protocol increases the time of acquisition (15 seconds) and consequently, produces a higher number of images than the other protocols. Each tooth was scanned three times; each scan corresponded to one of the previously described groups.

Image assessment

All CBCT images were exported as Digital Imaging and Communications in Medicine (DICOM) files and imported to a workstation (iMac 27", Apple, Cupertino, CA, USA.). A DICOM viewer software (OsiriX MD 1.2 64-bit, Pixmeo, Geneva, Switzerland) was employed

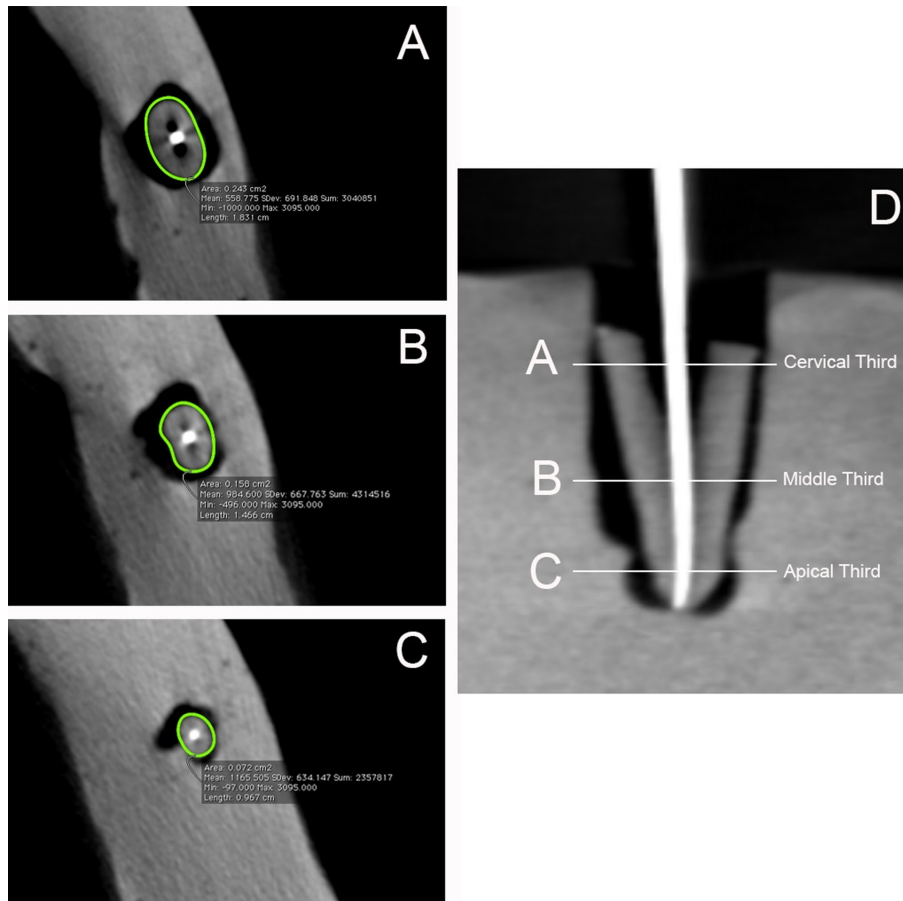
to assess the images. All observers, who had not had previous contact with the teeth, were calibrated by using 10 randomized images from the test group.

Grayscale variables – objective analysis

Two observers, who had over a year of experience with the analysis of CBCT images, performed the first analysis by using the Region of Interest (ROI). This tool allowed them to obtain the grayscale values by measuring pixel density in each tooth segment, which were categorized as (Figure 2):

A perimetrical line was manually drawn around the root, in the axial view of each root third (demonstrated by the green line – Figure 2). The inner region of this perimetrical line determined the area in which the grayscale values were obtained using the ROI tool.

The ROI tool provided the minimum, maximum, mean pixel values, as well as the standard deviation and the area and perimeter of the selected area (region of interest) (Figure 2). The minimum and maximum pixel values were used to evaluate the grayscale in each third of the root.



Cervical Third (CT): 2 mm from the cementoenamel junction; Middle Third (MT): median point of the root's length; and Apical Third (AT): 2 mm up to the apical foramen.

Figure 2 | Illustration of the three segments used for the grayscale measurements, indicating the values provided by the ROI tool. CBCT axial imaging: (A) cervical third, (B) middle third, and (C) apical third. (D) The CBCT coronal imaging shows the root's division in thirds.

Comparison between the groups' images – subjective analysis

Two maxillofacial radiologists and one endodontist executed a subjective analysis. The DICOM image in which the measurements were performed was exported in the TIFF format to create the material for these comparisons.

The randomization process was performed in two steps: the first (www.random.org – Trinity College, Dublin, Ireland) determined the teeth sequence and the second (Randomization Main software) randomized the test groups (conventional or bioceramic gutta-percha image) within each one of the pre-randomized teeth sequences assembled

in a PowerPoint presentation, with 60 slides in total. The presentation contained three images of the same tooth in different situations, to compare the test groups with the control group.

The observers were granted access to the PowerPoint presentation and had to answer which test image (A or B, corresponding to the position taken by either the CGP or the BCGP group in each slide) represented a higher artifact level (presence of artifacts, dark bands and white streaks)⁶ when compared to the control group. When the observer concluded that the two images had produced similar levels of artifact in both test groups, the answer was “zero”. The same images were analyzed again after a 2-week interval.

Statistical analysis

The reliability of this study was assessed based on two methods: 1) for the grayscale measurements: agreement between observers by using the interclass correlation coefficient (ICC), with a 95% confidence interval; 2) for comparison between the groups' images: Kappa coefficients were calculated to determine the inter- and intra-observer agreements for the subjective analysis.^{13,14}

The values obtained in each ROI, for the control group, the GP group and the BCGP group, were submitted to descriptive statistics. Linear functional normalization of data was conducted to analyze the groups. The minimum values were associated with darker images, while the maximum values were associated with brighter images. The control group's linear function value was determined as 1 (equivalent to 100%). Therefore, the grayscale variation rate between the control and each test group was determined based on numeric variation. The variations found in each root third were compared using the Mann-Whitney test.

Reliability statistics, Kappa tests, descriptive statistics and Student's t-test were performed in the BioEstat software (Instituto Mamiraua, Belém, PA, Brazil).

For the comparison between the test groups, the observers' individual responses were collated and submitted to frequency distribution analysis according to the three outcomes in our sample (image A or image B represented a higher presence of artifacts in relation to the control group, or images A and B represented an equal presence of artifacts). The data for each outcome and for each root third were presented in percentages; they were estimated in Microsoft Excel (Microsoft Corporation, Redmond, WA, USA).

RESULTS

Intra- and Inter-observer agreement

The ICC rate for the inter-observer agreement in each test group ranged from 0.944 to 0.989 (p-values < 0.0001), indicating excellent to almost perfect agreement.

The Kappa test for the intra-observer agreement ranged from 0.61 to 0.77, suggesting good agreement between the first and second observations in the subjective analysis. For the inter-observer agreement, it ranged from 0.37 to 0.49, suggesting fair to moderate agreement between the observers in the subjective analysis.

Grayscale values

Table 1 depicts the mean values for each test group, for the grayscale tones represented by the minimum and maximum pixel values. In the CT, both materials demonstrated similar minimum pixel values compared to the other regions. An identical pattern was noted for the maximum values, i.e., both materials produced the same level of white streaks. The comparison between the patterns of the GP and BCGP groups was corroborated by the p-values obtained in the Mann-Whitney test, which determined that there was no statistically significant difference between them.

Table 1 | Rate of variation between the control group and each test group, for the minimum (Min) and maximum (Max) values.

		Min	Max	p value*
CT	CGP	-993.50	3095	ns
	BCGP	-999.80	3095	
MT	CGP	-695.80	3095	ns
	BCGP	-736.30	3095	
AT	CGP	-503.20	3078	ns
	BCGP	-529.20	3095	

CT: Cervical third MT: Middle third AT: Apical third
 CGP: Conventional gutta-percha group
 BCGP: Bioceramic Gutta-percha group
 Min: Minimum pixel value
 Max: Maximum pixel value
 * Mann-Whitney Test

Subjective comparison between groups

For this analysis, the observers determined that the BCGP group's images reproduced a higher percentage of artifact presence (Table 2). In Figure 3, it is possible to visualize the different behavior of both materials in each root third.

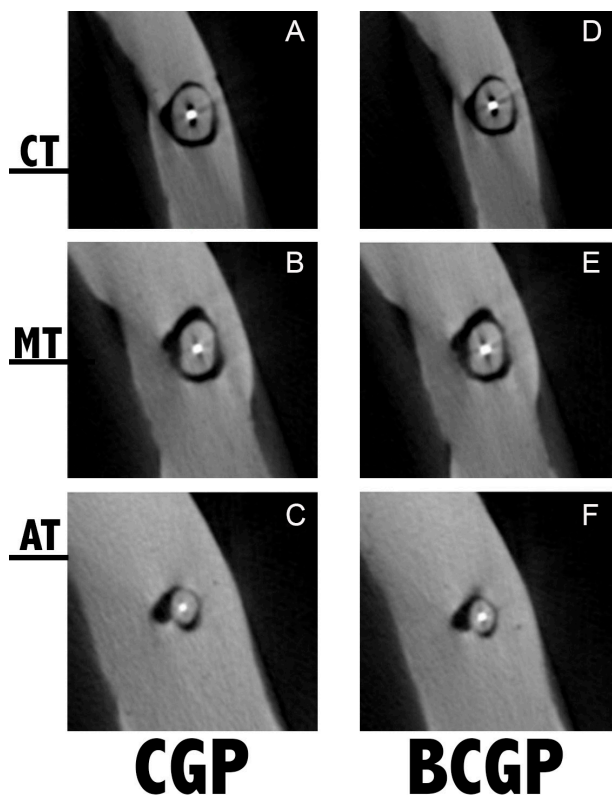


Figure 3 | CBCT axial imaging. Comparison between the Conventional gutta percha group (A, B, and C), and the Bioceramic gutta percha group (D, E, and F), for the cervical third (CT), middle third (MT), and apical third (AT).

Table 2 shows the subjective analysis for each root third. The “zero” column represents the images in which the observers established that BCGP and CGP produced similar degrees of artifact interference. In the BCGP group, the MT was selected more often by the observers. Thus, the BCGP group’s MT images contained more artifacts, followed by the AT and the CT.

Table 2 | Frequency (in percentage) for the comparison between groups of each observer’s answers in relation to the image with greater presence of artifact interference.

		CGP	BCGP	Zero
Third	CT	18%	67%	15%
	MT	5%	78%	17%
	AT	9%	72%	19%
Observer	Obs. 1	17%	71%	12%
	Obs. 2	10%	68%	22%
	Obs. 3	6%	74%	20%
	Mean	11%	71%	18%

CGP: Conventional gutta-percha group; BCGP: Bioceramic Gutta-percha group

DISCUSSION

Root fracture represents one of the worst prognosis in dentistry.¹⁵⁻¹⁶ Thus, new materials have been developed to increase the root’s resistance in teeth with endodontic treatment.⁴ Bioceramic materials showed good results regarding the resistance of endodontically-treated teeth in the literature.⁴⁻¹⁷ The root-filling materials’ composition may result in artifact production in tomographic images, and thus decrease the accuracy of root fracture diagnoses.^{5-18,9} The influence of these materials on CBCT images has been extensively studied.^{12,14,20-23} However, given the scarcity of studies concerning the quantification of artifacts and the need for the study of new materials, we measured the images’ density (objective assessments) and compared the images of the two test groups (subjective assessments).

One of the CBCT artifacts present in the images is the streak artifact, which is closely related to the direction of radiation exposure.¹³ Materials with higher mineral content will provide images with more artifacts due to the physical processes involved. In this regard, since BCGP is described as an endodontic filling with higher radiographic attenuation (zirconium oxide, calcium silicates, calcium phosphate monobasic and calcium hydroxide), more artifacts are expected, despite similar results in grayscale values. Another factor inherent to artifact production is the thickness of each tooth, even with uniform canal instrumentation, which could lead to different attenuation values. The artifact distribution pattern in tomographic images is multifactorial. The observer should consider that the interaction between different effects such as beam hardening and scatter could lead to different aspects of artifact distribution in CBCT images.

Brito-Júnior et al.¹⁴ evaluated the presence of artifacts by counting the number of white streaks. However, we believe that it is difficult to analyze artifacts in this way, because it is not always possible

to figure out the direction of the artifacts' streaks between different materials. Moreover, given the non-uniformity of each tooth, the artifacts will always be irregular in nature. These authors scanned 25 teeth positioned side-by-side. Based on our experience, the artifact caused by one tooth might spread the white streaks or dark bands to the neighboring tooth, thus impairing the analyses. In our study, the specimens were scanned individually to avoid interference of any materials close to them. In addition, the objective assessments of the images in our study were performed by analyzing the maximum and minimum grayscale values for each situation, to estimate the grayscale variation in the GP and BCGP groups. Additionally, the grayscale analyses were performed individually so that the quantitative information on the artifacts would originate from a specific material of a single root. According to Smeets et al (2017),²⁴ in CBCT, the grayscale value's distributions could differ from the reference values, leading to different images in relation to the materials used.

When interpreting the values provided by the ROI tool, the maximum values were similar for both materials, that is, both materials reached the same high hyperdensity level. While analyzing each root third independently, the CT region showed the highest variation of maximum values, thus corroborating the greater presence of artifacts in this region. The observers perceived a higher number of white streaks in the CT. The artifact was produced by the effects of scatter due to the presence of metallic restorations or endodontic fillings in the image, producing linear high density (bright lines).²⁵ The minimum values showed similar numbers in the three thirds, but the BCGP group always provided higher minimum values, especially in the MT, where the images obtained were perceived to have a higher number of darkened bands.

Imaging artifacts are produced by the effects of beam hardening due to the presence of metallic

restorations or endodontic fillings on the images, resulting in linear low-density (void) streak artifacts²⁶. When comparing the two test groups, both materials produced similar levels of brighter streaks. The BCGP group produced a higher rate of variation of greyscale values for the dark bands than the GP group. However, the difference between both materials was not statistically significant (Table 1). The subjective analysis' results supported the former finding: between BCGP and GP, the first group was more frequently selected (higher percentage values) as the one that resulted in images with more artifacts.

The endodontically-treated teeth were claimed to be weakened²⁵ by both the loss of tooth structure²⁶ and induced stresses caused after the endodontic treatment, mainly after restorative procedures^{2,26} such as the insertion of an intracanal post. In endodontically-treated teeth, MT and CT are the areas that suffer the greatest loss of structure and consequently, have the highest incidence of root fracture.²⁷ In these areas, image assessment is critical, especially when the patient describes symptoms of root fracture.

Andreasen et al.¹⁷ reported that 55% of root fractures occur on the middle third and that the knowledge of the correct type, location and extension of the fracture, as well as of the hard tissue affected by it, are important to estimate the survival rate of that tooth. Unfortunately, this root third was the area with greatest grayscale variation in our study. Consequently, MT and CT were the regions that might clinically result in a higher number of misdiagnoses, which might be associated with a higher number of dark bands (Table 1 and 2) overlapping the original image of the study object. It is essential to emphasize that our results showed that BCGP suffered a higher level of variation, especially in the MT. The composition of the bioceramic material may have contributed to these results.

The subjective assessments of the images were performed by three observers with different areas of expertise (two oral and maxillofacial radiologists-MFR and one endodontist), but all of them had extensive experience with CBCT images. The answers of all three observers was proportional, with higher sensitivity for the BCGP group. We understand that the subjective assessment was fundamental for our study, since professional experience might influence the observers' opinions. In real-life situations, MFRs and endodontists would analyze the CBCT exam and associate the images with the clinical findings. Particularly the endodontist (observer 3) selected BCGP as the image causing more artifacts in 74% of the slides, thus corroborating our findings shown in Table 1. We believe that the endodontist is more experienced in observing and differentiating the different endodontic filling materials and thus, more sensitive to these materials in the CBCT images.

The higher ICC and Kappa values supported the reproducibility of the methodology and grayscale analysis selected for this study.

An additional analysis was conducted to independently evaluate each root third (Table 2) according to the subjective assessments' results. The CT image was determined to be the one where the GP group generated more artifacts; the BCGP group generated more artifacts in the MT; and the AT values resulted in no difference between the groups. Again, in both test groups, there was a higher number of artifacts in the MT and in the CT.

Many studies have evaluated conventional endodontic fillings with other dental materials and different types of CBCT equipment and protocols.^{21,23,28,29} The results of all these studies were similar, with endodontic fillings producing fewer artifacts than metallic materials. Our study compiles these results by comparing a conventional endodontic filling with a new endodontic filling

with metallic particles. We believe that our observers identified higher variation values in the BCGP group (Table 2) due to the presence of zirconium particles in its composition.³ Topçuoğlu et al.⁴ concluded that the combination of BCGP with bioceramic cement contributed to the greater resistance to root fracture of endodontically-treated teeth.⁴ In Table 1, our values showed a higher rate of artifacts in the BCGP group, despite the fact that the numbers were not statistically significant. Even though the system of bioceramic endodontic fillings is known for assigning good mechanical resistance to endodontically-treated teeth,⁴ at the same time, it might produce a greater number of false-positive CBCT diagnoses of root fracture in a clinical setting, mainly as a consequence of the high percentage of inorganic components.

There are many previous studies on the form and effects of CBCT artifacts, but there was no analysis of the form of GP and BCGP artifacts and their influence on the diagnosis. In this study, we intended to perform this analysis by objective and subjective means, as stated in the method and discussion segments. According to our results, the BCPG group was indicated as the one that produced more artifacts in the root's middle third region, and the cervical third was the region that produced more artifacts for the PG group.

CONCLUSIONS

Both materials produced similar levels of artifacts in the CBCT images. The BCGP group showed higher levels of artifact production than the GP group, although no statistical differences were found between them.

In the subjective assessments, the BCGP group showed higher artifact production levels than the GP group, which could result in more cases of false-positive diagnosis of root fracture and consequently, in a worse prognosis for that tooth. The BCPG group was indicated as the one that produced more

artifacts in the root's middle third region, and the cervical third was the region that produced more artifacts for the PG group.

REFERENCES

- Williams JV, Williams LR. Is coronal restoration more important than root filling for ultimate endodontic success? *Dent Update*. 2010 Apr;37(3):187-93.
- Schwartz RS, Robbins JW. Post placement and restoration of endodontically treated teeth: a literature review. *J Endod*. 2004;30(5):289-301.
- Pawar S, Pujar M, Makandar S. Evaluation of the apical sealing ability of bioceramic sealer, AH plus & epiphany: An in vitro study. *J Conserv Dent*. 2014;17(6):579.
- Topçuoğlu HS, Tuncay Ö, Karataş E, Arslan H, Yeter K. In vitro fracture resistance of roots obturated with epoxy resin-based, mineral trioxide aggregate-based, and bioceramic root canal sealers. *J Endod*. 2013;39(12):1630-3.
- Costa FF, Pinheiro LR, Umetsubo OS, Santos Júnior O, Gaia BF, Cavalcanti MGP. Influence of cone-beam computed tomographic scan mode for detection of horizontal root fracture. *J Endod*. 2014 Sep;40(9):1472-6.
- Scarfe WC, Farman AG. What is cone-beam CT and how does it work? *Dent Clin North Am*. 2008 Oct;52(4):707-30.
- Scarfe WC, Farman AG, Sukovic P. Clinical applications of cone-beam computed tomography in dental practice. *J Can Dent Assoc*. 2006 Feb;72(1):75-80.
- Salineiro FCS, Pinheiro LR, Santos Junior O, Cavalcanti MGP. Detection of horizontal root fracture using four different protocols of cone-beam computed tomography. *Braz Oral Res*. 2015;29(1):1-6.
- Chang E, Lam E, Shah P, Azarpazhooh A. Cone-beam computed tomography for detecting vertical root fractures in endodontically treated teeth: a systematic review. *J Endod*. Elsevier Ltd; 2016 Feb;42(2):177-85.
- Candeiro GT de M, Correia FC, Duarte MAH, Ribeiro-Siqueira DC, Gavini G. Evaluation of radiopacity, pH, release of calcium ions, and flow of a bioceramic root canal sealer. *J Endod*. 2012 Jun;38(6):842-5.
- Hess D, Solomon E, Spears R, He J. Retreatability of a bioceramic root canal sealing material. *J Endod*. Elsevier Ltd; 2011;37(11):1547-9.
- de Rezende Barbosa GL, Sousa Melo SL, Alencar PNB, Nascimento MCC, Almeida SM. Performance of an artefact reduction algorithm in the diagnosis of in vitro vertical root fracture in four different root filling conditions on CBCT images. *Int Endod J*. 2016 May;49(5):500-8.
- Pinheiro LR, Scarfe WC, Augusto de Oliveira Sales M, Gaia BF, Cortes ARG, Cavalcanti MG. Effect of cone-beam computed tomography field of view and acquisition frame on the detection of chemically simulated peri-implant bone loss in vitro. *J Periodontol* [Internet]. 2015;86(10):1159-65. Available from: <http://www.joponline.org/doi/10.1902/jop.2015.150223>.
- Brito-Júnior M, Santos LA, Faria-e-Silva AL, Pereira RD, Sousa-Neto MD. Ex vivo evaluation of artifacts mimicking fracture lines on cone-beam computed tomography produced by different root canal sealers. *Int Endod J*. 2014 Jan;47(1):26-31.
- Benic GI, Sancho-Puchades M, Jung RE, Deyhle H, Hämmerle CHF. In vitro assessment of artifacts induced by titanium dental implants in cone beam computed tomography. *Clin Oral Implants Res*. 2013 Apr;24(4):378-83.
- Costa FF, Gaia BF, Umetsubo OS, Pinheiro LR, Tortamano IP, Cavalcanti MGP. Use of large-volume cone-beam computed tomography in identification and localization of horizontal root fracture in the presence and absence of intracanal metallic post. *J Endod*. 2012 Jun;38(6):856-9.
- Andreasen JO, Ahrensburg SS, Tsilingaridis G. Root fractures: the influence of type of healing and location of fracture on tooth survival rates: an analysis of 492 cases. *Dent Traumatol*. 2012;28(5):404-9.
- Celikten B, Uzuntas CF, Gulsahi K. Resistance to fracture of dental roots obturated with different materials. *Biomed Res Int*. 2015;1-5.
- Yiğit Özer S. Detection of vertical root fractures of different thicknesses in endodontically enlarged teeth by cone beam computed tomography versus digital radiography. *J Endod*. 2010 Jul;36(7):1245-9.
- Junqueira RB, Verner FS, Campos CN, Devito KL, do Carmo AMR. Detection of vertical root fractures in the presence of intracanal metallic post: a comparison between periapical radiography and cone-beam computed tomography. *J Endod*. 2013 Dec;39(12):1620-4.
- Helvacioğlu-Yiğit D, Demirtürk Kocasarac H, Bechara B, Noujeim M. Evaluation and reduction of artifacts generated by 4 different root-end filling materials by using multiple cone-beam computed tomography imaging settings. *J Endod*. 2016;42(2):307-14.
- Demirtürk Kocasarac H, Helvacioğlu Yiğit D, Bechara B, Sivanoglu A, Noujeim M. Contrast-to-noise ratio with different

- [Artifact induction by endodontic materials: a CBCT analysis](#)

- settings in a CBCT machine in presence of different root-end filling materials: an in vitro study. *Dentomaxillofacial Radiol.* 2016 May;45(5):20160012.
23. Queiroz PM, Oliveira ML, Groppo FC, Haiter-Neto F, Freitas DQ. Evaluation of metal artefact reduction in cone-beam computed tomography images of different dental materials. *Clin Oral Investig.* 2018 Jan;22(1):419-23.
24. Smeets R, Schollen M, Gauer T, Aarabi G, Assaf AT, Rendenbach C, Beck-Broichsitter B, Semmusch J, Siemonsen S. Artefacts in multimodal imaging of titanium, zirconium and binary titanium-zirconium alloy dental implants: an in vitro study. *Dentomaxillofac Radiol.* 2017 Feb;46(2):20160267.
25. Tang W, Wu Y, Smales RJ. Identifying and reducing risks for potential fractures in endodontically treated teeth. *J Endod.* 2010;36(4):609-17.
26. Neves FS, Freitas DQ, Campos PSF, Ekestubbe A, Lofthag-Hansen S. Evaluation of cone-beam computed tomography in the diagnosis of vertical root fractures: the influence of imaging modes and root canal materials. *J Endod.* 2014 Oct;40(10):1530-6.
27. Ferreira RI, Bahrami G, Isidor F, Wenzel A, Haiter-Neto F, Groppo FC. Detection of vertical root fractures by cone-beam computerized tomography in endodontically treated teeth with fiber-resin and titanium posts: an in vitro study. *Oral Surg Oral Med Oral Pathol Oral Radiol.* 2013 Jan;115(1):e49-57.