

Three-dimensional evaluation of mucoepidermoid carcinoma on the hard palate: a clinical case report

• **Antonione Santos Bezerra Pinto** Department of Morphology, Faculty of Medicine, Universidade Federal do Ceará, Fortaleza, CE, Brazil • **Sérgio Lúcio Pereira de Castro Lopes** Department of Dentistry, Universidade Estadual Paulista “Júlio de Mesquita Filho”, São José dos Campos, SP, Brazil • **Jean de Pinho Mendes** Department of Dentistry, Universidade Estadual do Piauí, Parnaíba, PI, Brazil • **Brenda Castro Rodrigues Ferraz** Dentistry Course, Universidade Estadual do Piauí, Parnaíba, PI, Brazil • **Matheus Santos Carvalho** Dentistry Course, Universidade Estadual do Piauí, Parnaíba, PI, Brazil • **Ingrid Safira de Freitas Silva** Dentistry Course, Universidade Estadual do Piauí, Parnaíba, PI, Brazil • **Alan Leandro Carvalho de Farias** Department of Biotechnology, Universidade Federal do Piauí, Parnaíba, PI, Brazil • **André Luiz Ferreira Costa** Postgraduate Program in Dentistry, Universidade Cruzeiro do Sul, São Paulo, SP, Brazil

ABSTRACT | Mucoepidermoid carcinoma is of unknown aetiopathology, but it may be related to genetic factors, exposure to ionizing radiation and smoking habits as well. Mucoepidermoid carcinoma is considered the most common malignant neoplasm of salivary glands found in the oral cavity, with its clinical characteristics (e.g., size and shape) favoring the diagnosis and treatment planning. This report describes a case of mucoepidermoid carcinoma which infiltrates into the maxillary sinus and nasal fossa through the palate and highlights the importance of obtaining three-dimensional (3D) images of the tumor for volumetric analysis, thus improving the chances of a successful surgery. We have described the use of the segmentation technique in which the tumor's volume was calculated to help in predicting surgical outcomes. A 50-year-old patient sought dental treatment because of a purplish swelling in the hard palate region on the left side. Computed tomography examination was performed for visualization of the lesion and incisional biopsy for obtaining a sample, which was sent to anatomopathological study. Histological characteristics of the lesion and presence of neoplastic cells showed positive immunohistochemical reactions for cytokeratin 7 antibody, leading to a diagnosis of mucoepidermoid carcinoma. In view of the malignant characteristics of the lesion, the patient was referred to a head and neck surgeon for treatment.

DESCRIPTORS | Diagnosis; Mucoepidermoid Carcinoma; Salivary Glands; Oral Medicine.

RESUMO | **Avaliação tridimensional de carcinoma mucoepidermoide em palato duro: relato de caso clínico** • O carcinoma mucoepidermoide possui etiopatogenia desconhecida, porém, pode ser relacionado a fatores genéticos, exposição à radiação ionizante e também ao hábito de fumar. Há a possibilidade de crescer de forma assintomática. É considerado a neoplasia maligna de glândulas salivares mais comum encontrada na cavidade oral e as suas características clínicas (por exemplo, sítio de predileção e forma como se apresenta) favorecem um melhor diagnóstico e planejamento de intervenção. Este relato apresenta um caso de carcinoma mucoepidermoide que se infiltra no seio maxilar e fossa nasal através do palato e destaca a importância da obtenção de imagens tridimensionais (3-D) do tumor para análise volumétrica e melhoria das chances de sucesso cirúrgico. Descrevemos o uso de uma técnica pictórica em que o volume do tumor foi calculado para ajudar a prever os resultados cirúrgicos. A paciente de 50 anos procurou atendimento odontológico devido ao aumento de volume com coloração arroxeada em região de palato duro do lado esquerdo, foi realizado o exame de Tomografia Computadorizada onde se verificou a lesão. A partir da biópsia incisional e o encaminhamento para avaliação anatomopatológica, suas características histológicas e as células neoplásicas mostraram-se positivas para as reações de imunohistoquímica contra anticorpo citoqueratina sete, o que concluiu o diagnóstico de carcinoma mucoepidermoide. Diante das características malignas da lesão, a paciente foi encaminhada para médico cirurgião de cabeça e pescoço para tratamento.

DESCRITORES | Diagnóstico; Carcinoma Mucoepidermoide; Glândulas Salivares. Medicina Bucal.

CORRESPONDING AUTHOR | • **Ingrid Safira de Freitas Silva** Dentistry Course at Universidade Estadual do Piauí, Parnaíba, PI, Brazil • **Rua Tangara, n. 3, apt. 203** São José de Ribamar, Maranhão, Brazil • **65110-000** E-mail: ingrid.fs@outlook.com

• Received Mar 7, 2019 • Accepted Mar 28, 2019
• DOI <http://dx.doi.org/10.11606/issn.2357-8041.clrd.2019.155434>

INTRODUCTION

Tumors of minor salivary glands are comparatively rare and account for about 10% of all salivary tumors.^{1,2} The most common malignant tumour of salivary glands and can affect both major and minor salivary glands, with the parotid gland being the most affected, followed by palatal minor glands is the mucoepidermoid carcinoma. Individuals aged between 6 and 90 years old, with a mean age of occurrence ranging from 51 to 56 years old can be affected by this type of lesion.^{2,3} Approximately three-quarter of the cases involve low-grade tumors, showing rarely metastasize. Therefore, the treatment is aimed at controlling the lesion locally by means of a wide surgical incision in order to let the margins free of tumor.^{2,4}

The majority of the mucoepidermoid carcinomas, anatomically, occur at the junction between the hard/soft palate and deep surface of the tumor, usually supported by the hard palate bone.⁵ The ultimate management of the inner bone margin of such tumors has not been conclusively established yet, but the treatment by partial maxillectomy or palatal fenestration are indicated for large and bulky tumors or those with radiological and tomographic evidence of bone erosion or invasion.²⁻⁶

The use of three-dimensional principles has facilitated the observation and comparison of several treatment plannings.⁷ The performance of a volumetric evaluation of the overall morphological changes in noble structures, thus enabling a better understanding of the tumor's morphology and its proximity to adjacent tissues is allowed by three-dimensional reconstruction.⁸ Besides, the 3D reconstruction techniques allow the surgical team to determine more characteristics regarding localization and extension of the tumour.^{3,8-10}

Given this, the objective of this work is to report a clinical case of mucoepidermoid carcinoma on the hard palate in which 3D re-constructions from cone

beam computed tomographic (CBCT) images were used. This allowed for segmentation and volumetric analysis of the lesion in order to determine the relationship between tumor and noble anatomical structures and provide favorable information to choose the best surgical technique for treating this pathology.

MATERIAL AND METHODS

A 50-year-old female patient sought dental treatment because of a purplish swelling in the hard palate region and posterior alveolar ridge on the left side (Figure 1). Panoramic radiography was performed, revealing irregular alveolar bone loss in the region of teeth #27 and #28 (Figure 2), which suggested neoplasm. Cone beam computed tomographic examination (GXCB-500™, powered by i-CAT®) was indicated and performed with FOV of 16 x 6.0 cm and a voxel size of 0.25 mm, producing images showing a well-defined mass of density corresponding to soft tissue, on the left palatal region. Intravenous contrast examination showed a nodular solid lesion with lobulated contour and partially defined, located in the pharyngeal-mucosal space in the palatal region on the left side (Figure 3). The volumetric measurements of the lesion performed indicated 5480.995 mm³. In the CBCT sections, the lesion dimensions in the super-inferior direction of 20.60 cm, in the lateromedial direction of 17.20 cm and 13.90 cm in the anteroposterior direction, are observed. Next, an incisional biopsy was performed and the sample sent for anatomopathological study. Histological sections revealed the presence of cystic fragment partially covered by non-keratinised stratified epithelium, showing a lining consisted of sometimes pavementous and sometimes cubic cells. The lining cells were sometimes organized as ductiform structures, whereas mucosal cells could be readily identified. It was possible to observe

nests of epithelial cells in the capsule, including epidermoid cells, sometimes showing cystic degeneration. Solid nests could also be observed. Areas exhibiting discrete lymphoplasmocitary inflammatory infiltrate and focal area presenting multinucleated giant cells and fragments of reactive bone complete the histological picture. Neoplastic cells were shown to be positive to immunohistochemical reactions for cytokeratin 7 antibody (Figure 4).

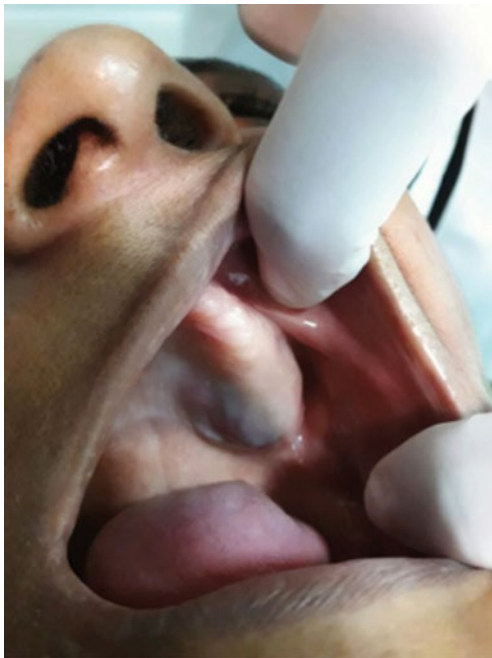


Figure 1 | Initial clinical appearance of the patient, showing increased volume, in purple color, in the posterior left region of the palate.

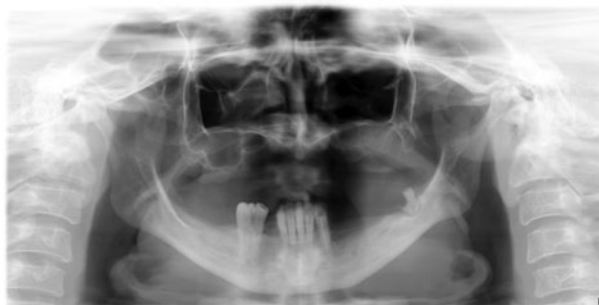

Figure 2 | Panoramic radiograph demonstrating radiolucent line in the alveolar bony border on the left side, affecting the ipsilateral maxillary sinus floor and the left nasal fossa floor area of irregular and ill-defined appearance.

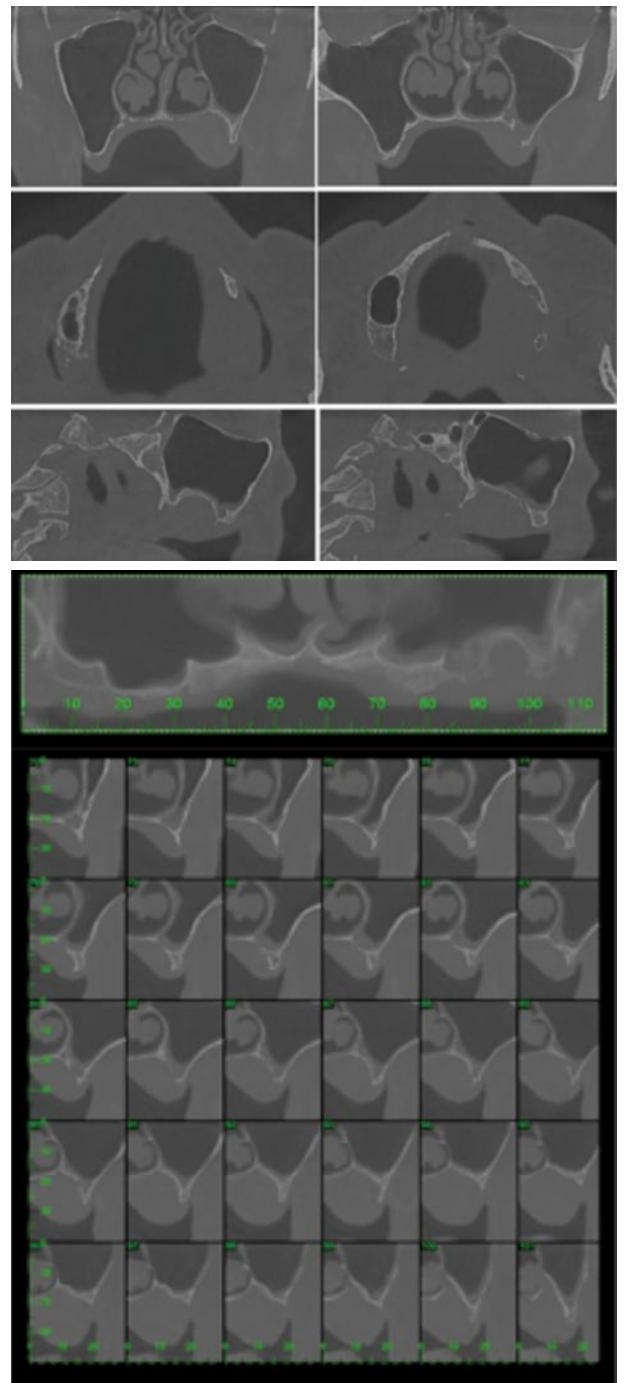


Figure 3 | Multiplanar reformatted sections of CBCT show an extensive mass of soft-tissue density, continuing the hard palate region of the left side, causing a hypodense line of the maxillary sinus floor and the ipsilateral nasal fossa side wall, with irregular aspects of the bone adjacent to the lesion. Panoramic view and cross sections show the invasive aspect of the lesion with involvement and expansion of the cortical bone of the alveolar ridge, the floor of the maxillary sinus and left nasal fossa.

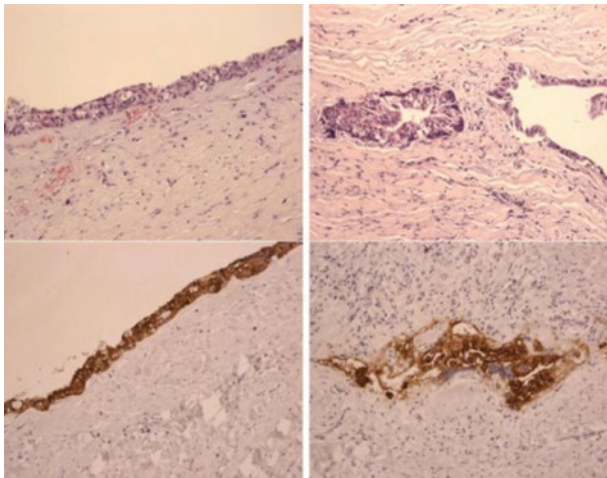


Figure 4 | Histopathological features with hematoxylin and eosin and examination showing positive immunohistochemical reactions for cytokeratin 7 antibody.

Among the imaging characteristics that indicate a malignant behavior of the lesion, it is evident its infiltrative aspect, leading to the solution of continuity of the anatomical limits (floor of the maxillary sinus and nasal fossa), with irregular bone borders, moth-eaten aspect, as well as the absence of previous cortical bulging procedures, which would suggest a benign behavior. In view of the clinical, imaging and histological characteristics, the diagnosis was low-grade mucoepidermoid carcinoma.

After the final diagnosis, the case was selected for 3D study by using the InVesalius software. After 3D re-construction according to the soft-tissue protocol, it was possible to reduce the bone transparency and observe the morphology of the mass, which was isolated from the other structures to allow for evaluation of its size and position (Figure 5). In the 3D model, after measuring its volume (i.e. 5480.995 mm³), the upper margin of the tumor was found to be more prominent, suggesting a higher probability of tumor invasion into both maxillary sinus and nasal fossa floor. The area corresponding to the tumour on CBCT image was manually segmented and the addition of its volume allowed for a new perspective on the lesion's extension and

size in cubic millimeters as well as for analysis of the lesion's morphological aspects on a panoramic basis.

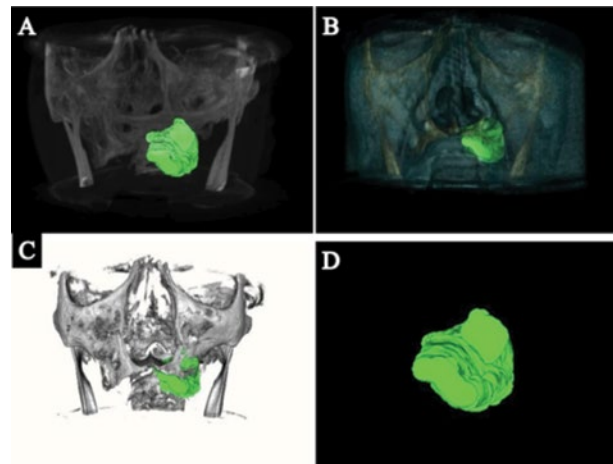


Figure 5 | (A) Isometric perspective view showing skeletal structures with reduced bone transparencies, which better shows the neoplasm. (B) Volumetric reconstruction of facial soft tissue highlighting the lesion. (C) Volumetric reconstruction of the lesion inside the bone structure following manual segmentation. (D) Panoramic view of the tumor following manual segmentation with volumetric measurement of 5480.995 mm².

The InVesalius software combines a specific CBCT slice with a 3D reconstructed slice of the tumor to produce a single image of it, thus individualizing the tumor for further surgical planning.

This emphasizes the importance of 3D reconstruction as this method can add a new perspective for analysis of the spatial position of the tumor and highlight the most prominent areas around the surrounding tissues. Consequently, the 3D imaging technique can be an auxiliary method to help determine which margins should be sectioned.⁹ Moreover, the InVesalius software can be also used for a conservative analysis as the patients do not need to undergo procedures placing their recuperation at risk, and thus one can decide on the best ways to proceed with the case, including surgery planning and further treatments. Because the lesion was malignant, the patient was referred to a head and neck surgeon for maxillary resection as three-dimensional, volumetric and segmental analyses indicated invasiveness characteristics. The

patient has been followed up since then with a good prognosis (Figure 6). Informed consent form signed by the patient.

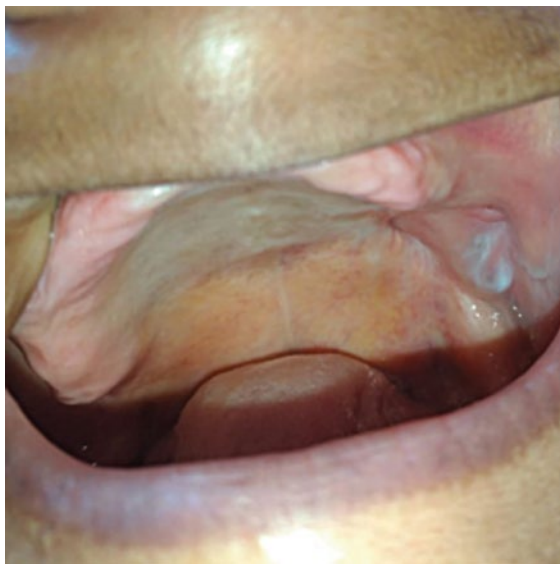

Figure 6 | Clinical appearance after ten months of surgery performed by a head and neck surgeon.

DISCUSSION

The mucoepidermoid carcinoma comprising approximately 23% of all tumors of the salivary gland, usually affects the palate (i.e. 35%), affects women (3: 2 ratio) and the average age is 55 years, characteristics which corroborate the clinical case presented here.

Prognostic factors regarding all sites and minor glands include the TNM staging system (where T = tumor, N = involvement of close lymph nodes, and M = metastasis), which is a classification tool used by the American Joint Committee on Cancer (AJCC) and Union for International Cancer Control (UICC) to identify types of cancer and histological degree. The majority of the intra-oral mucoepidermoid carcinomas are of low-grade and tend to be a T1 lesion on the palate when smaller than 2 cm in diameter since this classification is given to tumors with diameters smaller or equal to that. In these cases, therefore, the prognosis may be

good if excision is adequate. However, in those cases of the local invasion, the bone resection of palate is needed.¹

Eversole et al., (1972) reported 17 cases of low- and intermediate-grade tumors which were treated with local and wide excisions, respectively. The bone was removed only when there was erosion, resulting in a healing rate of 100%.¹¹ This therapeutic technique preserving the adjacent bone, if not directly invaded, is supported by imaging examinations.^{1,2,9} Diagnoses and treatments of diseases have been improving by the advances in the image acquisition and processing methods with the purpose of health. There are currently several image acquisition methods available for practitioners to make a diagnosis using visualization techniques for human body exploration, which are helpful and often fundamental in therapeutic decisions.

The InVesalius software is open-code and allows 3D-reconstruction of body human structures, including volume and measurement of lesions in the bone. In addition, to re-create anatomic structures in 3-D, this software can determinate the volume of the neoplasm lesion based on thresholds and manual segmentation of CT slices. The neoplastic structure is manually directed by using the brush tool for axial, coronal or sagittal cuts obtained from CT scans, thus providing a 3D representative image of the tumor as well as of the skeleton, which appears automatically due to pre-established thresholds.

The volumetric image can be observed at different angles and, when magnified, its transparency can be individually changed to allow the analysis of the relationship between the lesion and bone structure involved. With those elements, it is allowed the development of a surgical planning based on the topography of mucoepidermoid carcinoma.⁷ Considering both surgical approaches for mucoepidermoid carcinoma and palate, local excision and wide bone resection depend not only

on local invasion, but also on three-dimensional reconstruction, and segmental volumetric analyses, and as such they should be performed for personalized treatment, individualized care and post-operative analysis of patients. The present case report shows how the 3D reconstruction of a tumor emphasizes larger areas and their proximity to bone tissue and around the tumor – a factor which can help the surgeon decide whether a wide bone resection is actually needed.

The software allows combining a CT slice with the 3D reconstruction of the tumor to produce a single image of it, as shown in Figure 5D. It is also possible to produce a single image of the tumor combining a specific CT slice with a 3D reconstruction of it (Figures 4B and 4C), which allows personalizing the surgical treatment for a specific tumor. One can also observe the same segmented area of other CT slices, which appear automatically.

We have presented in this case report 3D images obtained with InVesalius software showing tumor invasion into the maxillary sinus and nasal fossa, which helped us select wide bone resection as surgical treatment. Therefore, this study shows the importance of 3D-reconstruction for surgical planning, with regard to mucoepidermoid carcinomas on the palate, because this resource can provide the surgical team with clearer information on the shape and location of the lesion compared to 2D images, CT images or MRI individually.^{7,9} Consequently, precise spatial and structural information (e.g. tumor volume index) might be added to the surgery planning for evaluation of the long-term outcome.

The present case agrees with the previous literature, which one of the factors that most influence spatial resolution in vivo is the mean voxel density, or mean volume. Often, voxel size is larger than the object or its density. This occurs more often along the edge of an object or on the

edges of two structures with different densities. The voxel can only show one shade of gray at a time (by a numerical value) and, as a result, the voxel will show an average of the density. This process can make boundaries between densities more difficult to distinguish accurately and results in lower spatial resolution of the image. Thinner bone regions are especially susceptible to being calculated by the mean volume.

The most effective method to decrease the influence of mean volume is to decrease the size of the voxel to be used. However, there is a disadvantage when using smaller voxels since they require greater radiation dose for adequate exposure, increasing the dose of patients and also the likelihood of increased noise in the images. Thus, the 0.25mm voxel is a medium voxel, which does not lead to a partial volume effect so pronounced, but also does not generate such high noises.

CONCLUSIONS

Open-code software, like the one used here, is potentially useful for virtual analysis with low cost and unrestricted accessibility, thus playing an important role in diagnosis and intra-operative guidance prior to surgeries.

The need to perform bone resection for low-grade mucoepidermoid carcinomas on the palate is determined by the local invasive characteristics of the tumor, concluding that 3D planning in the treatment of this type of tumor allows better precision and a more detailed evaluation of the surgery option depending on each case.

REFERENCES

1. Ord RA, Salama AR. Is it necessary to resect bone for low-grade mucoepidermoid carcinoma of the palate? *Br J Oral Maxillofac Surg.* 2012;50(8):712-4. doi: 10.1016/j.bjoms.2012.01.007
2. Moraes P, Pereira C, Almeida O, Perez D, Correa ME, Alves F. Paediatric intraoral mucoepidermoid carcinoma mimi-

- cking a bone lesion. *Int J Paediatr Dent.* 2007;17(2):151-4. doi: 10.1111/j.1365-263X.2006.00770.x
3. Martins TH, Bonardi JP, Stabile GA, Ito FA, Pereira-Stabile CL, Hochuli-Vieira E. Mucoepidermoid carcinoma of the hard palate in a young patient. *J Craniofac Surg.* 2016;27(7):e598-e599. doi: 10.1097/SCS.0000000000002909
 4. Ata N, Ünverdi H. Parotid mucoepidermoid carcinoma mimicking a large mucocele. *J Craniofac Surg.* 2018;29(3):e295-e296. doi: 10.1097/SCS.0000000000004329
 5. Kumar R, Natarajan S, Sneha KS, Chitra NS, Boaz K, Manaktala N. Oncocytes in mucoepidermoid carcinoma of the palate: diagnostic challenges. *Case Rep Dent.* 2017;2017:5741821. doi: 10.1155/2017/5741821
 6. Baumgardt C, Günther L, Sari-Rieger A, Rustemeyer J. Mucoepidermoid carcinoma of the palate in a 5-year old girl: case report and literature review. *Oral Maxillofac Surg.* 2014;18(4):465-9. doi: 10.1007/s10006-014-0461-6
 7. Gomes JP, Costa AL, Chone CT, Altemani AM, Altemani JM, Lima CS. Three-dimensional volumetric analysis of ghost cell odontogenic carcinoma using 3-D reconstruction software: a case report. *Oral Surg Oral Med Oral Pathol Oral Radiol.* 2017;123(5):e170-e175. doi: 10.1016/j.oooo.2017.01.012
 8. Herd MK, Murugaraj V, Ghataura SS, Brennan PA, Anand R. Low-grade mucoepidermoid carcinoma of the palate—a previously unreported case of metastasis to the liver. *J Oral Maxillofac Surg.* 2012;70(10):2343-6. doi: 10.1016/j.joms.2011.11.019
 9. Li Q, Zhang XR, Liu XK, Liu ZM, Liu WW, Li H, Guo ZM. Long-term treatment outcome of minor salivary gland carcinoma of the hard palate. *Oral Oncol.* 2012;48(5):456-62. doi: 10.1016/j.oraloncology.2011.12.005
 10. Rocha LA, Brasil Moreira AE, Pereira Neto JS, Vargas PA, Lopes MA. Mucoepidermoid carcinoma diagnosed in orthodontic patients. *Am J Orthod Dentofacial Orthop.* 2010;138(3):349-351. doi: 10.1016/j.ajodo.2008.08.038
 11. Eversole LR, Rovin S, Sabes WR. Mucoepidermoid carcinoma of minor salivary glands: report of 17 cases with follow-up. *J Oral Surg.* 1972;30(2):107-12.