

# DSD and CAD/CAM integration in the planning and execution of an oral rehabilitation procedure: a case report

• **Marina Medeiros Toste Coelho dos Santos** School of Dentistry, Department of Prosthodontics, Pontifícia Universidade Católica do Rio de Janeiro, Rio de Janeiro, RJ, Brazil • **Adriano Relvas** School of Dentistry, Department of Prosthodontics, Pontifícia Universidade Católica do Rio de Janeiro, Rio de Janeiro, RJ, Brazil • **Bárbara Vieira** School of Dentistry, Department of Prosthodontics, Pontifícia Universidade Católica do Rio de Janeiro, Rio de Janeiro, RJ, Brazil • **Renata Ventura** School of Dentistry, Department of Prosthodontics, Pontifícia Universidade Católica do Rio de Janeiro, Rio de Janeiro, RJ, Brazil • **Ângelo Raphael Segundo** School of Dentistry, Department of Prosthodontics, Universidade Federal do Rio de Janeiro, Rio de Janeiro, RJ, Brazil • **Sérgio Saraiva** School of Dentistry, Universidade Federal do Ceará, Ceará, RJ, Brazil

**ABSTRACT** | This article presents a clinical case involving the integrated application of CAD/CAM and DSD. DSD – Digital Smile Design – assists in obtaining a treatment plan adjusted to the patient’s facial features, achieving the best aesthetic potential. The integration between DSD and CAD/CAM allows for greater fidelity in respect to the original plan. A patient received a rehabilitation with veneers milled out of leucite-reinforced feldspathic ceramics, using the CAD/CAM system and a DSD-obtained digital wax-up. This workflow simplifies design and fabrication, providing greater accuracy and predictability to the rehabilitation process. The digital planning and development of the mockup also makes clinical conditions more predictable. Making ceramic veneers using the CAD/CAM technique requires judicious adhesive cementation, and also an accurate practical and theoretical knowledge on the part of the professional.

**KEYWORDS** | Ceramic Veneers; DSD; CAD/CAM; Adhesiveness; Leucite; Oral Rehabilitation.

**RESUMO** | **Integração de DSD e CAD/CAM no planejamento e execução de um procedimento de reabilitação oral: um estudo de caso** • Este artigo apresenta um caso clínico envolvendo a aplicação integrada de CAD/CAM e DSD. O DSD – Digital Smile Design – auxilia na obtenção de um plano de tratamento ajustado às características faciais do paciente, alcançando o melhor potencial estético. A integração entre DSD e CAD/CAM permite maior fidelidade em relação ao plano original. Um paciente recebeu uma reabilitação com facetas fresadas de cerâmica feldspática, reforçada com leucita usando o sistema CAD/CAM, e um encerado digital obtido por DSD. Esse fluxo de trabalho simplifica o projeto e a fabricação, proporcionando maior precisão e previsibilidade ao processo de reabilitação oral. O planejamento digital e o desenvolvimento da maquete também tornam as condições clínicas mais previsíveis. A preparação de facetas cerâmicas usando a técnica CAD/CAM requer cimentação adesiva criteriosa e também um conhecimento prático e teórico preciso por parte do profissional.

**DESCRITORES** | Facetas de Cerâmica; DSD; CAD/CAM; Aderência, Leucita; Reabilitação Oral.

**CORRESPONDING AUTHOR** | • **Adriano Relvas Barreira de Oliveira** School of Dentistry, Department of Prosthodontics, Pontifícia Universidade Católica do Rio de Janeiro • **Rua Marquês de São Vicente, 389** Rio de Janeiro, RJ, Brazil • **22451-041** E-mail: [relvasrj@yahoo.com.br](mailto:relvasrj@yahoo.com.br)

• **Received** Nov. 19, 2018 • **Accepted** Nov. 28, 2018  
• **DOI** <http://dx.doi.org/10.11606/issn.2357-8041.clrd.2019.151911>

## INTRODUCTION

In the past 30 years, restorative dentistry has undergone a major revolution. Treatments' guiding principle used to be clinical durability, with barely any consideration for patients' aesthetic concerns. Nowadays, however, ceramics—presenting a wide range of translucency nuances and effects—is the leading dental restorative material. The initial applications of ceramics had aesthetic drawbacks, due to the ceramic having to be applied into metal to compensate for its lackluster mechanical properties. In this context, the increased demand from patients and the development of ceramic materials prompted a new era of fully functional ceramic restorations. This was made possible by increasing crystalline content and changing formats, and also by improvements in the preparation of the restorations, increasing its clinical durability. Thus, traditional techniques, such as stratification and injection, that incorporate failures into the material, have been replaced by the CAD—CAM (computer-aided design—computer-aided manufacturing) system, leading to fewer internal defects and, consequently, lower risk of fracture, as well as satisfactory aesthetics, less preparation time, and a less sensitive overall technique.<sup>1</sup>

Recently, minimally invasive restorative dentistry has been propelled by the evolution of adhesive systems, resinous luting agents, and dental ceramics. Partial conservative preparations may be indicated with better predictability. Adhesive procedures contribute to lessen or avoid marginal microleakage and postoperative sensitivity, and increase the teeth structure's retention of restoration and resistance to fracture. Therefore, the correct conditioning of the ceramic surface contributes to the durability of the restorative procedure.<sup>2</sup>

In addition to the clinical-radiographic test and study models, photographs aid in the diagnostic process, and are indispensable for carrying out an individualized and aesthetically adequate treatment plan across several specialties, associating

format, biology, and function. Besides enabling the visualization of details difficult to be seen with the naked eye, photographs are also a good tool for communication with the patient and with the prosthesis laboratory, since it provides data concerning the entirety of facial features.<sup>3</sup>

Digital Smile Design (DSD) is a multiple-use conceptual tool that can strengthen the diagnostic view even further, improving communication and enhancing predictability throughout the treatment. DSD allows for the analysis of dental and facial features of the patient along with any critical factors that may have been neglected during clinical, photographic, and anamnesis procedures. The design of reference lines and forms on extra- and intra-oral digital photographs following a predetermined sequence can broaden the diagnostic view and help the team in their assessment of limitations and risk factors.<sup>4</sup>

To make a two-dimensional plan three-dimensional, DSD can be turned into a 3D digital wax-up, based on the scanned image of an intra-oral or plaster study model, which can then be digitally waxed, following the original design. This is performed with the *NemoSmile Design 3D* software, which allows for the mockup (in Polymethyl methacrylate – PMMA), as well as the temporary and definitive restorations from the CAD/CAM system, to be individually prepared.

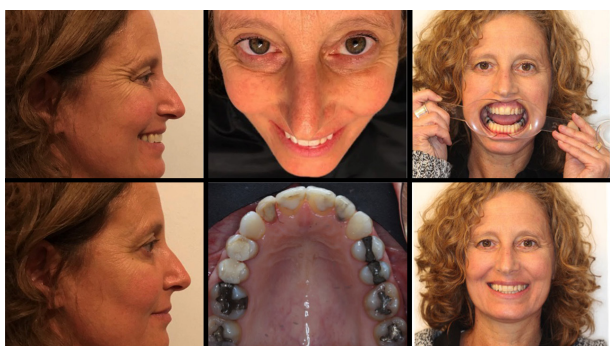Even though the use of fully digital protocols is already reality in current dentistry, there are still doubts about the indication, advantages, and disadvantages of this treatment option. This article presents a clinical case in which the CAD/CAM technology and the DSD technique were employed jointly during planning and execution of a restorative procedure, under the same functional parameters that guide a traditional prosthetic rehabilitation.

## CASE REPORT

Patient VP, 50 years old, female, leukoderma, sought a private practice with her main complaint regarding the shape and color of her teeth. The

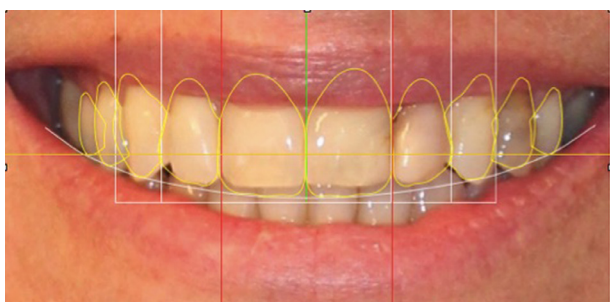patient had gone through many previous restorations, made at different times throughout her life.

The first appointment aimed to collect as much information as possible, performing anamnesis; aesthetics interview; clinical examination; photographic protocol—photos of smiling profile and profile at rest with lips sealed, 12-hour photo, occlusal photo, and frontal photos with and without lip retractor (Figure 1); videos (spontaneous smile capture); intra-oral scanning with CEREC Omnicam (Vita Zahnfabrik, Bad Sackingen, Germany); and CT scans. This process amounted to a “digital clone” of the patient’s facial features.



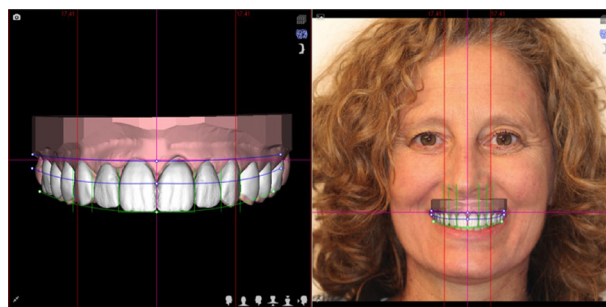
**Figura 1** | Photographs of smiling profile, and profile at rest; 12-hour photograph; Occlusal photograph; Smiling frontal photograph; Frontal photograph with lip retractor.

After completing this first step, a 2D Digital Smile Design (DSD) was performed (Figure 2). This consisted of determining the patient’s ideal smile based on the previously collected photos and videos. The 2D natural teeth template to be used in the restorative procedure was also chosen, from professor Jan Hajto’s digital library.

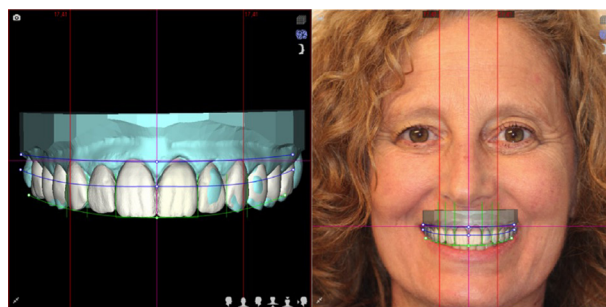


**Figura 2** | DSD 2D.

The completed 2D DSD and the STL-format file generated by intra-oral scanning were sent to the DSD Planning Center, in Madrid, where two types of 3D digital wax-up were carried out: one for making the motivational mockup using additive volume (Figure 3), and another comprised of the ideal digital wax-up (Figure 4). These were the basis for two new STL files, which were generated using *inLab 15* software (Dentsply Sirona, Bensheim, Germany) and sent back to the laboratory.



**Figura 3** | 3D digital wax-up for motivational mockup.



**Figura 4** | Ideal 3D digital wax-up, prior preparation.

The STL file for the motivational mockup was opened in the software and integrated with the patient’s working model, allowing for the milling of polymethyl methacrylate (PMMA) veneers (Vipi Block Trilux, São Paulo, Brazil). The second STL file, containing the ideal digital wax-up, was printed using the 3D FormLabs 2 printer (Formlabs, Massachusetts, USA), so as to produce the guiding mockup for dental preparation.

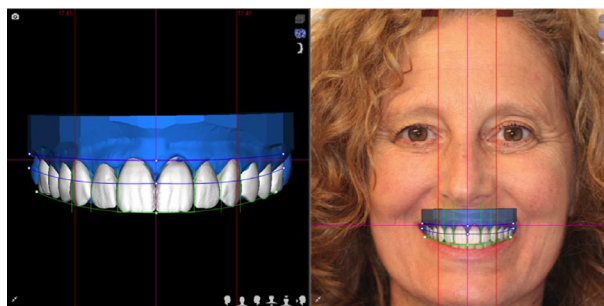
The second appointment aimed to test the motivational mockup, which allows for a preview of treatment results without any type of dental

preparation actually being carried out. PMMA veneers were cemented with the Natural Flow A2 resin flow (Nova DFL, Rio de Janeiro, Brazil), without any prior conditioning of the veneers or dental tissues. After diagnosis, prognosis and patient's approval, the treatment plan was chosen (ceramic veneers from the first right premolar to the first left premolar).

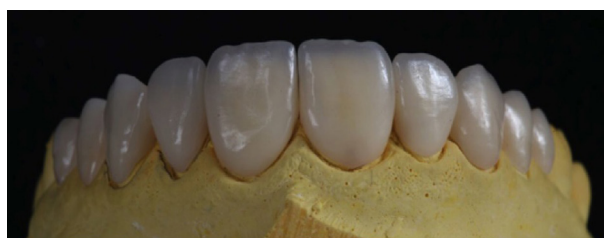Clinical procedures began during the third appointment. After inserting an intra-sulcular retraction cord Ultrapak 00 (Ultradent, São Paulo, Brazil), a bis-acryl resin (Structur 2 SC, Voco Brasil, Rio Grande do Sul, Brazil) mockup was made from a silicone index (Futura AD, Nova DFL, Rio de Janeiro, Brazil), based on the ideal digital wax-up printed model. The preparation procedures were performed using the KG dental drills (KG Sorensen, São Paulo, Brazil) over the mockup. After finishing the preparations, the retraction cord was removed and replaced by two Ultrapak retraction cords in the gingival sulcus, spanning from the first right premolar to the first left premolar, the first one with a smaller diameter (000) and the second one with a larger diameter (00). After removing the larger retraction cord, tooth preparations, antagonists and bite registration were scanned using the CEREC Omnicam. Transitional veneers were made from bis-acryl resin, according to the same index used in the mockup.

The new STL file generated by the intra-oral scanning of tooth preparations was once again sent to the DSD Planning Center, to be overlapped with the ideal digital wax-up, resulting in the DSD digital 3D "over the prep" (Figure 5). The file was sent to the laboratory licensed to use *inLab* 15, where the "over the prep" wax-up was integrated with the prepared model, thus allowing the milling of veneers from blocks of leucite-reinforced feldspathic ceramics from IPS Empress Cad Multi (Ivoclar Vivadent, Schaan, Liechtenstein), using the *inLab* MC XL milling machine (Dentsply Sirona, Bensheim,

Germany). This procedure allowed for a faithful representation of the initial DSD plan (Figure 6).

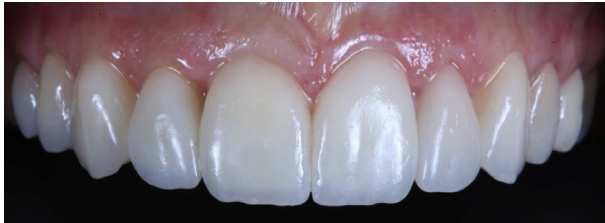

**FIGURA 5** | Over the prep 3D digital wax-up.



**FIGURA 6** | Leucite-reinforced feldspathic ceramics, IPS Empress CAD Multi.

In the cementing appointment, the inner surfaces of the ceramic veneers were etched with 10% hydrofluoric acid (Dentsply, Rio de Janeiro, Brazil) for 60s and rinsed with water for over 60s, air-dried, and then received a silane coupling agent (Monobond Plus, Ivoclar Vivadent, Liechtenstein). The dental tissues were etched with 37% phosphoric acid (Dentsply, Rio de Janeiro, Brazil) for 30s, rinsed with water, and gently dried. A thin adhesive system (Tetric® N-Bond Universal adhesive, Ivoclar Vivadent, Schaan, Liechtenstein) layer was applied, without precuring. After 60s, the resin cement Variolink Esthetic LC warm (Ivoclar Vivadent, Schaan, Liechtenstein) was applied on the inner surface of the ceramic veneers. The final shades were selected by trial and error using try-in pastes. After placement of the ceramic veneers, cement excesses were removed using a brush. A LED curing unit with a light intensity of 1.200 mW/cm<sup>2</sup> (Bluephase N, Ivoclar Vivadent, Liechtenstein) was used to cure the resin cement in each tooth for a minimum of 30s (Figure 7).



**FIGURA 7** | Intraoral photograph of immediate cementation of ceramic veneers.

The treatment was completed (Figure 8) after carrying out occlusal adjustments and polishing the margins with goat hairbrushes, as well as sequential diamond polishing pastes (Porcelize, Cosmedent, São Paulo, Brazil).



**FIGURA 8** | Final frontal photograph.

## DISCUSSION

The use of CAD/CAM in dentistry was initially developed for the manufacturing of indirect restorations, such as inlays, onlays, crowns, and veneers<sup>5</sup>. More recently, due to significant technological development, systems used both in clinical practice and laboratories evolved to provide a wider range of dental surgery clinical applications.

In the clinical case described here, planning by means of DSD/CAD/CAM integration enabled the errors usually associated with classical manual steps to be minimized, and improved the accuracy of the prosthetic procedures. All the three-dimensional planning data generated by the clinic was able to be digitally transferred to a laboratory, where this information was successfully translated

by the CAD/CAM system, making the restorative process simpler, faster, and more predictable.<sup>6</sup> This procedure allowed for the closure of small diastemas, the alignment and leveling of the upper dental arch of the patient, and for changing teeth color, solving the patient's main complaint.

Several techniques are employed in the planning and implementation of ceramic veneers, with physical wax-up being the most well-known. However, 'analogical' techniques, based on static clinical, radiographic, and photographic planning, do not allow for a pre-procedure assessment of smile design. Such techniques are restricted to two-dimensional workflows and require the preparation of plaster models, the classic wax-up of the model, and the development of the mockup using a silicone index. This entire manual process, which is difficult and potentially error-prone, has to be performed before transmitting the virtual project containing the measurements of dental elements of the new smile to the laboratory,<sup>6</sup> as opposed to an all-digital planning based on videos and photographs for milling the laminates.

The digital workflow with intra-oral digital impression instead of conventional molding enhances patient well-being by reducing chairside time and simplifying the 4-appointment prosthodontic protocol. Moreover, comparative studies have shown that intra-oral digital impressions present similar or superior precision to conventional moldings.<sup>7</sup>

The choice of material and manufacturing techniques to be used in the definitive veneers is a step that cannot be neglected. Stratified feldspathic ceramics provide excellent aesthetic features, with a relatively high survival rate (between 84.7% and 96.6% within 6-7 years' follow-up), although the use of this material is laboratory-dependent. Microporosity and non-homogeneity between particles can be caused by malpractice in the sintering process. However, the mechanical properties of glass-matrix ceramics have been

improved by the incorporation of leucite particles. These glass-matrix ceramics can be manufactured by sintering and injection techniques and by means of blocks that are premanufactured for CAD/CAM milling, featuring more uniform characteristics without the errors inherent in the manual technique.<sup>8</sup> Hence, aiming at maximum fidelity in respect to the digital wax-up and considering the aforementioned advantages, we opted for the leucite-reinforced feldspathic ceramic veneers, and for the CAD/CAM technique.

The mockup step allows the patient to preview the treatment's result without undergoing any dental preparation. In order to follow the fully digital protocol, the new smile's testing sample was obtained via polymer milling by the CAD/CAM technology. In this respect, polymethyl methacrylate (PMMA) and polyetheretherketone (PEEK) are the most used polymers. PEEK shows remarkable mechanical characteristics, but it has a greyish or pearly white opaque color, requiring it to be covered with composite resin. On the other hand, PMMA not only presents a low risk of incorporating porosities, but also excellent mechanical properties<sup>9</sup> and favorable aesthetics, allowing for a wide range of colors very similar to that of the human teeth. Considering this, PMMA is the indicated choice for the manufacturing of an individualized mockup.

A rigorous protocol of adhesive cementation was employed, with several advantages over conventional cementation, such as resistance to compression and traction, low solubility, and aesthetic quality. The choice of a photopolymerized luting agent was due to the thickness<sup>10</sup> of the ceramic restoration, and also its clinical advantages, such as color stability (a clear advantage over the dual-resin and chemically activated cements, which feature tertiary amine in their composition); wide range of colors available in the market; increased working time during the cementation, and ease of execution.

## CONCLUSION

Correct diagnosis and planning are key to the accuracy of the dental treatment, assisting in organizing clinical workflow, minimizing complications, and providing safety to the patient. The digital planning and development of mockups confers more predictability to the clinical case. The use of ceramic veneers made using CAD/CAM requires judicious adhesive cementation, as well as precise practical and theoretical knowledge on the part of the professional.

## REFERENCES

1. Cardoso P, Decurcio R. *Facetas: lentes de contato e fragmentos cerâmicos*. 3rd ed. Florianópolis: Ponto; 2015. 565 p.
2. Özcan M, Alkumru HN, Gemalmaz D. The effect of surface treatment on the shear bond strength of luting cement to a glass-infiltrated alumina ceramic. *Int J Prosthodont*. 2001 Jul-Aug;14(4):335-9.
3. Bottino MA, Faria R, Balandro LF. Percepção: estética em próteses livres de metal em dentes naturais e implantes. São Paulo: Artes Médicas; 2009. 804 p.
4. Coachman C, Calamita M. Digital smile design: a tool for treatment planning and communication in Esthetic Dentistry. *QDT*. 2012;35:1-9.
5. Fasbinder DJ. Clinical performance of chairside CAD/CAM restorations. *J Am Dent Assoc*. 2006 Sep;137:22S-31S.
6. Cattoni F, Mastrangelo F, Gherlone EF, Gastaldi GA. A new total digital smile planning technique (3D-DSP) to fabricate CAD-CAM mockups for esthetic crowns and veneers. *Int J Dent*. 2016 May;2016:1-5. doi: <http://dx.doi.org/10.1155/2016/6282587>.
7. Amin S, Weber HP, Finkelman M, Rafie KE, Kudara Y, Paspapyridakos P. Digital versus conventional full-arch implant impressions: a comparative study. *Clin Oral Implants Res*. 2017 Nov;28(11):1360-67. doi: 10.1111/clr.12994.
8. Martin N, Jedynekiewicz NM. Clinical performance of CEREC ceramic inlays: a systematic review. *Dent Mater*. 1999 Jan;15(1):54-61.
9. Stawarczyk B, Liebermann A, Eichberger M, Guth JF. Evaluation of mechanical and optical behavior of current esthetic dental restorative CAD/CAM composites. *J Mech Behav Biomed Mater*. 2015 Mar;55:1-11. doi: 10.1016/j.jmbm.2015.10.004.
10. Christensen, GJ. Thick or thin veneers? *J Am Dent Assoc*. 2008 Nov;139(11):1541-3.