

CASE REPORT

UMBILICAL MASS AS THE SOLE PRESENTING SYMPTOM OF PANCREATIC CANCER: A CASE REPORT

Fábio Crescentini, Fernanda Deutsch, Carlos Walter Sobrado and Sérgio de Araújo

CRESCENTINI F et al. Umbilical mass as the sole presenting sign of pancreatic cancer: a case report. *Rev. Hosp. Clín. Fac. Med. S. Paulo* 59(4):198-202, 2004.

Umbilical nodes are rare. The metastatic involvement of the region was first described in 1846. Sister Mary Joseph was the first observer to establish the correlation between carcinomas and umbilical nodes. The umbilical node may be the sole presenting sign of cancer and is usually associated with advanced disease and poor prognosis.

A 64-year-old woman, previously healthy, presented vague abdominal discomfort and a hard umbilical nodule for 1 week, which was first diagnosed as an incarcerated umbilical hernia. She underwent a new clinical assessment and biopsy. After immunohistochemical analysis and computerized tomography, she was diagnosed with pancreatic cancer.

The clinical staging showed advanced disease with distant metastasis. She received palliative chemotherapy. After 8 months, she was alive in poor clinical condition.

Clinical suspicion should lead to a careful additional evaluation whenever an umbilical nodule presents with malignant signs.

KEY WORDS: Sister Mary Joseph's nodule. Umbilical mass. Unknown primary site. Cancer.

Tumors of the umbilicus are rare. The metastatic involvement of the region due to visceral carcinomas is even less frequent.^{1,2} The first medical report of such a condition was by Walshe et al. in 1846, through the Tanchov's review of data. The author found only 2 cases of umbilical involvement among 9118 deaths from cancer in the period of 1830 to 1840.¹ In 1864 Storer et al. reported the first complete case study of a metastatic umbilical nodule due to gastric adenocarcinoma.³ However, the association of umbilical masses and visceral carcinomas was firmly established after the clinical observations of a nurse from the Mayo Clinic (Rochester, USA). Her name was attributed to this clinical feature, which was

designated as "Sister Mary Joseph's" sign.

Even though it is a rare clinical finding, an umbilical mass may be the sole presentation of malignant tumors.^{4,5} Shetty¹ reviewed all cases related to "Sister Mary Joseph's nodule" published until 1989. This review found a total of 265 cases and 85 nodules from unknown primary tumors. Concerning pancreatic tumors, only 12 cases had been reported.³⁻¹⁰ We found

From the Department of Gastroenterology, Division of Gastrosurgery and Coloproctology, Hospital das Clínicas, Faculty of Medicine, University of São Paulo – São Paulo/SP, Brazil.

E-mail: sobrado@iconet.com.br

Received for publication on
September 16, 2003.

only 1 description¹¹ since 1989, and in 1998 the metastatic involvement of the umbilicus from a pancreatic cancer was exhibited as the image of the month in *Gastroenterology*¹². We undertook this bibliographic research using the PubMed database and the following keywords: "Sister Mary Joseph's nodule", unknown primary tumor, pancreatic cancer, umbilical metastasis.

A careful clinical examination and extensive diagnostic procedures should be performed for all patients presenting with umbilical nodules. To illustrate and emphasize this point, we report a case of an umbilical mass as the only presenting sign of adenocarcinoma of the pancreas.

DESCRIPTION OF THE CASE

A 64-year-old woman presented with a 3-month history of vague abdominal discomfort in the epigastric region, with no irradiation sites, slowly progressive, and not related to food intake. She had noticed an umbilical nodule the previous week. She did not present with weight loss, fever, or other systemic symptoms. She denied having cardiorespiratory discomfort or gastrointestinal complaints. Her referral doctor (general practice) first diagnosed the mass as an incarcerated umbilical mass. A surgeon re-examined and re-evaluated the patient. She presented in good general condition, well nourished, no palpable masses at the cervical, abdominal, or thoracic regions. On physical examination, a peri-umbilical nodule of 2 by 2 cm was noted, which was hyper-pigmented, indurated, discretely painful, and produced a fetid discharge.

Routine laboratory investigation showed normal results. The sonographic scan of the abdomen showed no abnormalities. At the first physical and laboratory investigation, the patient presented evidence of tumoral disease, with unknown primary tumor. Therefore, the umbilical nodule was resected for diagnostic purposes and an anatomic-pathologic analysis was performed (Figure 1), which showed a mucinous, poorly differentiated metastatic adenocarcinoma, suggestive of a GI tract (stomach or pancreas) or ovarian cancer. Immunohistochemical analysis was positive for cytokeratin 7 and negative for cytokeratin 20. This finding suggested a primary site at stomach or pancreas.

Due to the anatomic-pathologic findings, an abdominal CT scan was performed. The exam showed a cystic and solid tumor of 6 cm in the pancreatic body (Figure 2). For staging purposes, a thoracic CT scan was also performed, and several pulmonary nod-

ules, diagnosed as metastases, were encountered (Figure 3). The brain CT scan showed no abnormalities.

The patient was referred to the medical oncology service for palliative chemotherapy because of advanced pancreatic cancer with perito-

neal dissemination and lung metastases. Even though the patient was alive 8 months after the diagnosis, she progressively deteriorated and presented in poor clinical condition. She had undergone thoracocentesis 3 times for relief of severe dyspnea.

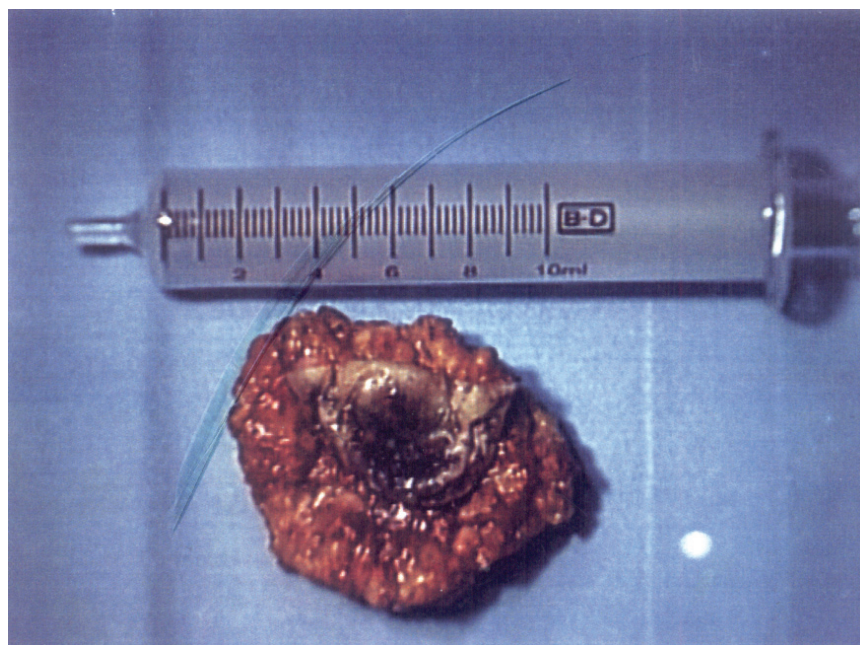


Figure 1 – Resected nodule (hardened and dark).

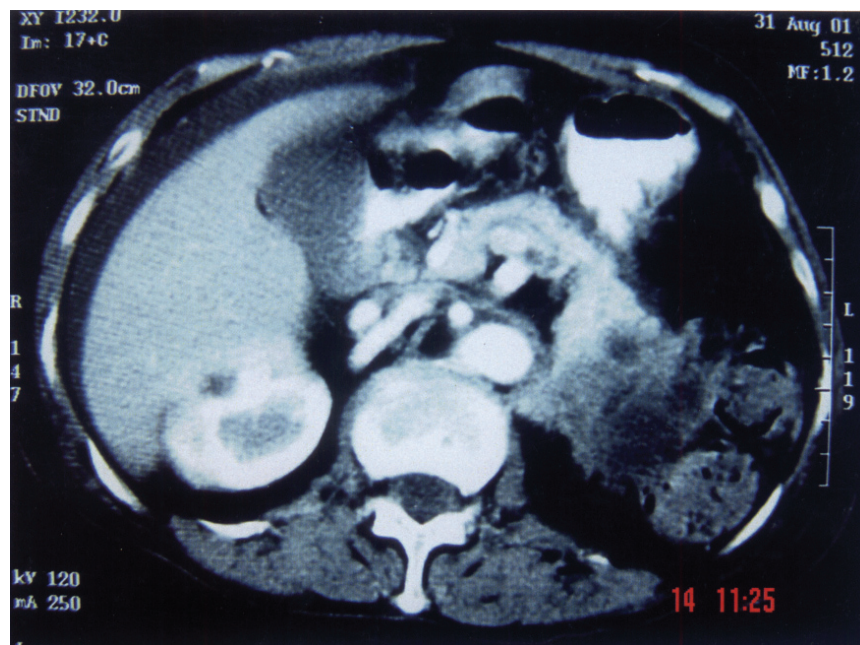


Figure 2 – Abdominal CT scan with IV contrast (cystic lesion with solid components in the pancreatic body).

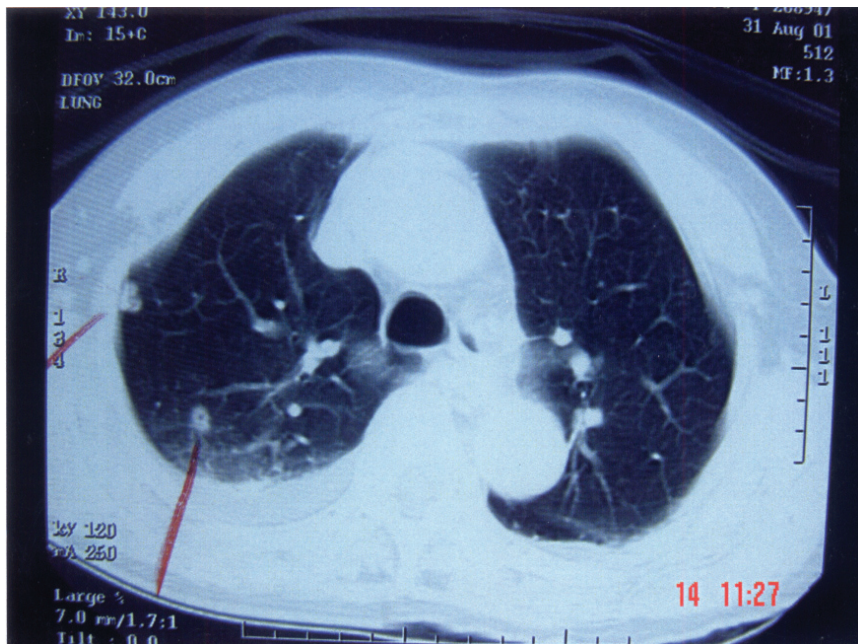


Figure 3 – Thoracic CT scan (pulmonary window) - several nodules (suggestive of metastases).

DISCUSSION

The finding of an umbilical nodule as the only clinical manifestation of a disease leads to several possible diagnoses including umbilical hernia, granuloma, attachments of the urachus, pilonidal sinus, omphalomesenteric duct abnormalities, endometriosis, and benign and malignant tumors.⁷⁻¹³ Benign lesions are diagnosed in the vast majority of cases, and the finding of the metastatic involvement of the umbilical region is rare.⁸⁻¹⁴ Shetty et al. reviewed all cases of malignant disease at the umbilicus from 1830 to 1989 and found only 265 cases previously published; 85 cases of umbilical metastasis from unknown primary origin were found.¹

Several modes of spreading to the umbilicus have been discussed. Metastasis to the umbilicus may occur due to proximity to the tumor, hematogenic and lymphatic dissemination, or via umbilical ligaments. The most prevalent form of umbilical involvement is related to direct invasion of peritoneal metastasis. The retrograde flux from superficial and deep

lymphatic systems originated at axillary, inguinal, and para-aortic nodes may lead to umbilical involvement. Another possible form involves venous communication between the lateral thoracic veins and internal mammary vein with the portal circulation.¹⁴ Therefore, theoretically, all types of cancer may disseminate to the umbilical region. However, the most prevalent primary sites are from intra-abdominal origin. Shetty (1990) reviewed cases of umbilical metastasis previously published and found that 42% originated at the abdomen or pelvis, mainly from the GI tract, classified as follows: gastric cancer 17%, large bowel 6%, pancreas 6%, gallbladder 3%, and small bowel 1%. He also found a large prevalence among tumors from the female genital tract, accounting for 9% of all cases. Other primary sites, such as lung, cervix, fallopian tube, and melanoma were rare and represented 1% of patients. However, this data should be analyzed cautiously since it was partially obtained before modern radiological techniques. Nearly 30% of cases had an unknown primary site.¹ In the present case report,

the lymphatic spread from the pancreatic body to the umbilicus originated mostly through the splenic and para-aortic nodes, as described by Donatini et al.¹⁵ Although there were no signs of carcinomatosis in the reported case, the umbilical involvement due to proximity to the primary site should always be investigated.

The metastatic umbilical nodule, known as Sister Mary Joseph's nodule, is morphologically firm, an indurated plaque or nodule with a vascular appearance, and may be fissured and ulcerated with some fetid discharge. However, it may also present as an uncharacteristic diffuse hardening of the umbilical region or as a profound node.¹⁶ Steck et al. observed that in 45% of their patients, the umbilical node was the only clinical sign of cancer. This figure demonstrates the importance of an evaluation of all umbilical lesions, especially in patients after the fifth decade of life.¹³

For diagnostic purposes, radiological methods and the anatomic-pathological analysis are extremely important. The microscopic analysis is especially attractive in such cases due to the favorable localization of umbilical nodes. The usual evaluation with hematoxylin-eosin may differentiate primary and metastatic tumors. Moreover, immunohistochemical analysis may define the cellular origin in 72% of cases of unknown primary tumor.¹⁷ The use of electronic microscopy and cytogenetic analysis may enhance the diagnostic sensitivity and specificity of the diagnosis. Edoute et al. Analyzed the cytologic material of 14 patients using fine-needle aspiration. The method had a sensitivity as high as 92.8% and a positive predictive value of 100%. Only 1 case was diagnosed as a false negative, since no inflammatory cell-containing aspiration was obtained.² Therefore, although it is a safe diagnostic method, the cytologic evaluation using fine-needle aspiration

should be properly indicated and may not replace the full anatomic-pathologic analysis. Moreover, radiological exams, such as ultrasound imaging, CT scan, or MRI have a poor cost-benefit relationship due to their low diagnostic power. Those methods should be preserved for staging purposes or for special cases when the pathologist evaluation is not possible.

The metastatic spread to the um-

bilical region representnaan advanced stage of the primary disease and worsened prognosis. Consequently, palliative treatment is usually the only remaining therapeutic option. However, as previously discussna, an umbilical nodule may be the only presenting sign of cancer, enhancing the diagnosis before the appearance of more exuberant features, such as ascites, pulmonary masses, and bone metastasis,

which are responsible for decreased quality of life and overall survival even after the administration of palliative treatment.

Even though it is a rare finngang, an umbilical mass may be the first manifestation of neoplastic disease, as was observed in the present case. Therefore, the clinical suspicion and diagnostic evaluation are extremely important for therapeutic and prognostic purposes.

RESUMO

CRESCENTINI F e col. Nódulo umbilical como única apresentação clínica de tumor pancreático: relato de caso. **Rev. Hosp. Clín. Fac. Med. S. Paulo** 59(4):198-202, 2004.

Nódulos umbilicais são raros. Desde 1846, o comprometimento metastático da região vem sendo descrito. A Irmã Mary Joseph foi a primeira a relacionar o aparecimento de nódulos umbilicais com carcinomas. Esses nódulos podem ser a única manifestação

de câncer, normalmente associada a estádios avançados e pior prognóstico.

Uma senhora de 64 anos, previamente hígida, apresentava desconforto abdominal inespecífico e aparecimento de nódulo umbilical endurecido há uma semana. O diagnóstico inicial foi hérnia umbilical encarcerada. Após reavaliação, o nódulo foi biopsiado, cujo exame anátomo-patológico demonstrou carcinoma com sítio primário desconhecido. Á análise imuno-histoquímica e tomografia, o diagnóstico foi carcinoma de pâncre-

as. O estadiamento demonstrou doença avançada, com metastases à distância. A paciente foi submetida a quimioterapia paliativa. Após 8 meses, encontrava-se em mau estado geral.

A suspeita clínica deve originar avaliação clínica cuidadosa, auxiliada por exames subsidiários, sempre que um nódulo umbilical apresentar sinais de malignidade.

UNITERMOS: Nódulo Sister Mary Jpseph. Massa umbilical. Tumor primário desconhecido. Cancer.

REFERENCES

- Shetty MR. Metastatic tumors of the umbilicus: a review 1830-1989. *J Surg Oncol* 1990;45:212-5.
- Edoute Y, Malberger E, Kuten A. Umbilical metastasis diagnosed by fine needle aspiration. *J Surg Oncol* 1990; 45:56-58.
- Barrow MV. Metastatic tumors of the umbilicus. *J Chron Dis* 1966; 19:1113-17.
- Bukovsky I, Lifshits Y, Langer R. Umbilical mass as a presenting symptom of endometrial adenocarcinoma. *Gynecol Obstet Invest* 1979;17:229-30.
- Shvili D, Halevy S, Sandbank M. Umbilical metastasis as the presenting sign of pancreatic adenocarcinoma. *Cutis* 1983;5:555-6.
- Charoenkul V, DelCampo A, Derby A, Hodgson WJ, McElhinney AJ. Tumors of the umbilicus. *Mt Sinai J Med* 1977;44:257-62.
- Scarpa FJ, Dineen JP, Boltax RS. Visceral neoplasia presenting at the umbilicus. *J Surg Oncol* 1979;11:351-9.
- Chatterjee SN, Bauer HM. Umbilical metastasis from carcinoma of the pancreas. *Arch Dermatol* 1980;166:954-5.
- Sharaki M, Abdel-Kadner M. Umbilical deposits from internal malignancy. *Clin Oncol* 1981;7:351-5.
- Heatley MK, Toner PG. Sister Mary Joseph's nodule: a study of the incidence of biopsied umbilical secondary tumors in a defined population. *Br J Surg* 1989;76:728-9.
- Foster MA, Gering SA, Bradley YC. Sister Mary Joseph's sign from metastatic disease of the pancreas. *J Am Coll Surg* 2001;192:130.
- Venu RP, Brown RD. Image of the month. Sister Mary Joseph's nodule: carcinoma of the pancreas with umbilical metastasis. *Gastroenterology* 1998; 114:632, 863.

13. Steck WD, Helwig EB. Tumors of umbilicus. *Cancer* 1965;18:907-15.
14. Powell FC, Cooper AJ, Massa MC, Goellner JR, Su WP. Sister Mary Joseph's nodule: A clinical and histologic study. *J Am Acad Dermatol* 1984;10:610-5.
15. Donatini B, Hidden G. Routes of lymphatic drainage from the pancreas: a suggested segmentation. *Surg Radiol Anat* 1992;14:35-42.
16. Khan AJ, Cook B. Metastatic carcinoma of umbilicus: "Sister Mary Joseph's nodule". *Cutis* 1997;60:297-8.
17. Chorost MI, McKinley B, Tschoi M, Ghosh BC. The management of unknown primary. *J Am Coll Surg* 2001;193:666-77.