

CASE REPORT

BILATERAL GIANT RENAL ANGIOMYOLIPOMA ASSOCIATED WITH HEPATIC LIPOMA IN A PATIENT WITH TUBEROUS SCLEROSIS

Edison Daniel Schneider-Monteiro, Antonio Marmo Lucon, André Avarese de Figueiredo, Aldo Junqueira Rodrigues Junior and Sami Arap

SCHNEIDER-MONTEIRO ED et al. - Bilateral giant renal angiomyolipoma associated with hepatic lipoma in a patient with tuberous sclerosis. *Rev. Hosp. Clín. Fac. Med. S. Paulo* 58(2):103-108, 2003.

OBJECTIVE: To report a case of bilateral giant renal angiomyolipoma associated with tuberous sclerosis, with successful treatment, and to review the literature concerning angiomyolipoma treatment.

CASE REPORT: Patient with tuberous sclerosis and angiomyolipoma diagnosed by ultrasonography during her pregnancy. At that time, the angiomyolipoma on the right side was 9 cm in diameter. Conservative management was selected during her pregnancy. The patient returned 7 years later, with a 24.7 x 19.2 x 10.7 cm tumor on the right side and another of 13 x 11.5 x 6.5 cm on the left side, in addition to multiple small angiomyolipomas. A nephron-sparing surgery with tumoral enucleation was performed on the right side, and after 3 months, the tumor on the left side was removed. Renal function in the post-operative period was preserved, and contrast medium progression was uniform and adequate in both kidneys.

CONCLUSION: We conclude that an angiomyolipoma larger than 4 cm should be removed surgically, since they have a greater growth rate and pose a risk of hemorrhage. Resection of smaller tumors is safe and has decreased morbidity. Tumoral enucleation is an effective treatment method that preserves kidney function.

DESCRIPTORS: Angiomyolipoma. Tuberous sclerosis. Hepatic lipoma. Nephron-sparing surgery. Therapeutic.

INTRODUCTION

Renal angiomyolipoma is a benign tumor comprised of 3 different types of tissue: fatty, smooth muscle, and vascular. It is estimated to occur in 0.3% of the population and comprises 3% of the solid renal masses^{1,2}. It affects 2 distinctive populations: the bearers and the non-bearers of tuberous sclerosis. Tuberous sclerosis is a dominant autosomal congenital disease, having an estimated frequency in the western society of 1:10.000. It results from alterations in the 9q34 or 16p13.3 chromosome and is normally characterized by a classic triad of men-

tal retardation, epilepsy, and sebaceous adenomas³⁻⁵. Angiomyolipoma associated with tuberous sclerosis occurs with greatest frequency between the second and third decade while in its isolated form. It primarily affects women between the fourth and seventh decade of life⁶. The most common signs and symptoms are abdominal pain, palpable abdominal mass,

hematuria and other consequences of intra-tumoral hemorrhage⁷. The latter occurs in approximate 25% of the patients; in 10% of them, it can lead to hypovolemic shock when in the acute phase^{8,9}. The symptoms and complications of angiomyolipoma are related to its size and rapidity of growth. Lesions greater than 4 cm in size indicate a greater risk of complication, such as hemorrhage. According to the literature, management depends on its size, which indicates the best treatment to be given¹⁰.

Fifty-four cases of giant renal angiomyolipoma were found to be reported in the literature, with only 11

From the Disciplines of General Surgery and Urology, Surgery Department, Hospital das Clínicas, Faculty of Medicine, University of São Paulo.

Received for publication on
February 25, 2002.

of them being larger than that in the present case. We have found only 1 case of similar association of renal angiomyolipoma, tuberous sclerosis, and hepatic lipoma¹¹. We undertook this bibliographic research using the PUBMED database and the following keywords: renal angiomyolipoma and tuberous sclerosis, giant renal angiomyolipoma, renal angiomyolipoma, tuberous sclerosis and lipoma, angiomyolipoma, and hepatic lipoma. We present 1 case of giant (> 12 cm) bilateral renal angiomyolipoma associated with hepatic lipoma that was diagnosed in a pregnant woman with tuberous sclerosis.

CASE REPORT

A female patient, 34 years old, who had bearded tuberous sclerosis and had experienced convulsive crises since she was 8 years old, presented during pregnancy (20 weeks) reporting left lumbar pain. On physical examination, she presented no abnormalities, but the abdominal sonography showed a renal mass of 9 cm diameter on the right. Magnetic resonance imaging confirmed the presence of a tumor of the dimensions given above in her right kidney, suggesting a diagnosis of renal angiomyolipoma. It was decided to leave her under observation during pregnancy and to resolve the case after delivery. The patient did not return for follow up after the birth, but came back, asymptomatic, to the clinic 7 years later, reporting that 3 months previously, a right abdominal mass of large proportions had been discovered during a physical exam. She also said she had lost 8 kg during the 3 months. She denied any family history of tuberous sclerosis. We observed around the nose multiple sebaceous adenomas and warts under the toe nails. Hypochromic patches (café-au lait) were noted on her trunk, and a mass was

present on her right flank. On physical examination, there was a hepatomegaly, and the tumoral mass was palpable in the right flank and iliac region, extending to the mesogastrium and going beyond the midline; it had a smooth surface of solid consistence, of low mobility, and clear limits.

Abdominal sonography showed a solid mass of 24.7 x 19.2 x 10.7 cm in size and of 2638 cm³ in volume, though it was impossible to identify its origin. Computed tomography showed topical kidneys with non-specific hypoattenuated cortical nodular images of less than 1 cm, possibly corresponding to cysts or angiomyolipoma as well as hypo-attenuant solid nodules with very high fat content. Some of the tumors of considerable size with evident blood vessels in the interiors were pushing the intestine forward. The largest at the lower pole of the right kidney measured 20 x 15 x 16 cm extending as far as the pelvic region (Fig. 1). The presence of hepatic lipoma was also demonstrated; there were 3 rounded hypoattenuated images in the right lobe, less than 1 cm in size, which could represent small cysts or lipomas. Further, there was another hypoattenuated, cleared, delimit-

ated nodule of fat density in segment III.

Kidney function was normal, and the urine analyses showed discrete proteinuria (0.34 g/24h). Radionuclide renography with DMSA showed bilateral depressed renal tubular function, primarily in the right kidney, signs suggestive of sequels of pyelonephritis of the left kidney and bilateral dilatation of the collecting system.

The patient underwent medial longitudinal laparotomy and enucleation of the tumors of the right kidney, preserving the renal tissue as much as possible. The largest tumor in the inferior pole and small tumoral masses were withdrawn, weighing altogether 2020 g and measuring 23.0 x 21.0 x 11.5 cm. There was no intention of completely withdrawing all small intrarenal tumors, because this might damage the renal function. A further hepatic lipoma in segment III of 1.5 cm was removed. The pathology examination revealed angiomyolipoma with predominance of fat component and hepatic lipoma. The renal tumor reacted positively to HMB-45, an important angiomyolipoma marker, but the hepatic lipoma didn't. After 3 months, the patient underwent another opera-

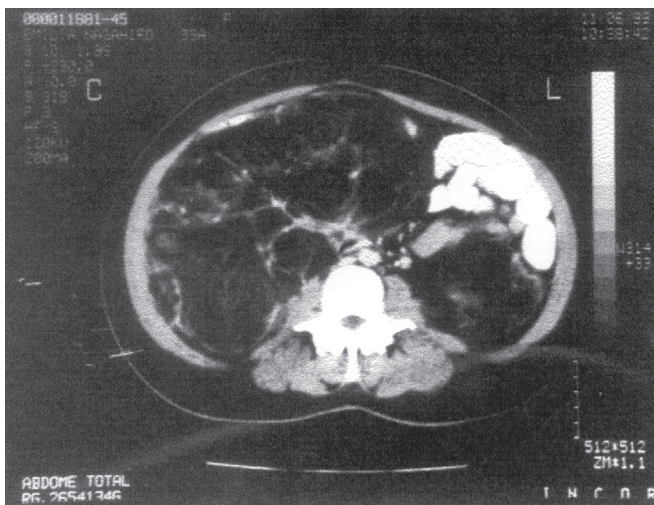


Figure 1 - Computed tomography before surgery: A giant angiomyolipoma (23 x 21 x 11.5 cm) in the right kidney and another (13 x 9.5 x 5.5 cm) in the left kidney.

tion for the enucleation of the tumors on the left kidney, the technique being repeated and the renal tissue preserved. The various irregular tumor fragments weighed a total of 475 g and the largest of the fragments measured 13.0 x 9.5 x 5.5 cm.

After surgery, renal function maintained normal. Computed tomography revealed good renal function and multiple small solid nodules on both kidneys. After 2 years, computed tomography was repeated and revealed preserved renal function and nodules of the same size of the last exam (Fig. 2).

DISCUSSION

Tuberous sclerosis is a dominant autosomal congenital disease that is characterized clinically by the classical triad of mental retardation, epilepsy, and sebaceous adenoma¹². Characteristically, tuberous sclerosis occurs in the brain, where whitish nodules are found in the distorted cortical cytoarchitecture, with deformed, bizarre neurons that are frequently enlarged. Re-

nal angiomyolipomas, cardiac rhabdomyomas, and pancreatic cysts may be associated with the tuberous sclerosis¹³. From 40% to 80% of the bearers of tuberous sclerosis present with renal angiomyolipoma with multiple bilateral asymptomatic tumors, which may be associated with cysts and more rarely renal carcinoma^{6,12}. In those patients with angiomyolipoma without tuberous sclerosis, the tumor is generally single, larger, and asymptomatic^{6,8,14}. The angiomyolipoma may affect the perirenal fat and local lymphatic vessels, and the presence of tumors in extra renal sites is considered multicentric and not metastatic. Angiomyolipoma may occur in the lungs, liver, Fallopian tubes, vagina, spermatic cord, penis, or nasal cavities¹⁴. The association of angiomyolipoma and hepatic lipoma is rarely observed in patients with tuberous sclerosis¹¹.

Although angiomyolipoma is comprised of 3 distinct groups of tissue, pleomorphism and aneuploid mitotic figures may occur in some cases. Electronic microscopy not infre-

quently reveals muscular cells with lipid content as if simulating a cell intermediate between smooth muscular and fat cell. These findings corroborate the hypothesis that the different types of tissue originate from one stem cell¹⁵. Because of the presence of multinucleated giant cells, it may be difficult to distinguish the tumor from liposarcoma, malignant fibrous histiocytoma, leiomyosarcoma, or sarcomatoid carcinoma. This difficulty emphasizes the importance of HMB-45 immunoreaction, because a monoclonal antibody reacts specifically with premelanosomes in the smooth muscle cells. No other benign or malignant renal tumors show staining with HMB-45. This confirmation is important for the correct definition of the nature of the tumor and the most appropriate procedures for the patient^{16,17}.

The natural history of angiomyolipoma is not fully known; however, some authors have presented some important observations. Steiner and colleagues studied 35 patients with a total of 48 lesions, 34 of which were followed clinically for 4 years. Of these, 64% presented no change during follow up, and it was found that tumors initially larger than 4 cm were more prone to growth. No metachromic lesions or renal carcinoma were observed in this group of patients. It was further noticed that growth of tumors did not seem to be due to intra-tumoral bleeding, but rather arose as a result of the growth of its tissue. The growth may be slow or rapid, there being no specific fact known to account for this rate of growth¹⁸. Ewalt and colleagues studied the growth of renal lesions in children suffering from tuberous sclerosis and observed that the majority of the lesions were angiomyolipoma and had the tendency to grow; they did not observe any case of regression among these tumors, in contrast with what occurs with renal cysts. The largest

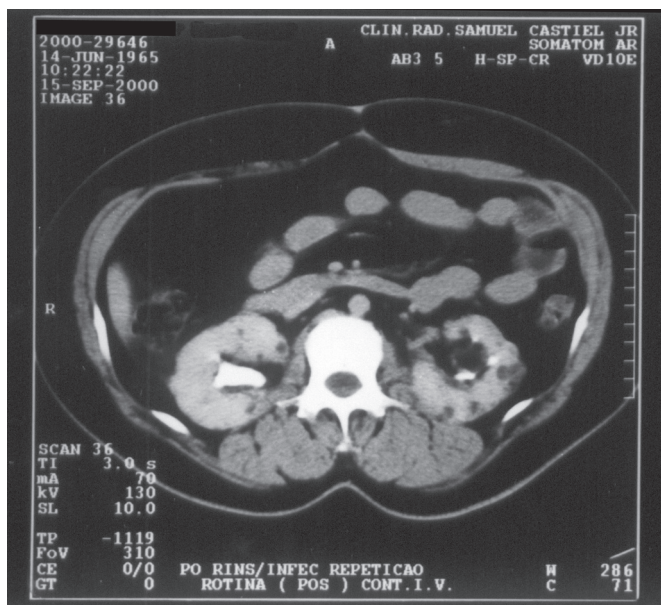


Figure 2 - Computed tomography 2 years after surgery: Only small intra-parenchymatous angiomyolipomas less than 1 cm are present in both kidneys, and good kidney preservation is apparent.

growth observed in the 60 patients was 4 cm in 1 year (0 to 4cm and in one other case from 5 to 9 cm). The youngest patient with angiomyolipoma was 2 years old. It was further observed that the growth of various lesions in the same kidney proceeded at different rates, the number of lesions and their rate of growth being progressive and dependent of age. It was suggested that the loss of the function of the tumor suppressive gene owing to a second mutation may explain why some tumors grow while others maintain stable. The hormonal influences of the steroid receptors in the muscle cells may explain the differences in tumor behavior seen during different periods of life, with greater tumor growth in post-puberal period and during pregnancy¹². Other studies add further that angiomyolipoma in patients with tuberous sclerosis grow over time, that tumors greater than 4 cm generally occur post-puberty¹⁹, and that angiomyolipoma has greater likelihood of growing in women than in men because according to hormonal theory, there are progesterone receptors in the muscle cells of the tumor²⁰. In the literature, there was one report of 6 cases of association of pregnancy and angiomyolipoma with acute bleeding, including 2 cases of acute rupture calling for nephrectomy²¹. What may be regarded as certain in the natural history of the disease is the relationship between size and risk of complications, with tumors having diameters greater than 4 cm having the greatest risk of rupture.

As for clinical manifestations, the main symptom is abdominal pain, more specifically lumbar pain. Other possible symptoms and signs are palpable mass, hemorrhage, hematuria, nausea and vomiting, systemic arterial hypertension, anemia, fever, shock, renal failure and urinary infection¹⁸. In those patients with lesions smaller than 4 cm the diagnosis is in the ma-

ajority of cases fortuitous during a physical exam. The symptoms are more frequent in patients with larger tumors²²; about 25% of patients with angiomyolipoma present with intense abdominal pain or with shock due to intra-tumoral hemorrhage and undergo emergency nephrectomy⁸.

At the present time, diagnosis is made based on abdominal sonography and computed tomography, by which the presence of fat cells in the composition of the tumor is discovered. This finding is confirmed in the computed tomography by means of the measurement of image density that should be less than or equal to - 50 Hounsfield. Doubt concerning diagnosis persists in those cases in which there is little fat content or in the presence of previous bleeding, which may conceal the presence of fat cells in the tumor^{6,10,23}.

The treatment has been fully discussed in the literature. The decision regarding treatment methodology is made primarily based on of the size of the angiomyolipoma, the symptoms, the rate of growth, complications, and the degree of diagnostic certainty regarding radiological results. Prior to 1976, 93% of all angiomyolipoma that were unrelated to tuberous sclerosis were treated by total nephrectomy. More recently, on the basis of sonography and computed tomography, which have created the possibility of diagnostic certainty, the objective in the majority of the cases and as far as possible is conservative treatment. Selective arterial embolization has shown itself effective in the treatment of acute hemorrhage with or without later surgery or as initial treatment of the angiomyolipoma^{8,10}. Although arterial embolization is minimally invasive, it does not preserve renal function; it only has a temporary effect; it requires close clinical observation because of associated complications; and as a rule, it is inefficient when used alone. Regarding surgical treatment,

tumorectomy, partial nephrectomy, or total nephrectomy may be carried out. The surgical treatment that preserves the largest amount of renal tissue is tumor enucleation, which has been undertaken with excellent results, even for giant angiomyolipoma (larger than 20 cm), being practically applicable to patients with tuberous sclerosis who present multiple and bilateral lesions^{10,24,25}. Total nephrectomy should be used very rarely; it is only justified in cases of uncontrollable bleeding, when there is risk to the patient's life, in central tumors, in the presence of extensive necrosis or when there is inflammation of the renal tissue, or when there is a diagnosis of renal carcinoma in the same kidney. This last scenario is debatable in the light of recent proposals for surgery for renal carcinoma with preservation of renal tissue^{5,23,26}. More recently, cryotherapy has been suggested as a therapeutic option and may be associated with laparoscopy²⁷.

The primary objective of treatment of angiomyolipoma is the preservation of renal function, principally in those cases in which it is associated with tuberous sclerosis, in which the lesions are generally larger, multiple, bilateral, and recurring. Among therapeutic options, tumor enucleation makes greater preservation of the renal tissue possible, followed by selective arterial embolization and cryotherapy. Embolization primarily controls the bleeding in the acute phase, but may lead to greater loss of the renal function. Cryotherapy is still an undergoing assessment, and additional clinical studies need to be undertaken to evaluate its real effectiveness in preserving the renal function. Oesterling and colleagues define an algorithm for treatment based on symptoms and the size of the angiomyolipoma; they proposed follow up, selective embolization, or surgical treatment, depending on the case. Surgery should be conservative whenever possible so that

maximal preservation of renal tissue (enucleation or partial nephrectomy) is achieved¹⁰.

Steiner and colleagues have proposed changes in Oesterling's algorithm, thus differentiating the treatment for patients with tuberous sclerosis (Fig. 3)¹⁸. This differentiation seems to be preferable to prevent the tumor from attaining larger dimensions, especially with cases associated with tuberous sclerosis in which con-

servative surgery is more difficult and causes greater losses of blood due to the size of the tumor.

In conclusion, the basis of management of angiomyolipoma is the attempted preservation of renal tissue, which can be effectively achieved with nephron-sparing surgical procedures such as tumor enucleation. Under some conditions, however, it is necessary to do selective angioembolization, partial nephrectomy, or even total ne-

phrectomy. Especially in patients with tuberous sclerosis with large bilateral and multiple tumors, the aim of treatment is the preservation of the greatest possible degree of efficient renal function. Therefore, tumoral enucleation is one of the best choices in these cases and is perfectly feasible. Smaller tumors can be excised and submitted to experimental studies using laparoscopy or cryotherapy.

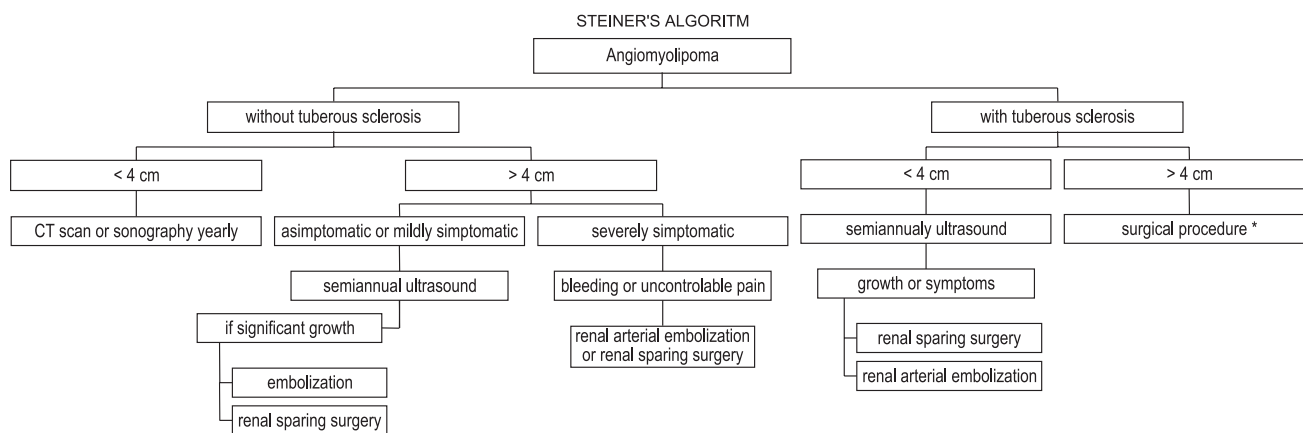


Figure 3. Steiner's algorithm¹⁸.

*Consider immediate prophylactic renal arterial embolization or renal sparing surgery.

RESUMO

SCHNEIDER-MONTEIRO ED e col. – Angiomiolipomas renais gigantes bilateralmente associados a lipoma hepático em pacientes com esclerose tuberosa. *Rev. Hosp. Clín. Fac. Med. S. Paulo* 58(2):103-108, 2003.

OBJETIVO: Relatar um caso de angiomiolipoma gigante, bilateral, associado a esclerose tuberosa, tratado com sucesso e revisar a literatura concernente ao tratamento do angiomiolipoma.

RELATO DO CASO: Paciente portadora de esclerose tuberosa, com

diagnóstico de angiomiolipoma realizado por ultra-sonografia durante gestação. O tumor apresentava 9cm de diâmetro, à direita. Optou-se por conduta conservadora durante a gestação, e a paciente retornou somente 7 anos após, com tumor de 24,7 x 19,2 x 10,7 cm à direita e outro à esquerda de 13 x 11,5 x 6,5 cm, além de múltiplos angiomiolipomas pequenos. Realizada inicialmente ressecção tumoral à direita, por enucleação, com preservação do parênquima renal, e 3 meses após à esquerda. A função renal pós-operatória se manteve inalterada, e ambos os rins apresentaram uniformidade e pro-

gressão do contraste adequados.

CONCLUSÃO: Concluímos que os angiomiolipomas maiores que 4cm devem ser tratados cirurgicamente porque têm maior risco de crescimento e hemorragias. As ressecções de tumores menores são mais seguras e têm menor morbidade. A enucleação dos tumores é forma eficaz de ressecção dos mesmos, com preservação de parênquima renal.

DESCRITORES: Angiomiolipoma. Esclerose tuberosa. Lipoma hepático. Enucleação tumoral. Terapêutica.

REFERENCES

1. HADJU SI, FOOTE Jr. F W - Angiomyolipoma of the kidney: report of 27 cases and review of the literature. **J Urol** 1969; **102**:396-401.
2. MAZEMAN E, WEMEAU L, BISERTE J *et al.* - Renal angiomyolipoma. A report of 11 cases. **Eur Urol** 1980; **6**:328-34.
3. WIEDERHOLT WC, GOMEZ MR, KURLAND LT - Incidence and prevalence of tuberous sclerosis in Rochester, Minnesota, 1950 through 1982. **Neurology** 1985; **35**:600-603.
4. LINDENBAUM R - Prevalence of tuberous sclerosis. In: TUBEROUS SCLEROSIS SYMPOSIUM, 2nd, Nottingham, United Kingdom, 1985.
5. FAZELI-MATIN S, NOVICK AC - Nephron-sparing surgery for renal angiomyolipoma. **Urology** 1998; **52**(4):577-83.
6. VAN BAAL JG, SMITS NJ, KEEMAN JN *et al.* - The evolution of renal angiomyolipoma in patients with Tuberous Sclerosis. **J Urol** 1994; **152**:35-38.
7. O'DONNELL M, FLEMING S - Angiomyolipoma of the kidney - a cause of recurrent retroperitoneal haemorrhage. **BJU** 1995; **76**:512-24.
8. TONGAONKAR HB, SAMPAT MB, DALAL AV *et al.* - Bilateral renal angiomyolipoma. **J S Oncology** 1994; **57**:65-70.
9. BOSNIAK MA - Angiomyolipoma (hamartoma) of the kidney: a preoperative diagnosis is possible in virtually every case. **Urol Rad** 1981; **3**:135-42.
10. OESTERLING JE, FISHMAN EK, GOLDMAN SM *et al.* - The management of Renal Angiomyolipoma. **J Urol** 1986; **135**:1121-24.
11. HIRASAKI S, KOIDE N, OGAWA H *et al.* - Tuberous sclerosis associated with multiple hepatic lipomatous tumors and hemorrhagic renal angiomyolipoma. **Intern Med** 1999; **38**(4):345-48.
12. EWALT DH, SHEFFIELD E, SPARAGANA SP *et al.* - Renal lesion growth in children with tuberous sclerosis complex. **J Urol** 1998; **160**:141-145.
13. GIROLAMI U, FROSCH MP, ANTHONY DC - The central nervous system. In: COTRAN RS, ROBBINS SL, KUMAR VY - **Pathologic basis of disease**. 5th ed. Philadelphia, Pennsylvania, Saunders, 1994. c. 29, p. 1354
14. DE LUCA S, TERRONE C, ROSSETTI R - Management of renal angiomyolipoma: a report of 53 cases. **BJU international** 1999; **83**:215-18.
15. HOLM-NIELSEN P, SORENSEN FB - Renal angiomyolipoma: an ultrastructural investigation of three cases with histogenetic considerations. **APMIS** 1988; suppl, **4**:37-47.
16. PEA M, BONETTI F, ZAMBONI G *et al.* - Melanocyte-marker HMB-45 is regularly expressed in angiomyolipoma of the kidney. **Pathology** 1991; **23**:185-188.
17. KAISERLING E, KRÖBER S, XIAO JC, SCHAUMBURG-LEVER G - Angiomyolipoma of the kidney. Immunoreactivity with HMB-45. Light and electron-microscopic findings. **Histopathology** 1994; **25**:41-48.
18. STEINER MS, GOLDMAN SM, FISHMAN EK *et al.* - The natural history of renal angiomyolipoma. **J Urol** 1993; **150**:1782-86.
19. STILLWELL TJ, GOMEZ MR, KELALIS PP - Renal lesion in tuberous sclerosis. **J Urol** 1987; **138**:477-81.
20. MARTIGNONI G, PEA M, BONETTI F - Progesterone receptors in renal angiomyolipoma. In: TUBEROUS SCLEROSIS ASSOCIATION OF GREAT BRITAIN. Bath, United Kingdom, 1995. **An Meeting** Bath, United Kingdom, 1995.
21. JARDIN A, RICHARD F, LEDUC A *et al.* - Diagnosis and treatment of renal angiomyolipoma (based on 15 cases). Arguments in favor of conservative surgery (based on 8 cases). **Eur Urol** 1980; **6**:69-82.
22. KATZ DS, POSTER RB - Massive renal angiomyolipoma in tuberous sclerosis. **Clinical Imaging** 1997; **21**:200-202.
23. CHATTERJEE T, HEINDEL W, VORREUTHER R *et al.* - Recurrent bleeding of angiomyolipoma in tuberous sclerosis. **Urol Int** 1996; **56**:44-47.
24. CHEN CH, YU TJ, HSU K - Unusual presentations of angiomyolipoma. **Changeng Yi Xue Za Zhi** 1991; **14**:269-72.
25. MEIRI H, SOEJIMA K, TOKUDA Y *et al.* - The management selection of renal angiomyolipoma. **Nippon Hinyokika Gakkai Zasshi** 1996; **87**:1197-200
26. LICHT MR, NOVICK AC - Nephron sparing surgery for renal cell carcinoma. **J Urol** 1993; **149**:1-7.
27. DELWORTH MG, PISTERS LL, FORNAGE BD *et al.* - Cryotherapy for renal cell carcinoma and angiomyolipoma. **J Urol** 1996; **155**:252-55.