

CASE REPORT

ELIMINATION OF BILIARY STONES THROUGH THE URINARY TRACT: A COMPLICATION OF THE LAPAROSCOPIC CHOLECYSTECTOMY

Maurício Gustavo Bravim de Castro, Antônio Sérgio Alves, Cláudio Almeida de Oliveira, Álvaro Vieira Júnior, José Luiz Campello de Mello Vianna and Renato Freitas Carvalho Costa

RHCFAP/2993

CASTRO, MGB de et al. - Elimination of biliary stones through the urinary tract: a complication of the laparoscopic cholecystectomy. *Rev. Hosp. Clín. Med. S. Paulo* 54 (6):209-212, 1999.

SUMMARY: The introduction and popularization of laparoscopic cholecystectomy has been accompanied with a considerable increase in perforation of gallbladder during this procedure (10%–32%), with the occurrence of intraperitoneal bile spillage and the consequent increase in the incidence of lost gallstones (0.2%–20%). Recently the complications associated with these stones have been documented in the literature. We report a rare complication occurring in an 81-year-old woman who underwent laparoscopic cholecystectomy and developed cutaneous fistula to the umbilicus and elimination of biliary stones through the urinary tract. During the cholecystectomy, the gall bladder was perforated, and bile and gallstones were spilled into the peritoneal cavity. Two months after the initial procedure there was exteriorization of fistula through the umbilicus, with intermittent elimination of biliary stones. After eleven months, acute urinary retention occurred due to biliary stones in the bladder, which were removed by cystoscopy. We conclude that efforts should be concentrated on avoiding the spillage of stones during the surgery, and that no rules exist for indicating a laparotomy simply to retrieve these lost gallstones.

DESCRIPTORS: Laparoscopic Cholecystectomy. Complications. Lost gallstone. Urinary tract. Urethra.

Laparoscopic cholecystectomy is a safe and effective procedure for the treatment of the cholecystolithiasis. Cholecystectomy via laparoscopy is the standard access because of the diminished postoperative pain, shorter hospital stay, and shorter absence from work, with morbidity comparable to the conventional surgery or through minilaparotomy¹.

With the popularization of the laparoscopic cholecystectomy, there has been a considerable increase in the number of perforations of the gallbladder (10%–32%), resulting in intraperitoneal gallstone spillage. This spillage has caused an increase in the incidence of lost gallstones, which is estimated to occur in 0.2 to 20% of the procedures²⁻⁴. Recently some complications associated with these stones have been

reported. In this article, the authors relate one of these complications, which has not been described in the current literature.

CASE REPORT

A woman aged 81 years underwent laparoscopic cholecystectomy for symptomatic cholecystolithiasis at another institution in February 1992. At that occasion, she was informed about the occurrence of perforation of the gallbladder with intra-abdominal gallstone spillage.

From the Division of General Surgery, Felício Rocho Hospital, Belo Horizonte - Brazil.

In March 1992, the patient was seen with serohemorrhagic drainage through the umbilicus, developing with cutaneous fistula and intermittent elimination of gallstones.

The patient was suffering from recurrent infection of the urinary tract and was followed by the urologic clinic. Eleven months after the initial procedure, she presented an episode of urinary retention, followed by the elimination of stones through the urethra. The cystoscopy showed a very hyperemic bladder (chronic cystitis) and an ulcerated lesion in the posterior wall with black and faceted stones, which were removed and sent to laboratory analysis. Laboratory tests verified the biliary origin of the stones (mixed gallstones). Urinary cultures grew *Klebsiella sp.* and *E. coli*.

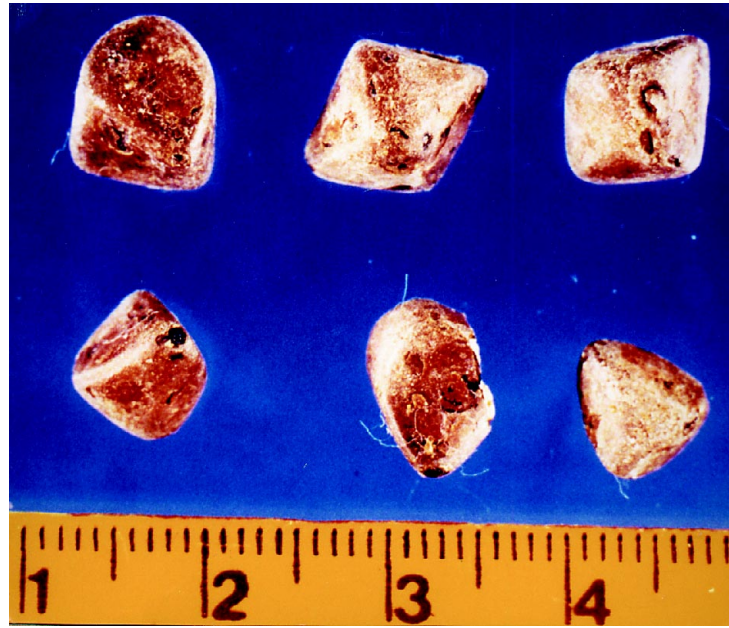


Figure 1 – Biliary stones eliminated through the umbilicus (sample provided by the patient).

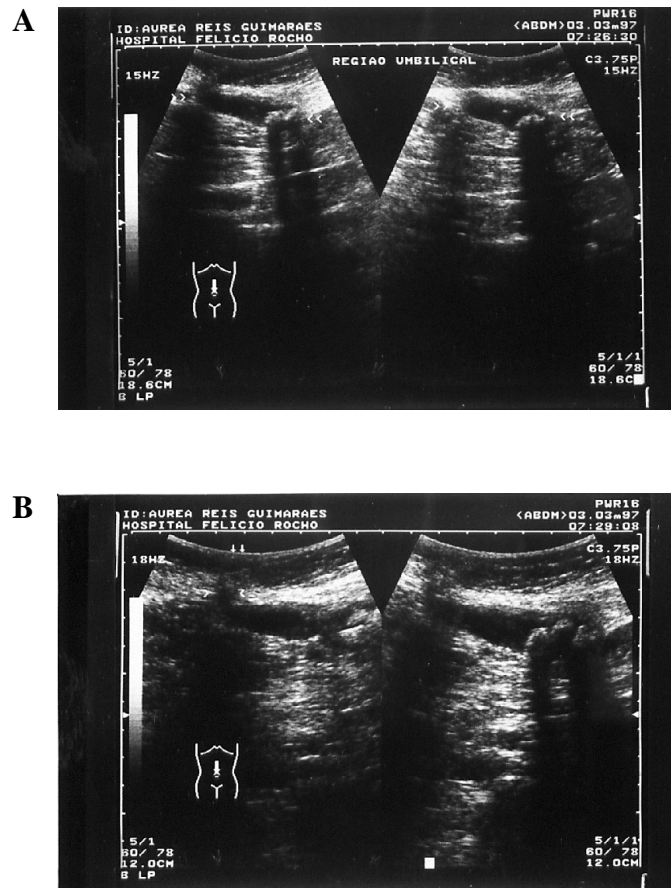


Figure 2 – Ultrasonography showing stones at the umbilical region (A) and a fistulous stretch to the abdominal wall (arrows) (B).

The patient progressed with intermittent elimination of biliary stones through the umbilicus during 5 years.

In February 1997, she was referred to our department. There was no fever, and no digestive or urinary symptoms. A new cystoscopy was performed, which showed a bladder with normal mucosa, a small dark point in the posterior wall, and absence of stones. Abdominal ultrasonography showed a 6.5 x 1.8 cm saccular image with a fistulous stretch to the umbilical region (Fig 2), presenting fluid collection and echogenic material.

In April 1997, the patient underwent a 4 cm transumbilical laparotomy under local anesthesia, with the drainage of viscid pus, from which *E. coli* was cultured. Eight biliary stones were also removed. Under appropriate antibiotic treatment, the recovery of the patient was uneventful, and there was complete cicatrization of the wound.

DISCUSSION

Bile is a sterile fluid. In aged patients, however, there is a high possi-

bility of colonization of the gallbladder. Additionally, up to 92% of pigmented stones can harbor bacterial microcolonies. These facts can explain the occurrence of postoperative infections in patients whose gallbladders were perforated during the procedure. The case reported is relative to an old woman with chronic cholecystopathy and mixed gallstones, who developed an intra-abdominal abscess with cutaneous fistula and eliminated biliary stones through the urinary tract after laparoscopic cholecystectomy, which was documented by cystoscopy and laboratory analysis of the stones.

Recently, Läufer et al.⁴ published a review of 22 cases of clinical manifestations of lost gallstones after laparoscopic cholecystectomy including many macroabscesses in different localizations, granulomas, fistulas, bowel obstruction, cholelithoptysis and cholelithorrhea, and migration of stones into the femoral canal, pelvis, and ovary. Previously, there had been no report about the elimination of biliary stones through the urinary tract as a late complication of the laparoscopic cholecystectomy.

With the information available in the current literature, it seems to be convenient to consider the possibility of late postoperative complications related to lost gallstones in the abdominal cavity. Thus, we recommend avoiding these complications by using an accurate surgical technique with adequate materials, including the use of the endobag when it is necessary, especially in cases of chronic cholecystitis, gallbladder with thin walls, and when there is evidence of multiple stones. Despite the high frequency of intra-abdominal loss of biliary stones during the laparoscopic cholecystectomy, the complications related to these stones are rare if we consider the number of procedures performed in the world. Thus, it becomes difficult to establish rules for indicating a laparotomy to retrieve the lost gallstones. Consequently, we think that after bile and gallstones leakage, retrieval of as many spilled stones as possible should be attempted laparoscopically, followed by an exhaustive irrigation of the abdominal cavity.

RESUMO

RHCFAP/2993

CASTRO MGB e col. - Eliminação de cálculos biliares pela via urinária: uma complicação da colecistectomia laparoscópica. **Rev. Hosp. Clín. Fac. Med. S. Paulo** 54 (6): 209-212, 1999.

Com a introdução e popularização da colecistectomia por via laparoscópica houve um aumento considerável na taxa de perfuração da vesícula biliar durante o procedimento, determi-

nando o derramamento de bile na cavidade peritoneal e consequente aumento da incidência de cálculos biliares perdidos na cavidade. Recentemente, as complicações associadas com estes cálculos vêm sendo estabelecidas na literatura. Os autores relatam uma complicação rara ocorrida em uma paciente de 81 anos que foi submetida à colecistectomia laparoscópica e apresentou no pós-operatório uma fístula cutânea para a cicatriz umbilical e eli-

minação de cálculos biliares pelo trato urinário. Concluímos que é importante evitar o derramamento de cálculos durante a cirurgia, porém a laparotomia não deve ser indicada simplesmente para retirada de cálculos perdidos durante a colecistectomia laparoscópica.

DESCRITORES: Colecistectomia laparoscópica. Complicações. Cálculos perdidos. Trato urinário. Uretra.

REFERENCES

1. ALVES AS, LÁZARO DA SILVA A, OLIVEIRA CA et al. - Open cholecystectomy, cholecystectomy via minilaparotomy and laparoscopic cholecystectomy: a comparative analysis of 300. **Rev. Col Bras Cir** 1997; **24**:143-146.
2. SOPER NJ & DUNNEGAN DL - Does intraoperative gallbladder perforation influence the early outcome of laparoscopic cholecystectomy? **Endoscopy** 1991;**1**:156-161.
3. FITZGIBONS RJ, ANNIBALIM R & LITKE BS - Gallbladder and gallstone removal, open versus closed laparoscopic, and pneumoperitoneum. **Am J Surg**. 1993; **165**:497-504.
4. LÄUFFER JM, KRÄHENBÜHL L, BAER HU et al. - Clinical manifestations of lost gallstones after laparoscopic cholecystectomy: a case report with review of literature. **Surg Laparosc Endosc**. 1997; **7**:103-112.
5. LÜTKEN W, BERGGREN P & MALTBAEK J - Passing of gallstones via the urethra: a complication of laparoscopic cholecystectomy. **Surg Laparosc Endosc**. 1997; **7**:495-497.

Received for publication on the 31/05/99