

doi: <http://dx.doi.org/10.11606/issn.1679-9836.v96i2p131-133>

## High levels of transaminases in a choledocholithiasis case: the importance of knowing this pattern

### Níveis elevados de transaminases em um caso de coledocolitíase: a importância do reconhecimento deste padrão

João Victor Vecchi Ferri<sup>1</sup>, João Peron Moreira Dias da Silva<sup>2</sup>, Umberto de Oliveira Filho<sup>3</sup>,  
José Augusto Froner Bicca<sup>4</sup>, Daniel Brito de Araujo<sup>5</sup>

Ferri JVV, Silva JPMD, Oliveira Filho U, Bicca JAF, Araujo DB. High levels of transaminases in a choledocholithiasis case: the importance of knowing this pattern / *Níveis elevados de transaminases em um caso de coledocolitíase: a importância do reconhecimento deste padrão*. Rev Med (São Paulo). 2017 abr.-jun.;96(2):131-3.

**ABSTRACT:** Case report of a 34-year-old healthy woman diagnosed with symptomatic choledocholithiasis associated with elevated results of transaminases without hepatic disease. High levels of these enzymes can occur in choledocholithiasis cases without further causes of liver injury. Clinicians must be aware of this phenomenon, avoiding unnecessary investigation and its consequences.

**Keywords:** Choledocholithiasis; Transaminases; Women.

**RESUMO:** Relato de caso de uma mulher hígida de 34 anos de idade diagnosticada com coledocolitíase sintomática associada a elevados níveis de transaminases, sem doença hepática. Altos valores destas enzimas podem ocorrer na coledocolitíase sem outra causa de lesão hepática concomitante. Os médicos devem estar atentos a este fenômeno, a fim de se evitar investigação desnecessária e suas consequências.

**Descritores:** Coledocolitíase; Transaminases; Mulheres.

#### CASE PRESENTATION

A 34-year-old caucasian woman was hospitalized due to abdominal pain, nausea, and jaundice. Laboratory exams showed elevated levels of alanine aminotransferase (670 U/L), aspartate aminotransferase (383 U/L), gamma glutamyl transferase (336 U/L),

and bilirubins (7.6 mg/dL). Pain started ten days prior to the admission, initially in the upper abdomen, with irradiation to the back. Owing to the similarity with an acute pancreatitis pain pattern, amylase and lipase were ordered, but resulted normal. The patient had negative

1. Resident of General Surgery at Hospital de Clínicas de Porto Alegre. E-mail: [jvvf17@gmail.com](mailto:jvvf17@gmail.com).

2. Resident of Internal Medicine at Hospital Escola of Federal University of Pelotas - UFPel. E-mail: [joaoperon@hotmail.com](mailto:joaoperon@hotmail.com).

3. Chief Professor of Rheumatology, Federal University of Pelotas - UFPel. E-mail: [umberto@ufpel.edu.br](mailto:umberto@ufpel.edu.br).

4. Assistant Professor of Internal Medicine, Federal University of Pelotas - UFPel.

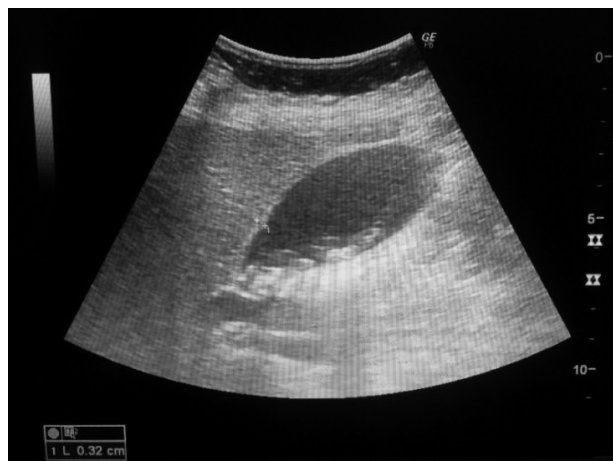5. Professor of Rheumatology, Federal University of Pelotas - UFPel. E-mail: [araujob@gmail.com](mailto:araujob@gmail.com).

**Correspondence:** João Victor Vecchi Ferri. Av. Mariland, 1445 - Ap. 202 - São João. Porto Alegre, RS. CEP: 90440-171. E-mail: [jvvf17@gmail.com](mailto:jvvf17@gmail.com)

history of hepatic diseases, risk factors for non-alcoholic steatohepatitis nor use of hepatotoxic medications that could explain such high levels of liver enzymes.

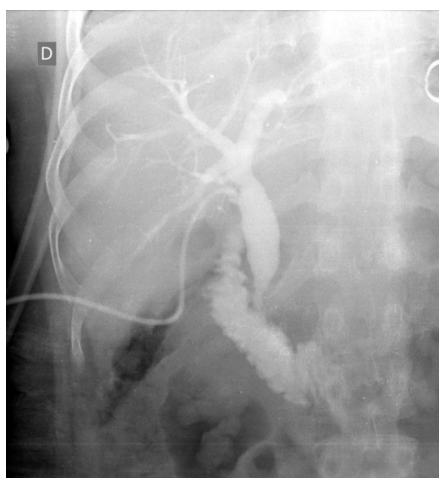
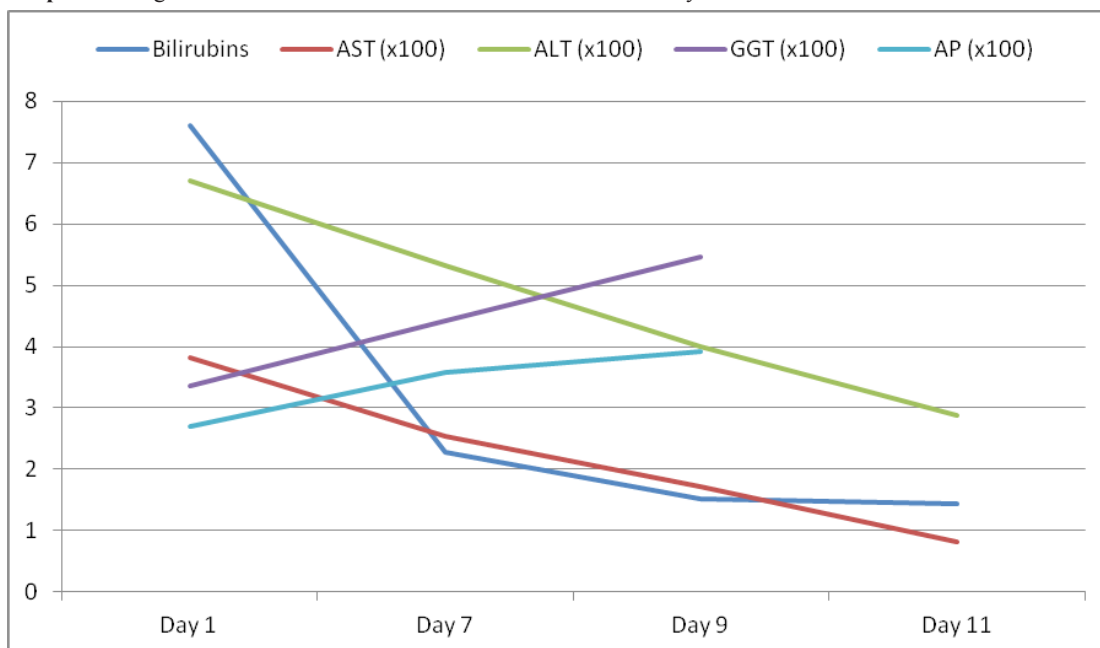
It was performed an abdominal ultrasound, which revealed multiple gallstones smaller than 10 mm and a choledochal dilatation of 11 mm, without any evidence of obstruction or liver morphologic changes (Figure 1).

During hospitalization, the patient had favorable evolution, with improvement of abdominal pain and jaundice, and progressive decrease of liver enzymes levels (Graphic 1). The patient underwent an open cholecystectomy with intraoperative cholangiography which did not show signs of obstruction (Figure 2), with hospital discharge in the day after surgery.



**Figure 1.** Multiples gallstones demonstrated by an abdominal ultrasound on patient's admission

**Graphic 1.** Progressive decrease of transaminases while canaliculi enzymes increase



**Figure 2.** Passage of contrast through the dilated common bile duct and duodenum with no signs of stones

## DISCUSSION

High levels of transaminases during a choledocholithiasis is not a common situation. Therefore, it isn't unusual that experienced physicians start an investigation for liver diseases such as viral or autoimmune hepatitis, and drug toxicity.

According to Mossberg and Ross<sup>1</sup>, there are three main mechanisms to explain the elevation of transaminases after a biliary obstruction: (1) regurgitation of transaminases from obstructive biliary canaliculi into hepatic sinusoids, (2) increased production and secretion of transaminases by liver cells following increased intrabiliary pressure, and (3) retention of bile acids leading to necrosis and/or apoptosis of hepatocytes. Spivey et al.<sup>2</sup> concluded that the bile salt-induced liver toxicity was due to mitochondrial

disfunction, resulting in depleted ATP levels and sustained influx of Ca<sup>2+</sup> leading to hepatocyte necrosis.

Although our patient had a high risk for choledocholithiasis based on the predictors of the American Society for Gastrointestinal Endoscopy, our service did not dispose of endoscopic retrograde cholangiopancreatography (ERCP), thus we performed an intraoperative cholangiography during cholecystectomy, which showed no residual calculi (Figure 2)<sup>3</sup>.

Transaminases are typically elevated early in the course of a biliary obstruction and, usually after the resolution of the obstructive process, their levels normalizes quickly<sup>4</sup>. Later, liver tests are elevated in a cholestatic pattern, with increases in serum bilirubin, alkaline phosphatase, and GGT, exceeding the elevations in ALT and AST serum levels. Improving liver blood tests combined with symptom resolution suggests that a patient with choledocholithiasis has spontaneously passed the gallstone, as occurred with our patient<sup>5</sup>.

A possible confounding factor was the use of ketoprofen by the patient in the emergency department, since there is the possibility of drug-induced hepatitis in less than 1% of the cases. However, the rapid decrease in transaminases levels, with normal liver function, substantially put away this diagnosis.

In a case series of four patients, Tetangco et al.<sup>6</sup> found high levels of transaminases in non-complicated

choledocholithiasis cases, with AST up to 1.134 U/L and ALT of 1.211 U/L, observing that it differs from hepatocellular disease by the rapid decline of transaminases levels after biliary opening, as occurred in our case.

Agahi and McNair<sup>7</sup>, in a case series of three patients with choledocholithiasis and ALT above 1.000 U/L, agreed that this pattern is virtually diagnostic of hepatocellular necrosis, but that it can occur in uncomplicated choledocholithiasis cases as well, although it is rarely recognized. Nathwari et al.<sup>8</sup>, in a more robust case series of eighteen patients with same features, concluded the same.

High levels of AST has been reported by Fortson et al.<sup>9</sup>, demonstrating levels greater than 600 U/L that fell rapidly in 24- to 72-hour period in cholelithiasis and choledocholithiasis cases. The highest levels were found in choledocholithiasis cases in whom the gallbladder had already been removed. An important conclusion was that a fall in AST levels did not necessarily mean that the stone had passed.

We concluded, as most of the other case series, that it is important that clinicians become aware of this underrecognized pattern, to avoid unnecessary investigation and, consequently, protect the patient from unnecessary invasive procedures, such as liver biopsy, as well as less complex tests, so costs can be reduced. It does not mean that in the proper context and high suspicious cases, additional investigation cannot be performed.

## REFERENCE

1. Mossberg SM, Ross G. High serum transaminases activity associated with extrahepatic biliary disease. *Gastroenterology*. 1963;45:345-53.
2. Spivey JR, Bronk SF, Gores GJ. Glycochenodeoxycholate-induced lethal cell injury in rat hepatocytes. *J Clin Invest*. 1993;92:17-24. doi: 10.1172/JCI116546.
3. ASGE Standard of Practice Committee, Maple JT, Ben-Menachem T, Anderson MA, Appalaneni V, Banerjee S, Cash BD, Fisher L, Harrison ME, Fanelli RD, Fukami N, Ikenberry SO, Jain R, Khan K, Krinsky ML, Strohmeyer L, Dominitz JA. The role of endoscopy in the evaluation of suspected choledocholithiasis. *Gastrointest Endosc*. 2010;71:1-9. doi: 10.1016/j.gie.2009.09.041.
4. Longo DL, Jameson JL, Loscalzo J, Hauser S, Fauci A, Kasper D. *Harrison's principles of internal medicine*. 18th ed. Columbus, OH: McGraw-Hill Professional; 2011.
5. Arain MA, Freeman ML. Choledocholithiasis: clinical manifestations, diagnosis, and management. *UpToDate* [cited 2016 Oct 30<sup>th</sup>]. Available from: <http://www.uptodate.com/contents/choledocholithiasis-clinical-manifestations-diagnosis-and-management>.
6. Tetangco EP, Shah N, Arshad HMS, Radawi H. Markedly elevated liver enzymes in choledocholithiasis in the absence of hepatocellular disease. *J Investig Med High Impact Case Rep*. 2016;18:4. doi: 10.1177/2324709616651092.
7. Agahi A, McNair A. Choledocholithiasis presenting with very high transaminase level. *BMJ Case Rep*. 2012. doi: 10.1136/bcr-2012-007268.
8. Nathwani RA, Kumar SR, Reynolds TB, Kaplowitz N. Marked elevation in serum transaminases: an atypical presentation of choledocholithiasis. *Am J Gastroenterol*. 2005;100(2):295-8. doi: 10.1111/j.1572-0241.2005.40793.x.
9. Fortson WC, Tedesco FJ, Starnes EC, Shaw CT. Marked elevation of serum transaminase activity associated with extrahepatic biliary tract disease. *J Clin Gastroenterol*. 1985;7(6):502-5.

Recebido em: 14.12.16

Aceito em: 10.04.17