

## Death from pan-resistant superbug

Larry Nichols<sup>a</sup> 

**How to cite:** Nichols L. Death from pan-resistant superbug. *Autops Case Rep* [Internet]. 2019 Jul-Sep;9(3):e2019106. <https://doi.org/10.4322/acr.2019.106>

### ABSTRACT

*Acinetobacter baumannii* has emerged as a pan-resistant superbug causing fatal infections in vulnerable patients. This report is the case of an immunosuppressed transplant patient with a fatal pneumonia due to pan-resistant *Acinetobacter baumannii*. Alternative therapy for resistant *Acinetobacter* infection is currently the subject of intense interest and research. This report illustrates the features of this type of emerging infectious disease and reviews some of the novel approaches to treatment.

### Keywords:

*Acinetobacter*; Pneumonia; Drug resistance, Bacterial; Autopsy.

### CASE REPORT

This 48-year-old white male presented with progressive dyspnea. He had first developed dyspnea on exertion in his third decade of life, between 20 and 29 years of age. He had a 4 pack-year history of smoking, which he discontinued when he began having dyspnea on exertion. He carried a diagnosis of asthma treated with various inhalers and corticosteroids with inconsistent results. Progressive dyspnea eventually prompted a referral to a pulmonologist, who diagnosed alpha-1-antitrypsin deficiency and began replacement therapy with weekly infusions of alpha-1-proteinase inhibitor, starting 4 years prior. The patient experienced a decreased frequency of exacerbations of his pulmonary disease initially following replacement therapy. He was also put on daily corticosteroid therapy and had 3 or 4 hospitalizations per year for exacerbations, which were treated with high dose corticosteroid therapy and antibiotics. The patient also had a history of hypertension, osteoporosis, a pulmonary nodule unchanged over several years, and

a pancreato-duodenal artery aneurysm managed with embolization. He had no history of liver disease. He had a sister with alpha-1-antitrypsin deficiency.

The patient presented for lung transplant evaluation when computed tomography (CT) scan of the chest showed diffuse panlobular emphysema involving all lobes of both lungs. Pulmonary function tests revealed a first-second forced expiratory volume (FEV1) 16% of predicted, forced vital capacity (FVC) 40% of predicted, vital capacity (VC) 43% of predicted, total lung capacity (TLC) 144% of predicted and diffusing capacity of the lungs for carbon monoxide (DLCO) 20% of predicted. Arterial blood showed pH 7.44, PCO<sub>2</sub> 44 mm Hg and PO<sub>2</sub> 63 mm Hg. Transthoracic echocardiogram showed normal left ventricular size and function (ejection fraction 55-60%) and a mildly dilated right ventricle with mildly decreased function. Cardiac catheterization revealed lesions of the left anterior descending coronary artery (mid 80% and 90% sequential).

<sup>a</sup> Mercer University School of Medicine, Department of Pathology. Macon, Georgia, USA.



Four months later, the patient underwent double lung transplantation and coronary artery bypass grafting. The coronary artery bypass grafting was initially performed using the left internal mammary artery, but hypokinesia of the distal anterior left ventricular wall prompted revision of the bypass grafting using a saphenous vein. Pathologic examination of the patient's native lungs showed bullous emphysema, bronchiectasis, focal dust macules, macrophages with dust particles, airspace "smoker's macrophages", and reactive peribronchial lymph nodes, some with anthracosilicotic nodules.

In the immediate postoperative period, the patient had hypotension requiring infusions of two vasopressors, epinephrine and phenylephrine. His postoperative medications included tacrolimus, mycophenolate, alemtuzumab and methylprednisolone, along with aztreonam, voriconazole, valganciclovir and metronidazole.

Bleeding complicated the patient's postoperative course, with excessive chest tube drainage. His platelet count was 191,000/mm<sup>3</sup> (reference range [RR]: 156,000-369,000/mm<sup>3</sup>), international normalized ratio (INR) 1.2 (RR: 0.8-1.2) and partial thromboplastin time (PTT) 37.8 seconds (RR: 25-33 seconds). He continued to have excessive chest tube drainage despite transfusion of fresh frozen plasma and platelets. On postoperative day 1 (PO1), the patient's chest was explored. He had small areas of oozing including one area of mild oozing from the posterior of the left atrial right pulmonary venous suture line, which was closed with sutures, while other areas of oozing were treated with cautery. Blood was evacuated from the pleural cavities.

The patient's respiratory function was adequate to permit extubation on PO3. Sterility cultures from the donor right bronchus were positive for methicillin-sensitive *Staphylococcus aureus* and the patient was treated with cefazolin. Between PO1 and PO8, the patient had improving lung function. Subcutaneous emphysema of the left chest and hyponatremia were the main problems during this period.

On PO10, computed tomography of the chest showed moderate bilateral anterior pneumothoraces and left pleurocutaneous communication. Between PO9 and PO14, the patient was relatively stable, although he had persistently low blood pressure treated with fludrocortisone. On PO14, the patient's

blood pressure was 87/47 mm Hg. On the day after, the patient had pain his ribs and legs. His temperature was 36.8° C, heart rate 104/minute, blood pressure 75/46 mm Hg, respirations 18/minute, and saturation 98% on supplemental oxygen at 2 L/minute. He had slightly decreased chest wall subcutaneous emphysema, along with a persistent air leak, scattered rhonchi in both bases, non-tender abdomen and moderate edema of the distal lower extremities. His hemoglobin (Hgb) was 7.1 g/dL (RR: 12.9-16.9 g/dL), white blood cell count 9,000/mm<sup>3</sup> (RR: 3,800-10,600/mm<sup>3</sup>), platelet count 330,000/mm<sup>3</sup>, creatinine 2.2 mg/dL (RR: 0.8-1.5 mg/dL) and tacrolimus level 8.9 ng/mL. His evening dose of tacrolimus was held.

On PO16, the patient's clinical condition deteriorated. He had worsening hypotension with a central venous pressure of 11 mm Hg and was started on an infusion of dopamine. He had decreasing urine output. He had findings of possible early cellulitis in his legs and was restarted on cefazolin, while voriconazole and valganciclovir were discontinued. His white blood cell count was 15,900/mm<sup>3</sup> (50% neutrophils, 48% bands, 2% monocytes), platelet count 347,000/mm<sup>3</sup>, urea nitrogen 214 mg/dL (RR: 10-42 mg/dL), creatinine 2.3 mg/dL, bilirubin 2.9 mg/dL (RR: 0.3-1.5 mg/dL), alkaline phosphatase 939 U/L (RR: 40-125 U/L), alanine aminotransferase (ALT) 64 U/L (RR: <40 U/L), gamma-glutamyl-transferase (GGT) 709 U/L (RR: <30 U/L), albumin 2.6 g/dL (RR: 3.5-5 g/dL) and tacrolimus level 12.8 ng/mL. Tacrolimus was held. Computed tomography showed right lower lobe pneumonia, bilateral pneumothoraces, bilateral chest tubes in good position and subcutaneous emphysema. He was transfused 2 units of red blood cells with an increase in his Hgb to 11.3 g/dL

On PO17, in the morning, the patient's Hgb was 10.1 g/dL, white blood cell count 8,500/mm<sup>3</sup> (53% neutrophils, 35% bands, 3% lymphocytes), platelets 165,000/mm<sup>3</sup>, urea nitrogen 231,4 mg/dL, creatinine 1.9 mg/dL, bilirubin 2.5 mg/dL, alkaline phosphatase 614 U/L, ALT 42 U/L, GGT 481 U/L, albumin 1.6 g/dL and tacrolimus level 10.1 ng/mL. In the afternoon, the patient's clinical condition deteriorated; he required an increasing fraction of inspired oxygen (FiO<sub>2</sub>), up to 90%, to maintain an adequate PO<sub>2</sub>. At 14:19 chest x-ray showed consolidation of right mid and lower lung zones. He was intubated and bronchoscopy showed an area in the membranous portion of the right bronchial anastomosis where 2 of the running sutures appeared

to be pulled off the epithelium, through which a clip could be seen. There was no air bubbling through, but there was evidence of disruption of the superficial layers. Gram stain of Bronchoalveolar lavage showed many white blood cells and many Gram-negative rods and many Gram-positive cocci in pairs. The patient was given empirical antibiotic therapy with meropenem and a dose of vancomycin. He required increasing vasopressor support with epinephrine and vasopressin. He had severe acidosis pH 7.16, PCO<sub>2</sub> 59 mm Hg and PO<sub>2</sub> 87 mm Hg at 17:20. He was given sodium bicarbonate. His hypoxemia did not improve despite an FiO<sub>2</sub> of 100% and increasing positive end-expiratory pressure. At 22:57, chest radiograph showed worsening bilateral airspace consolidation.

On PO18, at 01:00, arterial blood showed pH 7.19, PCO<sub>2</sub> 83 mm Hg, PO<sub>2</sub> 61 mm Hg, bicarbonate 30 mEq/L (RR: 22-26 mEq/L), lactate 14.2 mEq/L (RR: 0.5-1.6 mEq/L), Hgb 10.4 g/dL and potassium 4.3 mEq/L (RR: 3.5-5 mEq/L). The patient had a very poor prognosis. A decision was reached with his family not to further escalate interventions, and not to perform cardiopulmonary resuscitation. The patient died an hour later.

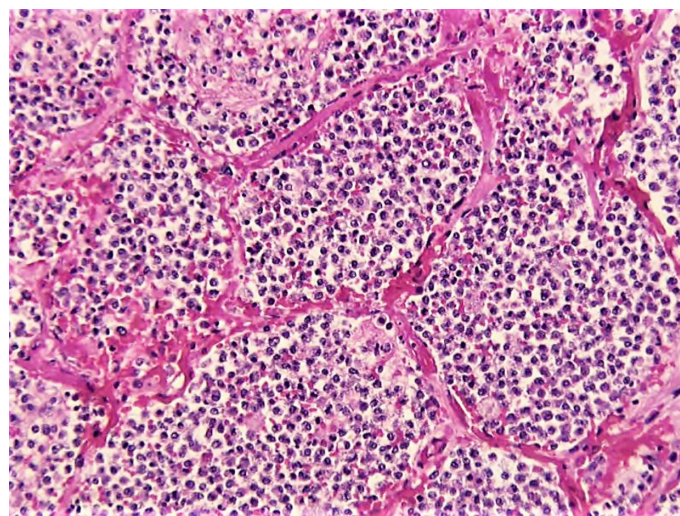
## AUTOPSY FINDINGS

Postmortem examination revealed acute bacterial pneumonia, severe in the right middle lobe and moderate in the right upper lobe. The right lower lobe showed pneumonia that was moderate and in an early subacute phase. There was severe subacute pneumonia in the left lower lobe (Figure 1) and mild fibrinous pleuritis over both lungs.

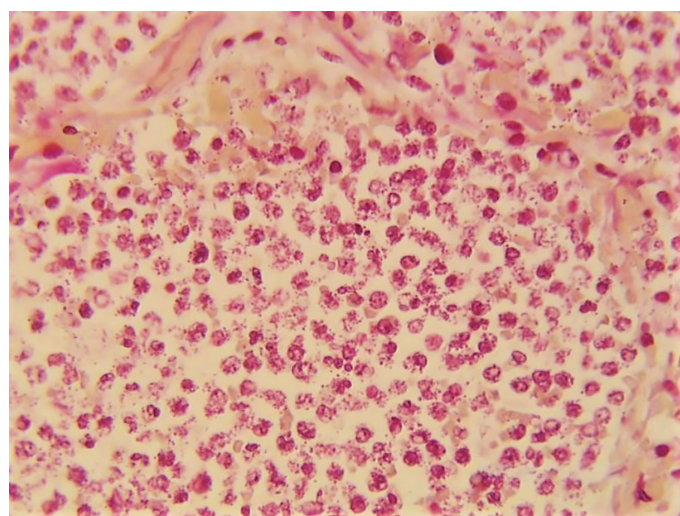
Autopsy revealed severe acute bronchitis with invading bacteria and a gap exposing 2 sutures at the right bronchial anastomosis. Gram stain of lung showed myriads of Gram-negative bacilli (Figure 2).

Autopsy also showed extensive hepatocyte hydropic degeneration (nonspecific edema) with alpha-1-antitrypsin globules (specific confirmation of the diagnosis of alpha-1-antitrypsin deficiency). The heart had findings of subendocardial ischemia and infarction of the upper septum and (focally) right ventricle and (at pulmonary venous anastomosis) left atrium, but the saphenous vein bypass graft to the left anterior descending coronary artery was patent, without lesions. The adrenal glands showed cortical

atrophy. Postmortem lung culture was positive for heavy growth of *Acinetobacter baumannii*. Postmortem blood and spleen cultures were also positive for *Acinetobacter baumannii*. Following the patient's death, bronchoalveolar lavage culture from PO17 were reported positive for >100,000/mL *Acinetobacter baumannii* resistant to all antibiotics tested. Blood cultures from the same day were also reported positive for *Acinetobacter baumannii* resistant to all antibiotics tested.



**Figure 1.** Photomicrograph of the lung. The alveoli are filled with inflammatory cells mixed with some fibrin and a few red blood cells. Most of the inflammatory cells are macrophages (characteristic of subacute phase pneumonia), replacing neutrophils (characteristic of acute phase pneumonia) (H&E,200X).



**Figure 2.** Photomicrograph of the lung. There are large numbers of small Gram-negative coccobacilli, many of them intracellular (Brown and Brenn, 400X).

## DISCUSSION

*Acinetobacter baumannii* has emerged as a life-threatening pathogen in vulnerable patients with, for instance, immunosuppression, cancer or neonatal hospitalization.<sup>1-3</sup> The pathogenicity of *Acinetobacter* is not due to virulence, but rather its resistance to antibiotics and ability to persist on the surfaces of beds, curtains, walls, medical devices, tap water sinks, telephones, door handles, hand sanitizers and computer keyboards.<sup>4</sup> *Acinetobacter* is a special scourge as a cause of pneumonia in patients on mechanical ventilation in hospital intensive care units.<sup>5</sup> It is noteworthy that the patient of this case report was not only on mechanical ventilation in an intensive care unit, but was also immunosuppressed for transplantation.

The patient of this case report had a bacteremic infection and the infection was fatal. Fatality in bacteremic infections with carbapenem and colistin resistant Gram-negative bacilli has been linked to the antibiotic resistance. In one study, 30-day all-cause mortality was 22% in patients with carbapenem sensitive bacteremia and 62% in patients with carbapenem resistant bacteraemia.<sup>6</sup> This raises the specter of lethal untreatable infections, which had passed out of most living memory since the pre-antibiotic era. Deaths from untreatable infections like the one in this case report have led some to suggest that we are seeing the start of a post-antibiotic era.<sup>7</sup>

The emergence of infections by superbug pan-resistant *Acinetobacter* has spurred intense research into alternative therapies. One of the leading alternative therapies is with bacteriophages, viruses of bacteria, which had passed out of favor in the antibiotic era of the past hundred years.<sup>8</sup> In one well-publicized case of a 68-year-old diabetic patient with necrotizing pancreatitis complicated by a multi-drug resistant *Acinetobacter baumannii* infection, he deteriorated over 4 months despite percutaneous drainage of a pancreatic pseudocyst. Two laboratories identified nine different bacteriophages with lytic activity for an *Acinetobacter* isolate from this patient, and administration of these bacteriophages intravenously and percutaneously into the abscess cavities was associated with reversal of the patient's downward clinical trajectory, clearance of the *Acinetobacter* infection, and a return to

health.<sup>9</sup> One of the major factors contributing to antibiotic resistance in *Acinetobacter baumannii* infections is biofilm development. Quorum sensing facilitates biofilm formation and therefore quorum quenching substances have emerged as a possible alternative therapy.<sup>10</sup> Another strategy is to combine antibiotics with new beta-lactamase inhibitors, for which the search is on.<sup>11</sup> Yet another strategy is one that utilizes knowledge from the era before bacteriophage therapy. A shortage of conventional medicine during the American Civil War (1861-1865) spurred Confederate physicians to use preparations of native plants as medicines. In 1863, botanist Francis Porcher compiled a book of medicinal plants native to the southern United States, including plants used in Native American traditional medicine. Testing these plant substances has shown some efficacy in inhibiting the growth, biofilm formation, and quorum sensing by multidrug-resistant bacteria.<sup>12</sup>

In the meantime, while these alternative therapies are in development, the most important aspect of these infections is prevention.<sup>5,13</sup> The unit in which the patient of this case report was hospitalized had a significant incidence of extensively resistant and pan-resistant *Acinetobacter baumannii* infections.<sup>14</sup> In this unit, the emergence of colistin-resistant *Acinetobacter baumannii* was almost exclusively in patients who had received colistin for carbapenem-resistant *Acinetobacter baumannii* infection.<sup>14</sup> This makes antibiotic stewardship aimed at limiting the use of antibiotics causing the emergence of resistance a crucial element in prevention. In outbreaks, enhanced audit to identify common sources, particularly contaminated equipment or fomites, and feedback of environmental cleaning can be helpful.<sup>13</sup> Healthcare worker hand hygiene, contact precautions and cohorting can aid in stemming outbreaks. Routine chlorhexidine bathing has been part of the infection control bundle curtailing some outbreaks.<sup>13</sup> Infections with pan-resistant pathogens are often preceded by colonization, so another important aspect of these infections is prevention of colonization.<sup>15</sup> The case reported here illustrates the urgency of the problem of pan-resistant superbugs.

Informed consent for the autopsy was given by the next of kin and manuscripts of case reports are not reviewed by the Institutional Review Board.

## REFERENCES

1. Serifoglu I, Er Dedekarginoglu B, Savas Bozbas S, Akcay S, Haberal M. Clinical characteristics of *Acinetobacter baumannii* infection in solid-organ transplant recipients. *Exp Clin Transplant*. 2018;16(Suppl 1):171-5. PMID:29528021.
2. Zhou S, Fan L, Wang Z, et al. Increasing rates of *Acinetobacter baumannii* infection and resistance in an oncology department. *J Cancer Res Ther*. 2018;14(1):68-71. [http://dx.doi.org/10.4103/jcrt.JCRT\\_737\\_17](http://dx.doi.org/10.4103/jcrt.JCRT_737_17). PMID:29516962.
3. Maciel WG, Silva KE, Croda J, et al. Clonal spread of carbapenem-resistant *Acinetobacter baumannii* in a neonatal intensive care unit. *J Hosp Infect*. 2018;98(3):300-4. <http://dx.doi.org/10.1016/j.jhin.2017.10.015>. PMID:29107079.
4. Asif M, Alvi IA, Rehman SU. Insight into *Acinetobacter baumannii*: pathogenesis, global resistance, mechanisms of resistance, treatment options, and alternative modalities. *Infect Drug Resist*. 2018;11:1249-60. <http://dx.doi.org/10.2147/IDR.S166750>. PMID:30174448.
5. Vazquez Guillamet C, Kollef MH. *Acinetobacter* pneumonia: improving outcomes with early identification and appropriate therapy. *Clin Infect Dis*. 2018;67(9):1455-62. <http://dx.doi.org/10.1093/cid/ciy375>. PMID:29741597.
6. Balkhair A, Al-Muharrmi Z, Al'Adawi B, et al. Prevalence and 30-day all-cause mortality of carbapenem and colistin resistant bacteraemias caused by *Acinetobacter baumannii*, *Pseudomonas aeruginosa*, and *Klebsiella pneumoniae*: a description of a decade long trend. *Int J Infect Dis*. 2019;14(19):30210-3. <http://dx.doi.org/10.1016/j.ijid.2019.05.004>.
7. Jones CA, Davis JS, Looke DF. Death from an untreatable infection may signal the start of the post-antibiotic era. *Med J Aust*. 2017;206(7):292-3. <http://dx.doi.org/10.5694/mja17.00077>. PMID:28403759.
8. Bagińska N, Pichlak A, Górski A, Jończyk-Matysiak E. Specific and selective bacteriophages in the fight against multidrug-resistant *Acinetobacter baumannii*. *Virol Sin*. 2019;1-11. <http://dx.doi.org/10.1007/s12250-019-00125-0>. PMID:31093881.
9. Schooley RT, Biswas B, Gill JJ, et al. Development and use of personalized bacteriophage-based therapeutic cocktails to treat a patient with a disseminated resistant *Acinetobacter baumannii* infection. *Antimicrob Agents Chemother*. 2017;61(10):e00954-17. <http://dx.doi.org/10.1128/AAC.00954-17>. PMID:28807909.
10. Saipriya K, Swathi CH, Ratnakar KS, Sriharan V. Quorum sensing system in *Acinetobacter baumannii*: a potential target for new drug development. *J Appl Microbiol*. 2019;00:1-13. <http://dx.doi.org/10.1111/jam.14330>. PMID:31102552.
11. El Hafi B, Rasheed SS, Abou Fayad AG, Araj GF, Matar GM. Evaluating the efficacies of Carbapenem/ $\beta$ -Lactamase inhibitors against Carbapenem-Resistant Gram-Negative Bacteria in vitro and in vivo. *Front Microbiol*. 2019;10:933. <http://dx.doi.org/10.3389/fmicb.2019.00933>. PMID:31114565.
12. Dettweiler M, Lyles JT, Nelson K, et al. American Civil War plant medicines inhibit growth, biofilm formation, and quorum sensing by multidrug-resistant bacteria. *Sci Rep*. 2019;9(1):7692. <http://dx.doi.org/10.1038/s41598-019-44242-y>. PMID:31118466.
13. Pouch SM, Patel G. Community of Practice – Multidrug-resistant Gram-Negative Bacterial infections in solid organ transplant recipients - Guidelines from the American Society of Transplantation Infectious Diseases Community of Practice. *Clin Transplant*. 2019;18:e13594. <http://dx.doi.org/10.1111/ctr.13594>. PMID:31102483.
14. Qureshi ZA, Hittle LE, O'Hara JA, et al. Colistin-resistant *Acinetobacter baumannii*: beyond carbapenem resistance. *Clin Infect Dis*. 2015;60(9):1295-303. <http://dx.doi.org/10.1093/cid/civ048>. PMID:25632010.
15. Thorne A, Luo T, Durairajan NK, Kaye KS, Foxman B. Risk factors for endemic *Acinetobacter Baumannii* colonization: a case-case study. *Am J Infect Control*. 2019;19:30462-6. <http://dx.doi.org/10.1016/j.ajic.2019.04.179>. PMID:31253551.

**Author contributions:** Nichols L signed out the autopsy and wrote all of the manuscript.

**Conflict of interest:** None

**Financial Support:** None

**Submitted on:** May 26<sup>th</sup>, 2019

**Accepted on:** June 30<sup>th</sup>, 2019

### Correspondence

Larry Nichols

Department of Pathology - Mercer University School of Medicine

1501 Mercer University Drive - Macon/GA - USA

31207

Phone: 478-304-2405

nichols\_l@mercer.edu