




## Diagnosis, management, and follow-up of extensive dermoid cyst of the submental region

Débora Menezes Regis<sup>a</sup> , John Lennon Silva Cunha<sup>b</sup> ,  
Celeste Sánchez-Romero<sup>b</sup> , Maria Alice Carvalho da Cruz Ramos<sup>a</sup> ,  
Ricardo Luiz Cavalcanti de Albuquerque Júnior<sup>c</sup> , Bruno Torres Bezerra<sup>a</sup> 

**How to cite:** Regis DM, Cunha JLS, Sánchez-Romero C, Ramos MACC, Albuquerque Júnior RLC, Bezerra BT. Diagnosis, management, and follow-up of extensive dermoid cyst of the submental region. *Autops Case Rep* [Internet]. 2019 Jul-Sep;9(3):e2019095. <https://doi.org/10.4322/acr.2019.095>

### ABSTRACT

Dermoid cyst (DC) is a cystic lesion of developmental origin and uncertain etiology that rarely affects the floor of the mouth. We report a case of a large lesion found in the submental and submandibular region in a 25-year-old male patient. Computed tomography revealed extensive hypodense lesion in the submental and submandibular space without peripheral enhancement. The microscopical analysis showed a cystic cavity lined by orthokeratinized stratified squamous epithelium. The cystic capsule was composed of dense fibrous connective tissue containing cutaneous attachments, such as sebaceous and sweat glands. The diagnosis of DC was made. The differential diagnosis of expansive sublingual lesions can be clinically challenging due to the similarity with several lesions frequently observed in this region. Herein, we describe a case of extensive DC arising in the floor of the mouth, presenting clinical, imaging, and microscopical features.

### Keywords

Dermoid Cyst; Mouth Floor; Diagnostic Imaging; Ultrasonography; Tomography, X-Ray Computed.

### CASE REPORT

A 25-year-old Afrodescendant male patient presented at the oral medicine service with a large, fluctuant, painless swelling with resilient consistency in the submental and left submandibular region (Figure 1A-C). Intraorally, there was a small, smooth surfaced, normochromic and movable mass in the floor of the mouth, adjacent to the lingual frenulum.

Ultrasonography (US) of the left submandibular gland showed a well-defined, homogeneous, round, and hyperechoic mass with a diameter of 6.8 × 4.7 cm localized between the geniohyoid and mylohyoid muscle that extended to the medial region of the neck.

Also, ductal dilatation and lithiasis were discarded. Computed tomography (CT) showed a well-defined cystic lesion in the submental and submandibular space without peripheral enhancement (Figure 2).

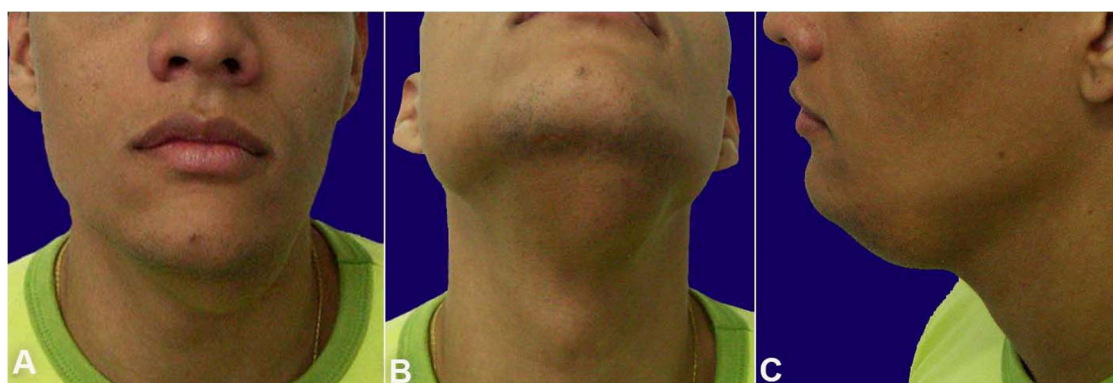
The aspiration puncture was performed and demonstrated a content of friable and white material. The diagnostic hypotheses established by the dentist were plunging ranula, dermoid cyst, or epidermoid cyst. Surgical excision of the lesion was performed through an extraoral incision (Figure 3A-C) under general anesthesia and nasotracheal intubation.

<sup>a</sup> Tiradentes University (UNIT), Department of Dentistry. Aracaju, SE, Brazil.

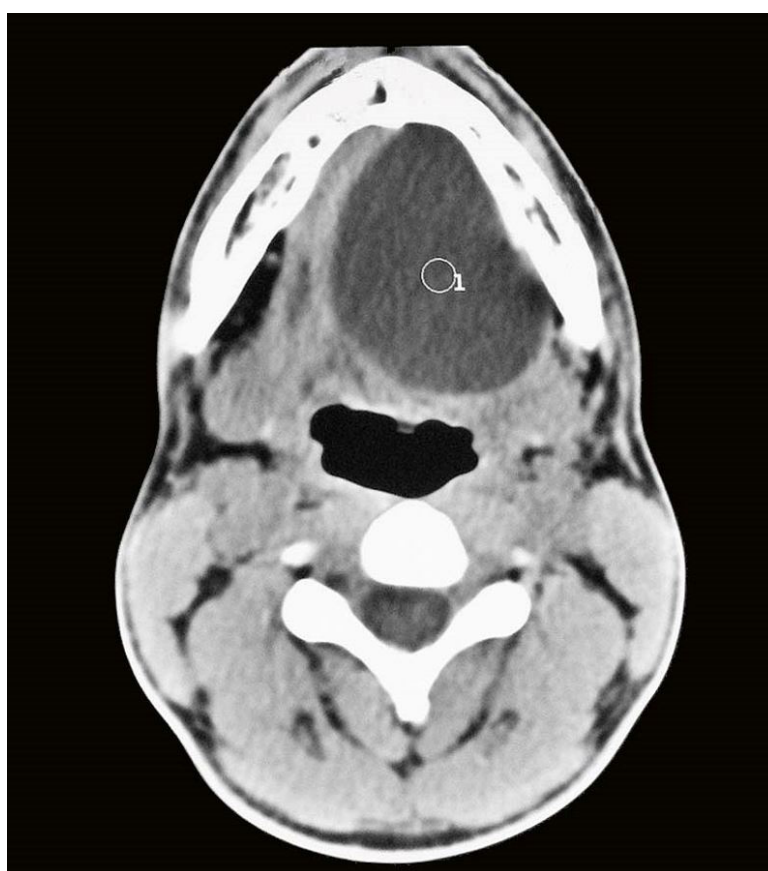<sup>b</sup> University of Campinas (UNICAMP), Piracicaba Dental School, Department of Oral Diagnosis, Oral Pathology Section. Piracicaba, SP, Brazil.

<sup>c</sup> Tiradentes University (UNIT), Institute of Technology and Research, Laboratory of Morphology and Experimental Pathology. Aracaju, SE, Brazil.





**Figure 1.** **A** and **B** – Preoperative frontal and **C** – lateral views showing swelling of the submental and submandibular left region.

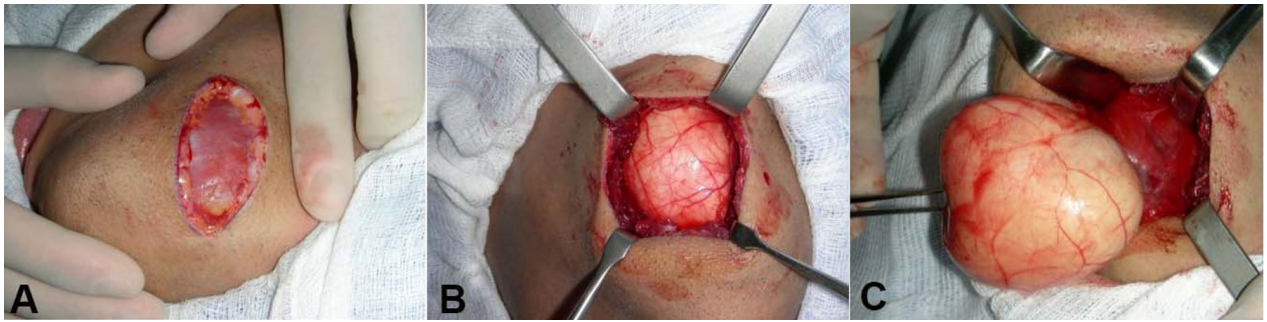


**Figure 2.** Pre-operative computed tomography image. Axial scan with a well-defined unilocular cystic lesion in the floor of the mouth.

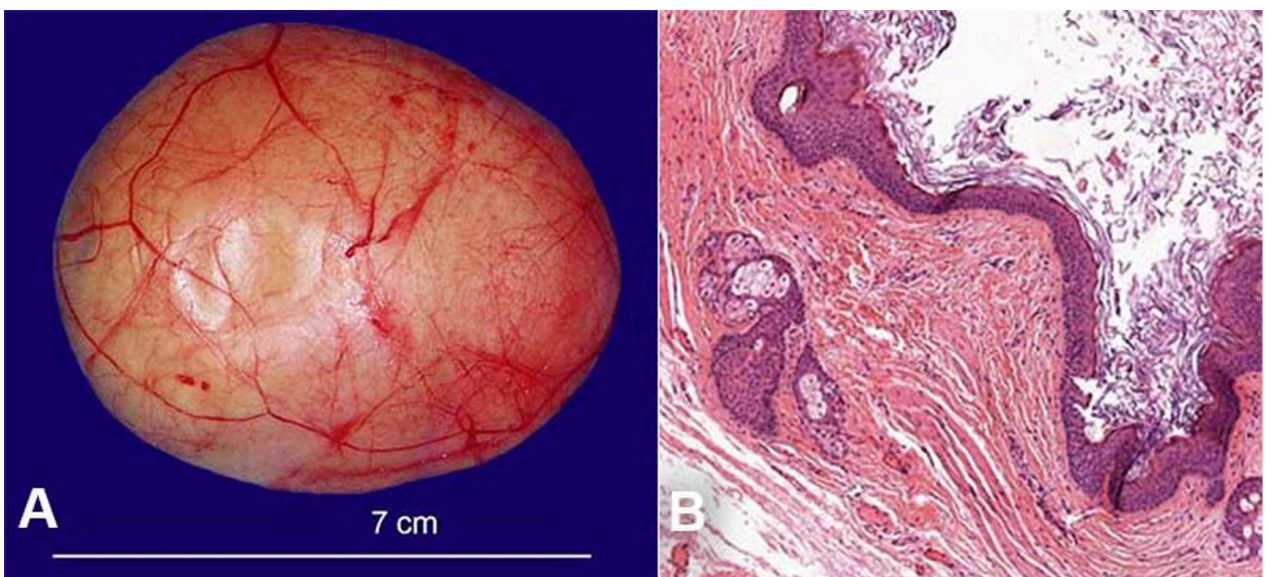
The surgical specimen was submitted to histopathologic examination. Gross examination revealed a well-circumscribed, solid oval mass, with a firm consistency and a yellowish surface (Figure 4A). On the cross-section, the tumor showed a cystic structure varying in color from gray to dark brown, contained a keratin-like yellow material. Microscopic examination revealed a cystic cavity lined by orthokeratinized stratified squamous epithelium,

exhibiting acanthosis, and hypergranulosis. The cystic capsule was composed of dense fibrous connective tissue containing cutaneous adnexa, such as sebaceous and sweat glands. Additionally, discrete chronic inflammatory infiltrate was observed (Figure 4B).

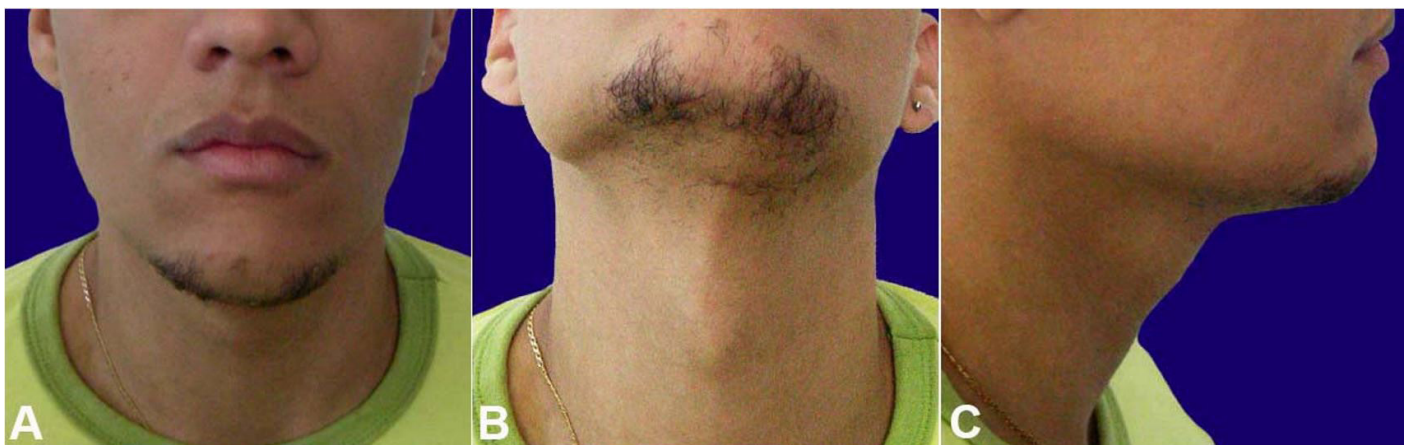
Based on these findings, the histologic diagnosis was DC. The patient is under follow-up without signs of recurrence two years after the surgery (Figure 5A-C).



**Figure 3.** **A** – Extraoral incision performed for surgical removal of the lesion; **B** and **C** – Intraoperative panoramic view of the tumor.



**Figure 4.** **A** – Gross aspect showing a well-circumscribed, solid oval mass, with a yellowish surface; **B** – Photomicrograph of the cyst wall showing an orthokeratinized stratified squamous epithelium supported by a fibrous wall of dense connective tissue with the presence of variable numbers of sebaceous glands. Keratinous debris could also be seen in the lumen (Hematoxylin & eosin, original magnification 100x).



**Figure 5.** **A** and **B** – Frontal and **C** – lateral view of the patient two years after the surgical removal of the lesion, without signs of relapse.

## DISCUSSION

Dermoid cyst (DC) is an uncommon lesion of developmental origin and uncertain etiology. DCs tend to occur in adults between the first and the third decades of life, being observed with a certain frequency (14.9%) in newborns and do not show sex predilection.<sup>1</sup> Most of the lesions occur in the ovary and scrotal regions. Approximately 7% of cases of DC are diagnosed in the head and neck region.<sup>2,3</sup> These lesions are extremely rare in the oral cavity, accounting for approximately 1.6% of all dermoid cysts<sup>3</sup> and when it occurs intraorally, the floor of the mouth is the anatomical site more frequently involved.<sup>4,5</sup> Other sites include the tongue, lips, and palate.

Clinical signs and symptoms mainly depend on the affected anatomical sites and vary considerably. Although most cases are asymptomatic<sup>3,4,6</sup> such as ours; pain is common if secondary infection is present. The typical clinical presentation in the floor of the mouth is asymptomatic swelling of slow growth located in the midline covered by the normal mucosa.<sup>3,4</sup> However, the location of the DC concerning the geniohyoid and mylohyoid muscles influences its clinical presentation. DCs located above the geniohyoid muscle are presented as swelling in the sublingual region. On the other hand, when the cyst is located between or below the geniohyoid and mylohyoid muscle, a swelling is evident in the submental region, as observed in the present case.<sup>3,4,6</sup> Other complaints may also be observed, including altered speech, difficulties with swallowing, phonation, and respiration, and double-chin development, especially in large lesions.<sup>3,4</sup> In this case, the patient reported swallowing and breathing difficulty, probably due to the posterior expansion of the lesion in the submandibular space. Large lesions, as observed in the present case, may also make it difficult or impossible for the patient to intubate during a general anesthesia process<sup>1</sup> and it can also pose a critical risk to the airway.<sup>3</sup> In these cases, partial aspiration of the cystic content of the lesion is recommended to improve patient breathing or facilitate intubation.<sup>1</sup>

The differential diagnosis of expansive sublingual lesions can be clinically challenging due to the clinical similarity with several lesions frequently observed in this region.<sup>7</sup> The nonspecific clinical presentation and the

rarity of DC make differential diagnosis wide and include infectious lesions of the salivary glands (sialadenitis), ranula, epidermoid cyst, lipoma, hemangiomas or lymphangiomas, sialoliths obstructing submandibular duct, branchial cleft cyst, and thyroglossal duct cyst.<sup>4,6,8</sup> In our case, the differential diagnosis included conditions commonly observed in adults patients, and the hypotheses included plunging ranula, dermoid cyst, and epidermoid cyst.

Imaging is necessary during the clinical investigation to guide the diagnosis and treatment.<sup>5,9</sup> Therefore, we requested ultrasonography and computed tomography (CT) to better evaluate the patient's condition. The ultrasonography typically shows a well-circumscribed tumor with mixed or pseudo solid density<sup>2</sup>, as observed in our case. However, comparing with ultrasonography, the computed tomography and magnetic resonance imaging (MRI) are more advantageous because they provide accurate information about the size and location of the lesion, facilitating surgical planning<sup>5</sup>. Also, fine-needle aspiration cytology (FNAC) may provide important diagnostic information of the cystic lesions. However, the definitive diagnosis can only be confirmed by morphological analysis.<sup>2</sup>

The microscopical features of DCs are usually characteristic. The lining of the cyst is composed of orthokeratinized squamous epithelium with a prominent granular layer, and a cystic capsule composed of dense connective tissue. The lesion typically contains skin appendages, such as sebaceous glands, hair follicles and/or sweat glands.<sup>1,4,6,8,10</sup> The presence of cutaneous adnexa is the main histological difference with epidermoid cysts. On the other hand, teratoid cysts, contain tissues derived from the three germ layers (endoderm, mesoderm, and ectoderm).<sup>1,6</sup> In general, these cysts have thin walls (2 to 6 mm thick) and often contain a yellowish oily material, representing keratin and sebaceous material.<sup>6,8</sup> In our case, the histopathology was consistent with a DC.

Conservative surgical excision is the treatment of choice, and the prognosis is excellent.<sup>3,4,6</sup> Often, DCs in the oral floor can be removed by intraoral incision, while extensive submental lesions, as seen in the current case, require extraoral access.<sup>4,6</sup> However, in some cases, there is a need to use both accesses. Malignant transformation has been reported but is rare<sup>1</sup>, and relapses are uncommon.<sup>3,4</sup>

## REFERENCES

1. Jayasuriya NSS, Siriwardena S, Tilakaratne WM, Parthiepan S. Malignant transformation of a longstanding submental dermoid cyst to a carcinosarcoma: a case report. *J Med Case Reports*. 2017;11(1):11. <http://dx.doi.org/10.1186/s13256-016-1186-y>. PMID:28077165.
2. Glaas MF, Schipper J, Kajasi N, Albrecht A. The youngest reported and successfully treated patient with a dermoid cyst of the parotid gland: a rare pediatric case. *Case Rep Otolaryngol*. 2017;2017:4187030. <http://dx.doi.org/10.1155/2017/4187030>. PMID:28791189.
3. Kim JP, Lee DK, Moon JH, Park JJ, Woo SH. Transoral dermoid cyst excision: a multicenter prospective observational study. *Otolaryngol Head Neck Surg*. 2018;159(6):981-6. <http://dx.doi.org/10.1177/0194599818791772>. PMID:30149779.
4. Şimşek-Kaya G, Özbudak I, Kader D. Coexisting sublingual dermoid cyst and heterotopic gastrointestinal cyst: case report. *J Clin Exp Dent*. 2018;10(2):e196-9. <http://dx.doi.org/10.4317/jced.53817>. PMID:29670741.
5. Otonari-Yamamoto M, Nakajima K, Sakamoto J, et al. Atypical MRI and histopathological findings in dermoid cyst. *Bull Tokyo Dent Coll*. 2018;59(3):207-12. <http://dx.doi.org/10.2209/tdcpublication.2017-0044>. PMID:30224615.
6. Patel H, Mayl J, Chandra B, Pritchett C, Chandra T. Dermoid of the oral cavity: case report with histopathology correlation and review of literature. *Radiology Case*. 2016;10(12):19-27. <http://dx.doi.org/10.3941/jrcr.v10i12.2995>. PMID:28580062.
7. Puricelli E, Barreiro BOB, Quevedo AS, Ponzoni D. Occurrence of dermoid cyst in the floor of the mouth: the importance of differential diagnosis in pediatric patients. *J Appl Oral Sci*. 2017;25(3):341-5. <http://dx.doi.org/10.1590/1678-7757-2016-0411>. PMID:28678954.
8. Ramanathan M, Balasundharam S, Christabel A, Murali P, Pandem S. simultaneous occurrence of a midline sublingual dermoid cyst with respiratory epithelium and submental dermoid cyst in a paediatric patient: a case report and review of literature. *J Maxillofac Oral Surg*. 2018;17(2):188-92. <http://dx.doi.org/10.1007/s12663-016-0972-9>. PMID:29618884.
9. Giarraputo L, Savastano S, D'Amore E, Baciliero U. Dermoid cyst of the floor of the mouth: diagnostic imaging findings. *Cureus*. 2018;10(4):e2403. <http://dx.doi.org/10.7759/cureus.2403>. PMID:29872584.
10. Mumtaz S, Singh M. Transoral marsupialization of a large dermoid cyst. *J Oral Maxillofac Surg*. 2019;77(4):753-6. <http://dx.doi.org/10.1016/j.joms.2018.11.033>. PMID:30611691.

**Author contributions:** Bezerra BT performed the surgical procedure. Albuquerque Júnior RLC and Sánchez-Romero C performed the microscopic and the critical review of the manuscript. Regis DM, Cunha JLS and Ramos MACC reviewed the literature and wrote the manuscript. All authors approved and proofread the final document.

The patient provided an informed consent declaration to permit the use of images and medical information, and the manuscript is in accordance with the Institutional Ethics committee.

**Conflict of interest:** None

**Financial support:** None

**Submitted on:** April 13<sup>th</sup>, 2019

**Accepted on:** May 14<sup>th</sup>, 2019

### Correspondence

John Lennon Silva Cunha

Department of Oral Diagnosis, Oral Pathology Section - Piracicaba Dental School - University of Campinas (UNICAMP)

Av. Limeira 901 – Areião – Piracicaba/SP – Brazil

CEP: 1314-903

Phone: +55 (79) 99654-0805

lennonrr@live.com