

## Fibrosarcomatous dermatofibrosarcoma protuberans from scar following trauma

Sang Wook Lee<sup>a</sup> , Araya Zaesim<sup>a</sup>, Amanda Jackson<sup>a</sup>, Michael Borkat<sup>a,b</sup>

**How to cite:** Lee SW, Zaesim A, Jackson A, Borkat M. Fibrosarcomatous dermatofibrosarcoma protuberans from scar following trauma. *Autops Case Rep* [Internet]. 2018;8(4):e2018039. <https://doi.org/10.4322/acr.2018.039>

### ABSTRACT

Dermatofibrosarcoma protuberans (DFSP) is an uncommon soft tissue neoplasm of low metastatic potential notable for its progressive growth and high rate of local recurrence after surgical excision. Fibrosarcomatous transformation of DFSP (FS-DFSP) is a rare variant characterized by higher rates of local recurrence and metastasis. Trauma has been hypothesized as a potential risk factor for the development of DFSP, although clear evidence has been lacking. In this study, we report a case of FS-DFSP that was found arising from a previously stable scar following a traumatic injury. A 49-year-old male was diagnosed with keloid scars following a motor vehicle accident where he sustained trauma. 12 years later, a large tumor developed immediately after a second traumatic event to the primary scar. Pathology of the excisional biopsy specimen demonstrated FS-DFSP with focal areas consistent with keloid and hypertrophic scar. This observation demonstrates the development of DFSP from underlying scar following a clear history of trauma. Furthermore, it suggests trauma as a possible trigger for the fibrosarcomatous transformation of DFSP.

### Keywords

Dermatofibrosarcoma; Wounds and Injuries; Cicatrix

### CASE REPORT

A 49-year-old African American male presents with a large mass on the left shoulder that has been rapidly enlarging for the past 2 months. The mass grew over a presumed keloid scar, which developed approximately 1 month following a motor vehicle accident 12 years prior. During the accident, he suffered a contusion to the left shoulder that first bruised and subsequently formed a golf ball-sized mass. There was no breakage of skin on the left shoulder. He sought medical attention for the skin lesion at that time and was diagnosed with keloid, which was readily accepted as he had past medical history and similar family history. No treatment for the lesion was performed at that

time. Since then, the lesion had been stable without any change in shape, color, or size until 1.5 years prior to evaluation, when he suffered a minor trauma to the lesion during a work-related injury that did not break the skin barrier. Following this event, he noticed that the lesion slowly increased in size under the skin without apparent cutaneous changes in appearance. Two months before the clinical encounter, he noticed a new rapidly growing nodule on the surface of the initial mass. He noticed no changes in symptomatology other than left shoulder pain and limited range of motion of the neck that became more prominent as the mass increased in size.

<sup>a</sup> Mercer University School of Medicine. Columbus, GA, United States of America.

<sup>b</sup> St. Francis Center for Surgical Care. Columbus, GA, United States of America.



On examination, there were three discrete protuberant tumor nodules, gray-white, involving the skin and subcutis. The largest nodule measured 16 × 15 × 7 cm and the smallest nodule measured 7 × 6 × 3 cm (Figure 1).

The tumor was ulcerated and necrotic without apparent attachment to underlying structures. Anterior cervical, posterior cervical, supraclavicular, and axillary lymph nodes were not palpable bilaterally, and there were no other masses observed. CT of thorax suggested the masses were superficial with no attachment to underlying bone or great vessels, and there was

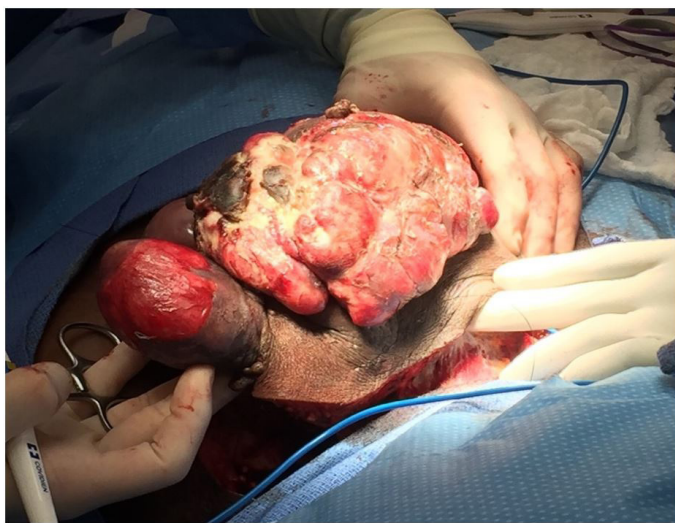no evidence of metastatic disease or adenopathy. A wide excisional biopsy of the lesion was performed. The histological examination revealed a fascicular architectural pattern composed of plump spindle cells with high nuclear grade atypia and numerous mitoses leading to the diagnosis of high-grade fibrosarcoma arising from DFSP (Figure 2A). The spindle cells diffusely express CD34 (Figure 2B).

There were areas showing a transition from scar to DFSP (Figure 3), and focal areas were consistent with keloid.

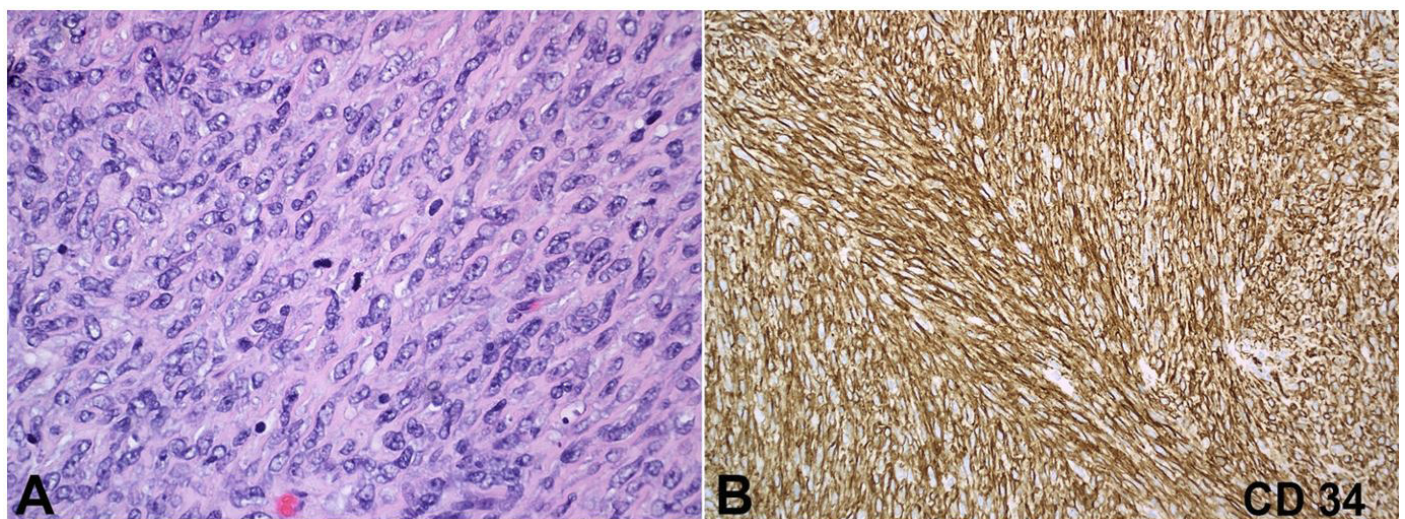
There was also invasion of the lesion into the underlying skeletal muscle as well as focal areas at the deep surgical margin. The post-op course was uneventful. Due to the location and extent of the invasion, further excision was not feasible. A multidisciplinary approach including radiation oncology will be pursued for further treatment. The current plan involves the placement of a skin graft over the incision site followed by radiation treatment to target the remaining lesion. The patient will continue to be observed for recurrence of the tumor to allow for early resection.

## DISCUSSION

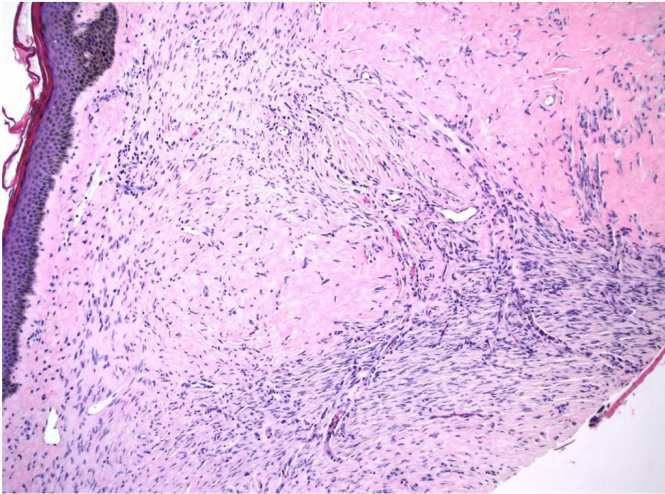
Dermatofibrosarcoma protuberans (DFSP) is a relatively rare soft tissue sarcoma with an estimated overall annual incidence of 4.2 cases per one million persons per year. Black people are affected at almost



**Figure 1.** Resection of the lesion was performed with wide surgical margins from the left mid-clavicular region. The largest mass measured 16 × 15 × 7 cm and the smallest mass measured 7 × 6 × 3 cm.



**Figure 2.** Photomicrograph of resected mass. **A** – demonstrates fibrosarcomatous differentiation of DFSP with cellular atypia with abundant mitotic activity (H&E, 40X); **B** – Immunohistochemistry staining for CD34 marker is diffusely expressed in the spindle cells and highlights the fascicular pattern of this tumor (20x).



**Figure 3.** Photomicrograph of the edge of the lesion shows transition between collagen-rich scar and proliferating spindle cells (HE, 10X).

2 times the rate of whites, and incidence among women is 1.14 times higher than among men.<sup>1</sup> Trauma has been hypothesized as a predisposing factor for DFSP, with reported cases of tumors arising from vaccination sites, burn scars, and surgical scars.<sup>2</sup> These studies<sup>3-6</sup> document roughly 10% of patients providing a history of antecedent traumatic insult; however, mechanistic basis and clear causative relationship have not been identified.<sup>7</sup> DFSP accounts for less than 0.1% of all malignant neoplasms, but it is the most common type of skin sarcoma. The lesion most commonly appears on the trunk, proximal extremities, and the head and neck. Initially, the tumor may appear as a sclerotic plaque-like mass with bluish skin discoloration which can be misinterpreted as a keloid. The tumor may show an initial slow growth phase for several years characterized by lateral spread before reaching a rapid growth phase with vertical infiltration and fixation to deep structures. As the mass enlarges, the overlying skin may ulcerate and bleed.<sup>8</sup> Fibrosarcomatous transformation in DFSP represents tumor progression marked by a more aggressive clinical behavior with higher rates of local recurrence and metastasis.<sup>9,10</sup> Histopathology of fibrosarcomatous foci demonstrates higher cellularity and fascicular pattern of growth rather than the storiform pattern normally seen in DFSP.<sup>11</sup>

Molecular studies have demonstrated that most cases of DFSP can be differentiated from other dermatofibromas by the presence of a  $t(17;22)(q22;q13)$

translocation forming a PDGFB/COL1A1 fusion gene containing a protein of a collagen 1 subunit and a platelet derived growth factor (PDGF) subunit. The translocation has been demonstrated to be present in up to 90% of cases and is a very useful marker for differential diagnosis.<sup>12</sup> Additionally, DFSPs with higher proportions of histologically fibrosarcomatous zones have been demonstrated to have a higher proportion of the translocation. Research investigating the significance of the translocation is still being conducted; nevertheless, the detection of the fusion gene using fluorescence in-situ hybridization (FISH) currently serves as an additional modality of DFSP diagnosis.

Surgical resection remains the treatment of choice, which can be achieved with standard wide local excision with negative margins or Mohs micrographic surgery.<sup>7,13</sup> Currently, a 2-3 cm margin is recommended for resection, and radiotherapy has been postulated as an option for adjuvant therapy, especially in the setting of positive surgical margins when further resection is not feasible.<sup>14,15</sup> Chemotherapy with imatinib mesylate has been used with demonstrable disease regression in DFSP; however, its efficacy and durability for the treatment of FS-DFSP is limited, with most cases showing initial response followed by relapse.<sup>16</sup>

Although DFSP rarely metastasizes, FS-DFSP has a reported metastatic rate of between 14% and 18%.<sup>10,17</sup> Both disease processes can be locally invasive and has a high rate of local recurrence after surgical excision. According to the review of 913 DFSP cases by Rutgers et al.,<sup>18</sup> recurrence after adequate wide excision was 13% compared to the overall recurrence rate of about 50%. Given the tendency for rapid growth, local invasion, recurrence, and cosmetic disfigurement, locally malignant processes such as DFSP should be suspected when patients present with perceived changes in previously stable lesions, even when prior history of trauma clearly predated the skin lesion. Furthermore, because our case demonstrates that DFSP may arise from an underlying scar, clinicians should maintain clinical suspicion of changing lesions even in the setting of biopsy proven benign lesions.

## REFERENCES

1. Kreicher KL, Kurlander DE, Gittleman HR, Barnholtz-Sloan JS, Bordeaux JS. Incidence and survival of primary dermatofibrosarcoma protuberans in the United States.

- Dermatol Surg. 2016;42(Suppl 1):S24-31. <http://dx.doi.org/10.1097/DSS.0000000000000300>. PMID:26730971.
2. Gloster HM Jr. Dermatofibrosarcoma protuberans. *J Am Acad Dermatol*. 1996;35(3):355-74. [http://dx.doi.org/10.1016/S0190-9622\(96\)90597-6](http://dx.doi.org/10.1016/S0190-9622(96)90597-6). PMID:8784271.
  3. Hirano SA, Torosky CM. Dermatofibrosarcoma protuberans arising at a Rho(D) immune globulin injection site. *Cutis*. 2012;90(5):233-4. PMID:23270191.
  4. Green JJ, Heymann WR. Dermatofibrosarcoma protuberans occurring in a smallpox vaccination scar. *J Am Acad Dermatol*. 2003;48(5, Suppl):S54-5. <http://dx.doi.org/10.1067/mjd.2003.168>. PMID:12734474.
  5. Tanaka A, Hatoko M, Tada H, Kuwahara M, Iioka H, Niitsuma K. Dermatofibrosarcoma protuberans arising from a burn scar of the axilla. *Ann Plast Surg*. 2004;52(4):423-5. <http://dx.doi.org/10.1097/01.sap.0000100421.95683.9b>. PMID:15084891.
  6. Saeki H, Kadono T, Le Pavoux A, Mori E, Tamaki K. Dermatofibrosarcoma protuberans with COL1A1-PDGFB fusion transcript arising on a scar due to a previous drainage tube insertion. *J Dermatol*. 2008;35(10):686-8. <http://dx.doi.org/10.1111/j.1346-8138.2008.00545.x>. PMID:19017053.
  7. Reha J, Katz SC. Dermatofibrosarcoma protuberans. *Surg Clin North Am*. 2016;96(5):1031-46. <http://dx.doi.org/10.1016/j.suc.2016.05.006>. PMID:27542641.
  8. Laskin WB. Dermatofibrosarcoma protuberans. *CA Cancer J Clin*. 1992;42(2):116-25. <http://dx.doi.org/10.3322/canjclin.42.2.116>. PMID:1540852.
  9. Reifs CM, Salido-Vallejo R. Dermatofibrosarcoma protuberans with fibrosarcomatous transformation. *An Bras Dermatol*. 2016;91(5):700-1. <http://dx.doi.org/10.1590/abd1806-4841.20164886>. PMID:27828659.
  10. Mentzel T, Beham A, Katenkamp D, Dei Tos AP, Fletcher CD. Fibrosarcomatous ("high-grade") dermatofibrosarcoma protuberans: clinicopathologic and immunohistochemical study of a series of 41 cases with emphasis on prognostic significance. *Am J Surg Pathol*. 1998;22(5):576-87. <http://dx.doi.org/10.1097/0000478-199805000-00009>. PMID:9591728.
  11. Monteagudo C, Llombart B, Burgues O, et al. Biphasic dermatofibrosarcoma protuberans with a labyrinthine plexiform high-grade fibrosarcomatous transformation. *J Cutan Pathol*. 2015;42(3):206-12. <http://dx.doi.org/10.1111/cup.12456>. PMID:25410704.
  12. Segura S, Salgado R, Toll A, et al. Identification of t(17;22) (q22;q13) (COL1A1/PDGFB) in dermatofibrosarcoma protuberans by fluorescence in situ hybridization in paraffin-embedded tissue microarrays. *Hum Pathol*. 2011;42(2):176-84. <http://dx.doi.org/10.1016/j.humpath.2010.07.015>. PMID:21111450.
  13. Dawes KW, Hanke WC. Dermatofibrosarcoma protuberans treated with Mohs micrographic surgery: cure rates and surgical margins. *Dermatol Surg*. 1996;22(6):530-4. <http://dx.doi.org/10.1111/j.1524-4725.1996.tb00369.x>. PMID:8646467.
  14. Rutkowski P, Debiec-Rychter M. Current treatment options for dermatofibrosarcoma protuberans. *Expert Rev Anticancer Ther*. 2015;15(8):901-9. <http://dx.doi.org/10.1586/14737140.2015.1052799>. PMID:26027711.
  15. Stojadinovic A, Karpoff HM, Antonescu CR, et al. Dermatofibrosarcoma protuberans of the head and neck. *Ann Surg Oncol*. 2000;7(9):696-704. <http://dx.doi.org/10.1007/s10434-000-0696-3>. PMID:11034249.
  16. Stacchiotti S, Pantaleo MA, Negri T, et al. Efficacy and biological activity of imatinib in metastatic Dermatofibrosarcoma Protuberans (DFSP). *Clin Cancer Res*. 2016;22(4):837-46. <http://dx.doi.org/10.1158/1078-0432.CCR-15-1243>. PMID:26261104.
  17. Hoesly PM, Lowe GC, Lohse CM, Brewer JD, Lehman JS. Prognostic impact of fibrosarcomatous transformation in dermatofibrosarcoma protuberans: a cohort study. *J Am Acad Dermatol*. 2015;72(3):419-25. <http://dx.doi.org/10.1016/j.jaad.2014.11.020>. PMID:25582537.
  18. Rutgers EJ, Kroon BB, Albus-Lutter CE, Gortzak E. Dermatofibrosarcoma protuberans: treatment and prognosis. *Eur J Surg Oncol*. 1992;18(3):241-8. PMID:1607035.

**Author contributions:** Lee SW provided the main research, data gathering, and writing of article, Zaesim A and Jackson A helped format and write sections of the article such as discussion, Borkat M led the clinical management of the patient.

All procedures were in accordance with the ethical standards of the responsible committee on human experimentation (institutional and national) and with the Helsinki Declaration of 1975, as revised in 2008.

**Conflict of interest:** None

**Financial support:** None

**Submitted on:** June 26<sup>th</sup>, 2018

**Accepted on:** July 19<sup>th</sup>, 2018

**Correspondence**

Sang Wook Lee

Mercer University School of Medicine

1550 College St, 31207 – Macon/GA – United States of America

Phone: (404) 936-5300

swlee91@gmail.com