

## Histological remission of autoimmune hepatitis after the addition of allopurinol and azathioprine dose reduction

Ana Luiza Vilar Guedes<sup>a</sup>, Adriana Ribas Andrade<sup>a</sup>, Vinicius Santos Nunes<sup>a</sup>, Fabiana Roberto Lima<sup>b</sup>, Evandro Sobroza de Mello<sup>b</sup>, Suzane Kioko Ono<sup>a</sup>, Débora Raquel Benedita Terrabuio<sup>a</sup>, Eduardo Luiz Rachid Cançado<sup>a,c</sup>

**How to cite:** Guedes ALV, Andrade AR, Nunes VS, et al. Histological remission of autoimmune hepatitis after the addition of allopurinol and azathioprine dose reduction. *Autops Case Rep* [Internet]. 2017;7(2):35-42. <http://dx.doi.org/10.4322/acr.2017.021>

### ABSTRACT

The standard therapy for some autoimmune diseases consists of a combination of corticosteroids and thiopurines. In non-responders to thiopurine drugs, the measurement of the metabolites of azathioprine, 6-thioguanine, and 6-methylmercaptopurine, can be a useful tool. The measurement has been used during the treatment of inflammatory bowel diseases and, less commonly, in autoimmune hepatitis. Many patients preferentially metabolize thiopurines to 6-methylmercaptopurine (6-MMP), which is potentially hepatotoxic, instead of 6-thioguanine, the active immunosuppressive metabolite. The addition of allopurinol shifts the metabolism of thiopurine towards 6-thioguanine, improving the immunosuppressive effect. We present the case of a 51-year-old female with autoimmune hepatitis who had a biochemical response after azathioprine and prednisone treatment without histological remission, and who preferentially shunted to 6-MMP. After the addition of allopurinol, the patient's 6-thioguanine levels increased, and she reached histological remission with a reduction of 67% of the original dose of azathioprine. The patient did not develop clinical manifestations as a consequence of her increased immunosuppressive state. We also review the relevant literature related to this issue. In conclusion, the addition of allopurinol to thiopurine seems to be an option for those patients who do not reach histological remission and who have a skewed thiopurine metabolite profile.

### Keywords

Hepatitis, Autoimmune; Azathioprine; Allopurinol; Azathioprine Metabolism

### INTRODUCTION

The current therapy of autoimmune hepatitis (AIH) consists of corticosteroids (prednisone [PD]/prednisolone) as monotherapy or, more commonly, in combination with azathioprine (AZA), and both have similar response rates. In the combined therapeutic regimen, the starting dose of

PD is usually 30 mg/day together with 50 mg/day AZA. This regimen has fewer side effects when compared with PD alone (10% vs. 44%).<sup>1</sup> During the treatment, the dose of corticosteroid is continuously tapered, whereas the dose of AZA is increased, with the final doses varying from 5 mg to 15 mg, and

<sup>a</sup> University of São Paulo, School of Medicine, Department of Gastroenterology. São Paulo, SP, Brazil.

<sup>b</sup> University of São Paulo, School of Medicine, Department of Pathology. São Paulo, SP, Brazil.

<sup>c</sup> University of São Paulo, Institute of Tropical Medicine of São Paulo. São Paulo, SP, Brazil.



50 mg to 150 mg (1-2 mg/kg/day), respectively.<sup>2,3</sup> Despite the therapy, 9% of patients show clinical deterioration, and even with adequate adherence, 13% exhibit only a partial response, while in approximately 10–20% of cases, AZA is poorly tolerated because of its side effects.<sup>2</sup>

AZA is metabolized through three metabolic enzymatic pathways: (i) xanthine oxidase, which releases an inactive metabolite, thiouric acid; (ii) hypoxanthine phosphoribosyl transferase, which produces 6-thioguanine (6-TGN), which is responsible for the immunosuppressive effect and for myelotoxicity; and (iii) thiopurine methyltransferase (TPMT), which releases 6-methylmercaptopurine (6-MMP), which may account for hepatotoxicity if the levels are higher than 5,700 pmol/8 × 10<sup>8</sup> red blood cells (RBC).<sup>4-7</sup> The levels of 6-TGN between 235 and 450 pmol/8 × 10<sup>8</sup> RBC are considered suitable for immunosuppression without presenting marked myelotoxicity.<sup>8</sup> The variation of the enzyme activity of TPMT in the population can be a factor responsible for AZA toxicity. While 89% of Caucasians have normal or high TPMT activity, 6-11% have intermediate activity, and 0.3% have insignificant activity, with higher risks of myelotoxicity secondary to the metabolic deviation towards the hypoxanthine phosphoribosyl transferase pathway.<sup>9</sup> Conversely, for those patients who preferentially metabolize thiopurine to 6-MMP instead of 6-TGN, AZA can induce hepatotoxicity, usually when the levels are higher than 5,700 pmol/8 × 10<sup>8</sup> RBC.<sup>10</sup> In this situation, the addition of allopurinol shifts the metabolism of thiopurine towards 6-TGN, improving the immunosuppressive effect of AZA and allowing a reduction in its dose. In the medical literature, there are few reported cases in which this approach was performed in AIH.

This is the report of a 51-year-old female with AIH, with only a biochemical response with PD and AZA, who had never achieved histological remission. After initiating allopurinol, the 6-TGN levels increased, the 6-MMP reduced, and the patient reached histological remission with the same dose of PD and one-third of the AZA dose before allopurinol was used. Relevant publications with a similar approach in AIH are discussed, but it is important to note that this is the first case reported in AIH with histological remission proven by liver biopsy.

## CASE REPORT

A 51-year-old female patient sought medical care complaining of pruritus and progressive jaundice over the last 5 months. Her medical history included hypertension, dyslipidemia, and type 2 diabetes mellitus. She had been regularly taking glibenclamide, acetyl salicylic acid, omeprazole, and losartan. She denied the consumption of alcohol, tobacco, or illicit drugs. The physical examination depicted jaundice and mild edema in the lower extremities. Initial laboratory tests showed total bilirubin 16.1 mg/dL (reference range [RR]: <1.2 mg/dL), direct bilirubin 12.4 mg/dL (RR: <0.35 mg/dL); international normalized ratio (INR) 1.6; aspartate aminotransferase (AST) 1,379 U/L (RR: <31 U/L); alanine aminotransferase (ALT) 712 (RR: <31 U/L); alkaline phosphatase (ALP) 165 U/L (RR: <104 U/L); gamma glutamyl transferase (GGT), 154 U/L (RR: <36 U/L); albumin, 1.8 g/dL (RR: 3.2-5.4 g/dL); creatinine, 0.7 mg/dL (RR: 0.6-1.2 mg/dL); hemoglobin (Hb) 11.3 g/dL (RR: 12-16 g/dL); platelets 143,000/m<sup>3</sup> (RR: 140,000-450,000 cells/mm<sup>3</sup>). The serological screening for hepatitis A, B, and C viruses was negative. She had normal levels of alpha-1-antitrypsin, ceruloplasmin, total serum copper, ferritin, and transferrin saturation index. She had hypergammaglobulinemia, 4.47 g/dL (RR: 0.7-1.5 g/dL); elevated immunoglobulin G, 5,361 mg/dL (RR: 952-1,538 mg/dL); ≥1/320 reactivity for both antinuclear antibodies with a homogeneous pattern, and for anti-smooth muscle antibodies with a tubular pattern (reactivity in vessel walls, glomeruli, and fibrils of tubular cells); and reactivity for anti-soluble liver antigen/liver pancreas antibodies (anti-SLA/LP) using ELISA. The abdominal computed tomography imaging revealed signals of chronic liver disease; the upper digestive endoscopy examination did not show esophageal varices; and the liver biopsy revealed portal expansion by fibrosis with porto-portal septa, mononuclear infiltrate with plasma cell predominance, and severe interface activity, with a METAVIR score of F2A3.

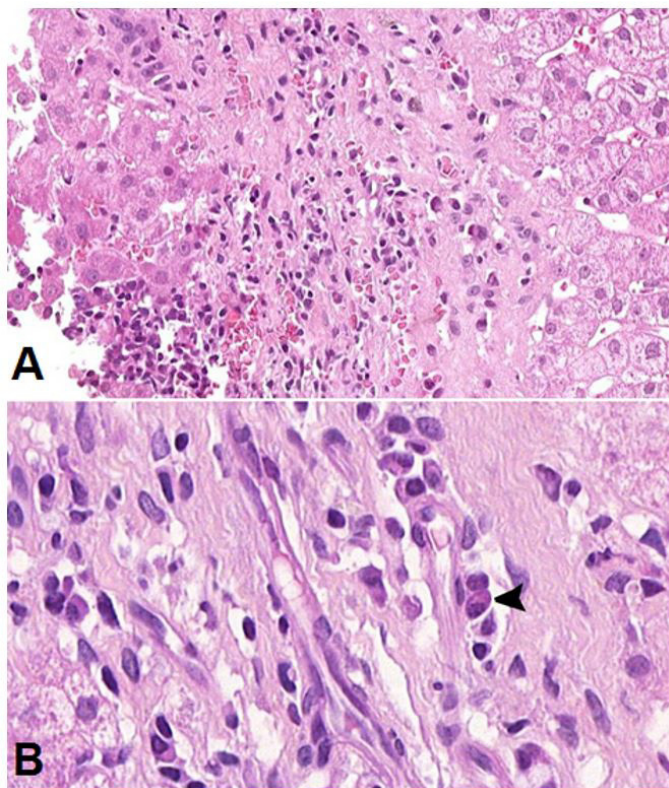
The diagnosis was definite AIH using both score systems of the International Autoimmune Hepatitis Group (IAIHG),<sup>11,12</sup> and the combined therapy with PD 30 mg/day with AZA 50 mg/day was started. The AZA dosage was increased until 125 mg/day (1.8 mg/kg/day) was reached and PD was tapered off until 10 mg/day was reached. After 1 year, ursodeoxycholic acid 900 mg/day was introduced because of the abnormal

levels of GGT and ALP, which reached nine and two times the normal values, respectively. In the third year of follow-up, the patient was asymptomatic and finally achieved biochemical remission, with the normalization of aminotransferase levels. After 18 months of normalized hepatic enzymes, she underwent another liver biopsy to evaluate histological remission. However, the histological report showed moderate fibrosis and discrete periportal activity with an inflammatory infiltrate still rich in plasma cells, with a METAVIR score of F2A2, and an absence of histological remission (Figure 1).

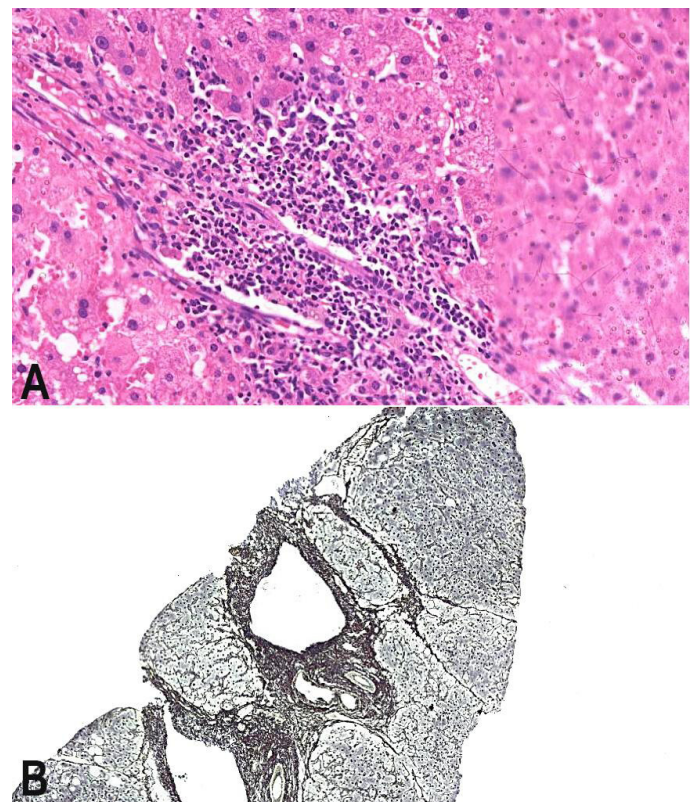
The dosages of AZA and PD were raised to 150 mg/day (2.1 mg/kg/day) and 12.5 mg/day, respectively, and after 18 months another liver biopsy was performed. The histological examination revealed periportal activity, without plasma cells, and progression of fibrosis to F3 (Figure 2).

At this time, the measurement of AZA metabolites revealed 6-MMP levels of 11,606 pmol/8 x 10<sup>8</sup> RBC, which were higher than the threshold for hepatotoxicity;

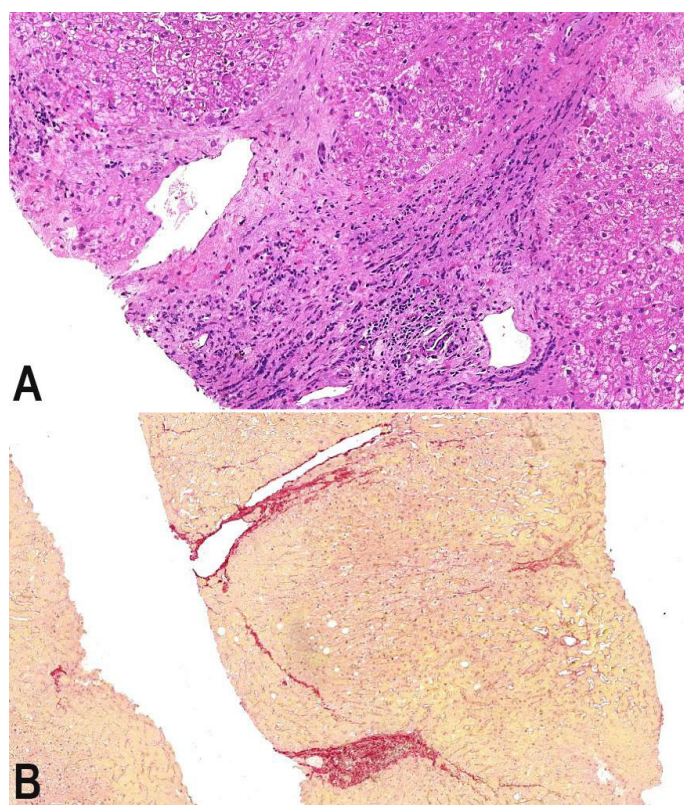
and 6-TGN of 378 pmol/8 x 10<sup>8</sup> RBC. Since the levels of 6-MMP were very high, AZA was reduced to 75 mg/day, PD was maintained at 12.5 mg/day, and allopurinol 100 mg/day was added to the therapeutic regimen. Four months later, the levels of 6-MMP were 9,655 pmol/8 x 10<sup>8</sup> RBC and those of 6-TGN were 1,498 pmol/8 x 10<sup>8</sup> RBC. The AZA dosage was reduced to 50 mg/day because the 6-TGN levels were very high, with a risk for myelotoxicity. The patient had no allopurinol adverse effects, and no manifestations of hyper immunosuppression. After 4 years under this new therapeutic regimen, another liver biopsy was performed, with fibrosis stage F3, and minimal periportal activity (only spill-over of lymphocytes beyond the interface of portal tracts to the liver parenchyma), in a healing pattern, with a METAVIR score of F3A1 and an Ishak's histological activity index (HAI) of 3, which was compatible with histological remission (Figure 3). The patient provided written



**Figure 1.** Photomicrography of the liver biopsy performed after 18 months of normal levels of aminotransferases. **A** - Persistence of periportal activity with a mononuclear inflammatory infiltrate (H&E, 200X); **B** - Presence of plasma cells (arrowhead) (H&E, 700X).



**Figure 2.** Photomicrography of the liver biopsy undertaken when the patient was under the maximum dose of azathioprine (2.1 mg/kg/day). Note the lack of histological remission. **A** - Periportal activity with inflammatory infiltrate (H&E, 200X); **B** - Liver fibrosis with multiple septa-METAVIR fibrosis stage F3 (Reticulin, 50X).



**Figure 3.** Photomicrography of the liver biopsy after the reduction of the azathioprine dose, and the addition of allopurinol to the prescription. **A** - Mild periportal activity, with only a spill-over of lymphocytes beyond the interface of the portal tract to the liver parenchyma (H&E, 100X); **B** - METAVIR fibrosis stage F3 in regression, with perforated septa (Sirius red stain, 50X).

informed consent to the use of allopurinol and to have this information published.

## DISCUSSION

This patient had a definite diagnosis of AIH according to both the classical and the simplified criteria of IAIHG, with a final score of 20 and 7 before treatment, respectively.<sup>11,12</sup> The first goal in the treatment of AIH is to reach the complete biochemical response, which means the normalization of aminotransferase levels, regardless of the period of time that it takes for the patient to achieve this result. The next step is to reach a complete histological remission, which has a less precise definition. The British Society of Gastroenterology Guidelines suggest that histological resolution correlates with long-term survival, with an optimal outcome associated with Ishak's HAI of

3 or less.<sup>13</sup> In our hospital, we follow the instructions of the IAIHG, which considers histological remission to be when periportal activity is minimal or absent (only a spill-over of chronic inflammatory cells beyond the limits of the portal tracts or septa to the liver parenchyma).<sup>11,14</sup> For this reason, the liver biopsy is the only reliable criterion that allows the definition of a complete response to treatment of AIH. However, we can state that, despite a persistent biochemical remission, the full therapeutic response with histological remission was not obtained.

In this case, although the biochemical response was achieved with the combined therapy of PD 10 mg, AZA 125 mg, and ursodeoxycholic acid 900 mg, the histological remission was not achieved even with the maximum dosage of AZA (150 mg; 2.1 mg/kg/day) plus prednisone 12.5 mg/day and ursodeoxycholic acid 900 mg/day. In this situation, there were other possibilities to follow, such as increasing the dose of prednisone. This option was immediately rejected because of the patient's comorbidities, namely: arterial hypertension, dyslipidemia, and type 2 diabetes mellitus. Another possibility was adding another immunosuppressant to the treatment regimen, such as a calcineurin inhibitor like cyclosporine or tacrolimus, but this option was not adopted because the patient was already under treatment for arterial hypertension and type 2 diabetes mellitus. The same schedule could have been maintained, but this would have precluded the possibility of reaching the histological remission and any possible subsequent attempt towards treatment withdrawal.

Although some authors have demonstrated a weak or no relationship between thiopurine metabolite levels and therapeutic efficacy or toxicity in patients with inflammatory bowel diseases,<sup>8</sup> the current concept is that patients in remission probably have higher 6-TGN levels; that is, above 230-260 pmol/ $8 \times 10^8$  RBC. The levels of 6-TGN, surprisingly, showed that the patient was not as immunosuppressed as could be imagined, even though AZA was being used at a dosage of 2.1 mg/kg/day. In addition, the measurement of the levels of metabolites showed that the patient had a good adherence to the treatment. However, the possibility of increasing the dose of AZA was promptly rejected because the levels of 6-MMP were in the range of hepatotoxicity.

The first study about thiopurine metabolites in AIH was performed in pediatric patients in 2002. In this population, the measurement of metabolites was useful in identifying toxicity, but not adherence to therapy.<sup>15</sup> Moreover, the correlation between metabolite levels and therapeutic response in AIH is not well established, with a great variation in metabolite levels and biochemical response. In a 2010 study,<sup>16</sup> among the patients who achieved remission, 74% had 6-TGN above the therapeutic levels. In that study, the histological remission was not evaluated. Another study published in 2012 by Dhaliwal et al.,<sup>17</sup> showed a positive correlation between high levels of 6-MMP and cholestasis, and a negative correlation between 6-TGN levels and ALT. In that study, the therapeutic levels of 6-TGN to achieve biochemical remission were above  $220 \text{ pmol}/8 \times 10^8 \text{ RBC}$ . The biochemical relapse occurred more frequently in patients with 6-TGN levels below  $177 \text{ pmol}/8 \times 10^8 \text{ RBC}$ .

Taking into account the adverse effects of the AZA metabolites, another therapeutic possibility could be replacing AZA with mycophenolate, which has a different mechanism of action. Although the latter interferes with the metabolism of thiopurines by inhibiting the enzyme inositol monophosphate dehydrogenase, this mechanism is quite different from AZA and 6-mercaptopurine.<sup>18</sup> However, the administration of alternative drugs is not fully available as a therapeutic option for AIH in the Brazilian Public Health Service. The administration of allopurinol in this situation seemed suitable because it would be possible to increase the levels of immunosuppressive metabolites and to reduce those related to hepatotoxicity.

The reason why the levels of 6-TGN increase and those of 6-MMP decrease is not completely understood. The initial hypothesis was that allopurinol inhibits TPMT, which was not evidenced *in vitro*. The most convincing explanation is, that after the introduction of azathioprine, there is an induction in up to 92% of TPMT synthesis, and with the addition of allopurinol and the reduction of azathioprine, a move towards 6-TGN occurs due to inhibition of xanthine oxidase, with a concomitant reduction in TPMT activity.<sup>19</sup> Another possibility is that TPMT may be inhibited by metabolites of oxypurinol (the inhibitor of xanthine oxidase), such as 6-thioinosine monophosphate, an analogue of the TPMT substrate.<sup>20,21</sup>

The first clinical experiment involving the addition of allopurinol to the AZA regimen was in renal transplant patients.<sup>22</sup> Following this study, this association was tested in patients with inflammatory bowel diseases who were non-responders to AZA or to 6-mercaptopurine. In these patients, the dose of AZA was reduced to 25–50% of the original dose, and allopurinol 100 mg/day was introduced, which led to a significant increase in 6-TGN and a reduction of 6-MMP levels, with subjective clinical improvement that allowed the interruption of corticosteroid in some patients.<sup>23</sup>

The first experience with allopurinol in patients with AIH was in three case reports that overlapped with primary sclerosing cholangitis who exhibited elevation of aminotransferases due to toxicity by 6-MMP, which was reversed after the addition of allopurinol and a reduction in the dose of thiopurine, resulting in biochemical remission.<sup>24</sup> More recently, de Boer et al.<sup>25</sup> published a study with eight patients classified as non-responders or as intolerant to therapy who had unfavorable thiopurine metabolism. They added allopurinol 100 mg/day to 25–33% of the initial thiopurine dose, reaching a biochemical improvement and showing the possibility of a reduction in the corticosteroid dose, and the collateral effects of thiopurine. The mean levels of 6-TGN increased from 100 to  $200 \text{ pmol}/8 \times 10^8 \text{ RBC}$  and the mean levels of 6-MMP reduced from 6,090 to  $175 \text{ pmol}/8 \times 10^8 \text{ RBC}$ .<sup>25</sup> In this study, histological remission was not assessed, and the hematological effects of thiopurine drugs were not significant. There are other isolated case reports on the addition of allopurinol in AIH patients, but the histological remission was not evaluated.<sup>5</sup> In the present case, there was a marked elevation in 6-TGN levels and a less impressive reduction of 6-MMP, but the patient had no clinical signs of excessive immunosuppression, myelosuppression, or hepatotoxicity.

Patients with refractory AIH evolve with the maintenance of liver inflammation, progressing to cirrhosis and portal hypertension. Increasing the dose of corticosteroids or AZA may not always be the best strategy for these patients because of their inherent side effects. The addition of another immunosuppressive also may be deleterious because other side effects are implicit with them. In these situations, the detection of an unfavorable profile of thiopurine metabolites can be an opportunity to add

allopurinol with a lower dose of the thiopurine drug, which shifts the thiopurine metabolism towards 6-TGN, thus improving the immunosuppression and decreasing the 6-MMP levels, with lower hepatotoxicity. Our case is different from those that have been published, because the patient did not present the side effects of the thiopurine and could not be classified as having refractory AIH. The problem was that the patient did not achieve histological remission with the conventional therapeutic regimen—even when using the maximum dose of AZA and an appropriate dose of corticosteroids. The addition of allopurinol to the therapeutic regimen led to a histological remission with a small dose of AZA, which has not yet been described in the literature. The possibility of using this low dose is interesting because of the reduction in the risk of hepatotoxicity, and the likely reduction in the cost of treatment.

## REFERENCES

1. Soloway RD, Summerskill WH, Baggenstoss AH, et al. Clinical, biochemical, and histological remission of severe chronic active liver disease: a controlled study of treatments and early prognosis. *Gastroenterology*. 1972;63(5):820-33. PMID:4538724.
2. Czaja AJ, Freese DK. Diagnosis and management of autoimmune hepatitis. *Hepatology*. 2002;36(2):479-97. PMID:12143059. <http://dx.doi.org/10.1053/jhep.2002.34944>.
3. MacFarlane IG. The relationship between autoimmune markers and different clinical syndromes in autoimmune hepatitis. *Gut*. 1998;42(5):509-602. PMID:9659147.
4. Yeoman AD, Longhi MS, Heneghan MA. Review article: the modern management of autoimmune hepatitis. *Aliment Pharmacol Ther*. 2010;31(8):771-87. PMID:20096018.
5. Al-Shamma S, Eross B, Mclaughlin S. Use of xanthine oxidase inhibitor in autoimmune hepatitis. *Hepatology*. 2013;57(3):1281-2. PMID:23238820. <http://dx.doi.org/10.1002/hep.26198>.
6. Wolf A, Burnat P, Garcia-Hejl C, Ceppa F. Étude pharmacologique et pharmacogénétique de deux immunomodulateurs: l'azathioprine et la 6-mercaptopurine. Stratégies de prévention des complications. *Gastroenterol Clin Biol*. 2009;33(3):176-84. PMID:19243907. <http://dx.doi.org/10.1016/j.gcb.2008.10.014>.
7. Czaja AJ, Carpenter HA. Thiopurine methyltransferase deficiency and azathioprine intolerance in autoimmune hepatitis. *Dig Dis Sci*. 2006;51(5):968-75. PMID:16773433. <http://dx.doi.org/10.1007/s10620-006-9336-5>.
8. Osterman MT, Kundu R, Lichtenstein GR, Lewis JD. Association of 6-thioguanine nucleotide levels and inflammatory bowel disease activity: a meta-analysis. *Gastroenterology*. 2006;130(4):1047-53. PMID:16618398. <http://dx.doi.org/10.1053/j.gastro.2006.01.046>.
9. Neto MP, Alves ANL, Fortini AS, et al. Monitoração terapêutica da azatioprina: uma revisão. *J Bras Patol Med Lab*. 2008;44(3):161-7.
10. Dubinsky MC, Lamothe S, Yang HY, et al. Pharmacogenomics and metabolite measurement for 6-mercaptopurine therapy in inflammatory bowel disease. *Gastroenterology*. 2000;118(4):705-13. PMID:10734022. [http://dx.doi.org/10.1016/S0016-5085\(00\)70140-5](http://dx.doi.org/10.1016/S0016-5085(00)70140-5).
11. Alvarez F, Berg PA, Bianchi FB, et al. International Autoimmune Hepatitis Group Report: review of criteria for diagnosis of autoimmune hepatitis. *J Hepatol*. 1999;31(5):929-38. PMID:10580593. [http://dx.doi.org/10.1016/S0168-8278\(99\)80297-9](http://dx.doi.org/10.1016/S0168-8278(99)80297-9).
12. Hennes EM, Zeniya M, Czaja AJ, et al. Simplified criteria for the diagnosis of autoimmune hepatitis. *Hepatology*. 2008;48(1):169-76. PMID:18537184. <http://dx.doi.org/10.1002/hep.22322>.
13. Gleeson D, Heneghan MA. British Society of Gastroenterology (BSG) guidelines for management of autoimmune hepatitis. *Gut*. 2011;60(12):1611-29. PMID:21757447. <http://dx.doi.org/10.1136/gut.2010.235259>.
14. Gayotto LCC, Alves VA, Cerski CT. Visão Histórica e consenso nacional sobre a classificação das hepatites crônicas. *GED*. 2000;19:137-40.
15. Rumbo C, Emerick KM, Emre S, Shneider BL. Azathioprine metabolite measurements in the treatment of autoimmune hepatitis in pediatric patients: a preliminary report. *J Pediatr Gastroenterol Nutr*. 2002;35(3):391-8. PMID:12352536. <http://dx.doi.org/10.1097/00005176-200209000-00032>.
16. Nguyen TM, Daubard M, Le Gall C, Larger M, Lachaux A, Bouliou R. Monitoring of azathioprine metabolites in pediatric patients with autoimmune hepatitis. *Ther Drug Monit*. 2010;32(4):433-7. PMID:20479703. <http://dx.doi.org/10.1097/FTD.0b013e3181dbd712>.
17. Dhaliwal HA, Anderson R, Thornhill EL, et al. Clinical significance of azathioprine metabolites for the maintenance of remission in autoimmune hepatitis. *Hepatology*. 2012;56(4):1401-8. PMID:22488741. <http://dx.doi.org/10.1002/hep.25760>.
18. Jonsson CA, Carlsten H. Inosine monophosphate dehydrogenase (IMPDH) inhibition in vitro suppresses lymphocyte proliferation and the production of immunoglobulins, autoantibodies and cytokines in

- splenocytes from MRLlpr/lpr mice. *Clin Exp Immunol*. 2001;124(3):486-91. PMID:11472413. <http://dx.doi.org/10.1046/j.1365-2249.2001.01545.x>.
19. Weyer N, Kroplin T, Fricke L, Iven H. Human thiopurine S methyltransferase activity in uremia and after renal transplantation. *Eur J Clin Pharmacol*. 2001;57(2):129-36. PMID:11417444. <http://dx.doi.org/10.1007/s002280100287>.
  20. Roberts RL, Geary RB, Barclay ML. Allopurinol-thiopurine combination therapy in inflammatory bowel disease: are there genetic clues to this puzzle? *Pharmacogenomics*. 2010;11(11):1505-8. PMID:21121769. <http://dx.doi.org/10.2217/pgs.10.143>.
  21. Duley JA, Chocair PR, Florin TH. Observations on the use of allopurinol in combination with azathioprine or mercaptopurine. *Aliment Pharmacol Ther*. 2005;22(11-12):1161-2. PMID:16305731. <http://dx.doi.org/10.1111/j.1365-2036.2005.02703.x>.
  22. Chocair P, Ianhez L, Arap S, et al. Low-dose allopurinol plus azathioprine/cyclosporin/prednisolone, a novel immunosuppressive regimen. *Lancet*. 1993;342(8863):83-4. PMID:8100914. [http://dx.doi.org/10.1016/0140-6736\(93\)91287-V](http://dx.doi.org/10.1016/0140-6736(93)91287-V).
  23. Sparrow MP, Hande SA, Friedman S, et al. Allopurinol safely and effectively optimizes tioguanine metabolites in inflammatory bowel disease patients not responding to azathioprine and mercaptopurine. *Aliment Pharmacol Ther*. 2005;22(5):441-6. PMID:16128682. <http://dx.doi.org/10.1111/j.1365-2036.2005.02583.x>.
  24. Dunkin D, Kerkar N, Arnon R, Suchy F, Miloh T. Allopurinol salvage therapy in pediatric overlap autoimmune hepatitis-primary sclerosing cholangitis with 6-MMP toxicity. *J Pediatr Gastroenterol Nutr*. 2010;51(4):524-6. PMID:20531025. <http://dx.doi.org/10.1097/MPG.0b013e3181d29750>.
  25. de Boer YS, Van Gerven NMF, Boer NKH, et al. Allopurinol safely and effectively optimizes thiopurine metabolites in patients with autoimmune hepatitis. *Aliment Pharmacol Ther*. 2013;37(6):640-6. PMID:23347359. <http://dx.doi.org/10.1111/apt.12223>.

**Informed consent statement:** Written informed consent was obtained from the patient for publication of this case report.

**Author contributions:** The manuscript was produced, reviewed and approved by all of the authors collectively. Guedes ALV wrote the manuscript and was in charge of the online submission. Andrade AR and Nunes VS retrieved the clinical data from the patient's chart. Mello ES and Lima FR interpreted the histological data and provided the images. Kioko Ono S coordinated the project for measuring the azathioprine metabolites. Terrabuio DRB was in charge of the follow-up of the patient in the outpatient clinic. Caçado ELR was the coordinator of the project. He was responsible for the introduction of allopurinol in patients with autoimmune hepatitis with a skewed metabolism profile of azathioprine.

**Conflict of interest:** None

**Financial support:** Eduardo Luiz Rachid Caçado had a scholarship from the Federico Foundation, Switzerland.

**Submitted on:** March 17<sup>th</sup>, 2017

**Accepted on:** June 2<sup>nd</sup>, 2017

### Correspondence

Eduardo Luiz Rachid Caçado

Department of Gastroenterology - School of Medicine - University of São Paulo (USP)

Avenida Doutor Enéas de Carvalho Aguiar, 255, 9<sup>th</sup> floor, room 9159 – São Paulo/SP – Brazil

CEP: 05403-000

Phone: +55 (11) 2661-6447 / Fax: +55 (11) 2661-7830

edulrc@uol.com.br

## **ABBREVIATIONS**

6-MMP = 6-methylmercaptopurine

6-TGN = 6-thioguanine

AIH = autoimmune hepatitis

ALP = alkaline phosphatase

ALT = alanine aminotransferase

ANA = antinuclear antibodies

anti-SLA/LP = anti-soluble liver antigen/liver pancreas antibodies

ASMA = anti-smooth muscle antibodies

AST = aspartate aminotransferase

AZA = azathioprine

GGT = gamma glutamyl transferase

HAI = Ishak's histological activity index.

Hb = hemoglobin

IAIHG = International Autoimmune Hepatitis Group

INR = international normalized ratio

PD = prednisone

RBC = red blood cells

TPMT = thiopurine methyltransferase